



# Outcome of Laparoscopic Totally Extraperitoneal Approach with Direct Dissection and Mesh Hernioplasty in the Treatment of Inguinal Hernia

**Osama Hasan Abd-Raboh, Taha Ahmed Ismael, Hamdy Abdel-Hady Mohamed**

General Surgery Department, Tanta University Hospitals, Tanta, Egypt

**Email address:**

dr\_osama\_hassan@med.tanta.edu.eg (O. H. Abd-Raboh), tahaemail@yahoo.com (T. A. Ismael)

**To cite this article:**

Osama Hasan Abd-Raboh, Taha Ahmed Ismael, Hamdy Abdel-Hady Mohamed. Outcome of Laparoscopic Totally Extraperitoneal Approach with Direct Dissection and Mesh Hernioplasty in the Treatment of Inguinal Hernia. *Journal of Surgery*. Special Issue: Minimally Invasive and Minimally Access Surgery. Vol. 5, No. 3-1, 2017, pp. 1-7. doi: 10.11648/j.js.s.2017050301.11

**Received:** December 25, 2016; **Accepted:** December 26, 2016; **Published:** February 6, 2017

---

**Abstract:** Aim of the work: To evaluate total extraperitoneal repair with direct telescopic dissection and mesh hernioplasty for inguinal hernias. Patients and methods: This study was conducted at Gastrointestinal, Liver & Laparoscopic Surgery Unit, General Surgery Department, Tanta University Hospital, over the period from 1st Jan 2014 to last of June 2015 on 20 patients having inguinal hernia. Results: This prospective study included 20 adult patients with primary unilateral inguinal hernia, all of them were males. Age of study patients ranged from 22 to 64 years old. There were 11 patients with right inguinal hernia (55%) and 9 patients with left inguinal hernia (45%). Mean operative time was  $99.30 \pm 25.13$  min. (with range between 60 - 160 min). The mean time for analgesia was  $3.75 \pm 1.62$  days (ranged 2 - 7 days). 24 hours post-operatively, mean visual pain score was  $2.8 \pm 1.15$ . There was one case of scrotal edema (5%). Minor surgical emphysema occurred in two cases (10%). Hospital stay ranged from 1-3 days, and the mean was  $1.35 \pm 0.67$  days. The mean time until return to work was  $14.8 \pm 4.26$  days, ranged from 7 - 21 days. The mean time of follow up was  $7.6 \pm 2.1$  months (range 6-12 months). There were no reported cases of hernia recurrences. Conclusion: Laparoscopic TEP repair is an excellent alternative to open preperitoneal repair of inguinal hernia. Operative time is relatively long but still comparable to many of studies discussing TEP technique and improving over the time of the study indicating the need for long learning curve. This technique was proved safe, as it was not associated with major morbidity or recurrence. Complication rate was average with other studies while there was no hernia recurrence during the period of follow up.

**Keywords:** TEP, Laparoscopic Hernia Repair, Telescopic Dissection

---

## 1. Introduction

Inguinal hernia is the most common type of herniae; More than 70% of all herniae that occur are inguinal type [1]. In 1986 Lichtenstein advocated an open on-lay mesh repair applied over the internal oblique fascia. This shared in the era of tension free repairs using mesh [2]. The laparoscopic approach for inguinal hernia repair was first reported by Ger, who performed a high ligation of the sac without mesh placement [3]. In 1993 the laparoscopic total extraperitoneal (TEP) approach was reported by McKernan [4]. The TEP approach allows for mesh placement within the preperitoneal space, without entering the abdominal cavity and the avoidance of the incision and closure of the peritoneum

typically required in the TAPP approach [5]. The creation of preperitoneal space is an important first step in the TEP hernia repair. The balloon dissection is the most commonly used method to create extraperitoneal space and is said to be helpful during the learning curve [6]. Commercially available balloons are expensive and associated with risk of bleeding, rupture of balloon, rupture of bladder neck and blind dissection without visualizing the important structures [7].

## 2. Patients and Methods

This study was conducted at Gastrointestinal, Liver &

Laparoscopic Surgery Unit, General Surgery Department, Tanta University Hospital, over the period from 1st Jan 2014 to last of June 2015 on 20 patients having inguinal hernia, to evaluate Laparoscopic totally extra-peritoneal approach with direct telescopic dissection and mesh hernioplasty in the treatment of inguinal hernia. This included operative time, hospital stay, post-operative morbidity and recurrence. All patients were adults above 18 years old with unilateral primary inguinal hernia. Exculsion criteria included; recurrent, sliding and complicated hernias, previous lower abdominal incision or preperitoneal operations and patients with severe co-morbidities (ASA class > III). All patients were subjected to full history taking, full clinical and laboratory examination and informed written consent about the benefits, possible risks and recording of the procedure.

### 2.1. Position and Anesthesia

The patient was placed in supine position on the operating table; after general anesthesia, a routine scrubbing with betadine 7.5% of the entire abdominal wall up to nipple line, penis, scrotum and upper half of thigh. The surgeon stands on the side opposite the hernia, the assistant stands beside the surgeon towards the head of the patient, and the monitor is placed at the patient leg at the same side of hernia. After insertion of 1st trocar & telescope, the table was put with a 15° Trendelenburg tilt (Fig. 1).

### 2.2. Technique

Transverse sub-umbilical 1.5cm incision was made slightly to the side of hernia; the anterior rectus sheath was incised transversely between two stay sutures of Vicryl 0. The rectus muscle was retracted laterally, and a small tunnel in the midline was made in the direction of pubis, between the rectus muscle and preperitoneal fat firstly by finger dissection then by insertion of 1st trocar (10mm. trocar). After insertion of 1st trocar between rectus muscle anteriorly and posterior rectus sheath posteriorly we start insufflation of Co2 at pressure 14 mm Hg. Because the posterior rectus sheath ends at the line of Douglas (arcuate line), the telescope (0°, 10mm.) passed on top of the posterior rectus sheath will automatically fall into the extraperitoneal space. Co2 gas insufflation facilitates separation of preperitoneal loose areolar tissue which is mostly avascular. The telescope itself was used for dissection of midline tunnel down to the symphysis pubis. After enough space was done by the telescope, the two 5mm. operating ports were inserted under vision both in the midline, the first 2 fingers breadth superior to the symphysis pubis and the other midway between the other two ports (5cm at least above suprapubic port) {Figure 2}. After insertion of all trocars, (30°, 10mm.) telescope is inserted to facilitate further instrumental dissection of preperitoneal space. Two blunt graspers or one grasper with Maryland grasper were used for further dissection of loose areolar tissue, 1st in the midline till complete visualization of posterior surface of pubic bone and space of Retzius. Identification of inferior epigastric vessels is an important

land mark that appears in the ceiling of the field {Figure 3}. External downward traction on the ipsilateral testis facilitates identification of cord structures coming lateral and below inferior epigastric vessels through the internal ring associated with indirect (oblique) peritoneal sac {Figure 4}. The hernial sac was identified and reduced. Sac was freed from the cord structures by traction and counter traction by the other hand. Parietalization of cord structures by peeling off the peritoneum is done, continuing the dissection cranially from the internal ring till the crossing of vas deferens with external iliac vessels and freeing all bands extending from the peritoneum to the parietal wall {Figure 5}. Direct hernia sac usually dissected easily and reduced with the midline dissection while the fascial defect appears medial to inferior epigastric vessels and cord structures. Blunt dissection of the lateral space between inferior epigastric vessels superiorly and cord structures inferiorly till reaching anterior superior iliac spine laterally and visualization of psoas muscle inferiorly {Figure 6}.

### 2.3. Mesh Insertion

A 12 x 15 cm fashioned polypropylene mesh rolled from lateral to medial and introduced through the 10 mm infra-umbilical port and unfolded from medial to lateral {Figures 7, 8, 9}. The mesh should lie unfolded in the preperitoneal space with the cord structures parietalized. The lower edge must extend well below the level of the inguinal ligament {Figure 9}. The lateral part of the patch should fold over and extend beyond the iliac vessels. Suction drain 14F was used in all cases to prevent hematoma collection and to drain any remaining gas in the scrotum and preperitoneal space to help mesh incorporation in the preperitoneal space. Drain was inserted through lower 5mm suprapubic port. The gas was released under direct vision, ensuring that the inferior border of the mesh will not roll up; mesh was not fixed in all of cases in this study.

### 2.4. Follow Up

Every patient was followed up for at least 6 months postoperatively; follow up was on weekly basis in the 1st month & monthly thereafter for any complications e.g. chronic pain or recurrence.

## 3. Results

This prospective study included 20 adult patients with primary unilateral inguinal hernia, all of them were males. Age of study patients ranged from 22 to 64 years old with the mean age was  $39.60 \pm 11.46$  years. 8 patients were nonsmokers (40%), 7 were mild smokers (35%), and 5 patients were heavy smokers (25%). There were 11 patients with right inguinal hernia (55%) and 9 patients with left inguinal hernia (45%).

Intraoperatively, 4 patients were presented to have direct inguinal hernia (20%) while 14 patients had indirect inguinal hernia (70%). In 2 patients, combined direct & indirect

hernia defects were present (10%). Mean operative time was  $99.30 \pm 25.13$  min. (with range between 60 -160 min) {Table 1}. In four patients (20%), peritoneal tears occurred during dissection of indirect sac with gas leak into peritoneal space. Insertion of Veress needle through subumbilical incision to peritoneal space was efficient as a vent in 3 cases. In the 4th case we used 16F cannula instead of Veress needle. In all the four cases, the operative field was sufficient to complete the operation as regular. All cases of this study were completed as TEP with no conversion to TAPP or open approach.

All patients needed 2 injections of analgesia in the first postoperative day to relieve the pain, and two to three oral doses per day of analgesics till they are pain free. The mean time for analgesia was  $3.75 \pm 1.62$  days ranged (2 - 7 days). After 24 hours post-operatively, mean visual pain score was  $2.8 \pm 1.15$  {Table 2}. In our study, there was one case of scrotal edema (5%). Minor surgical emphysema occurred in two cases (10%) and resolved over the following 2 days postoperative. One case complained from minor superficial infection in the subumbilical port incision after 1 week and resolved after antibiotic therapy with daily dressing. Drain was removed in all patients after 24 hours with amount of 20-50 cc. of serosanguinous discharge. Hospital stay ranged from 1-3 days, and the mean was  $1.35 \pm 0.67$  days (Table 3). The mean time until return to work was  $14.8 \pm 4.26$  days, ranged from 7 – 21 days. The mean time of follow up was  $7.6 \pm 2.1$  months (range 6-12 months). There were no reported cases of hernia recurrences during the period of follow up of our cases.

**Table 1.** Operative Time.

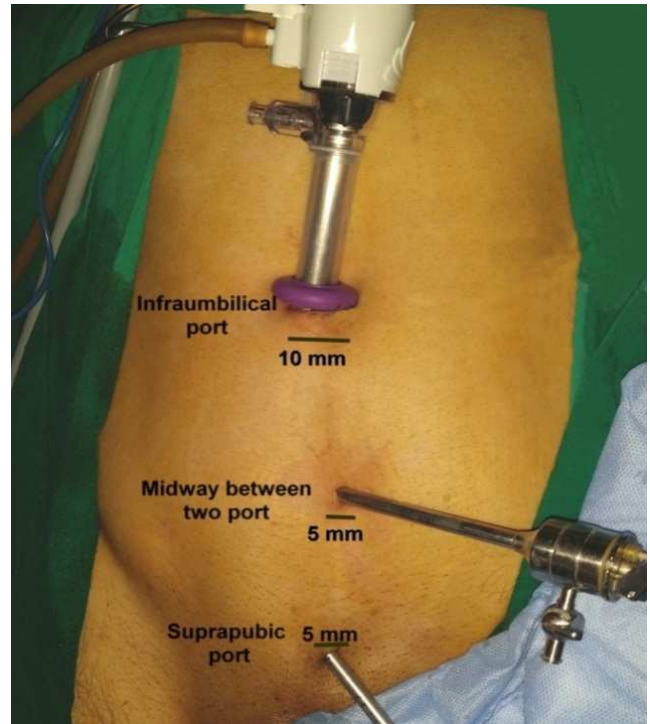
Operative Time	Number of Cases	%
60: 80 min.	4	20%
80: 100 min.	8	40%
100: 120 min.	5	25%
120: 140 min.	1	5%
140: 160 min.	2	10%

**Table 2.** Visual analogue pain scale 24 hours postoperative.

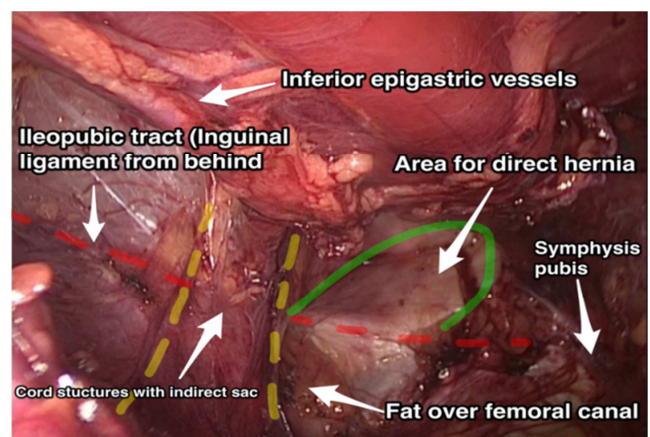
Visual analogue pain scale 24 hours postoperative	Number of Cases	%
2	11	55%
3	5	25%
4	2	10%
5	1	5%
6	1	5%

**Table 3.** Postoperative hospital stay.

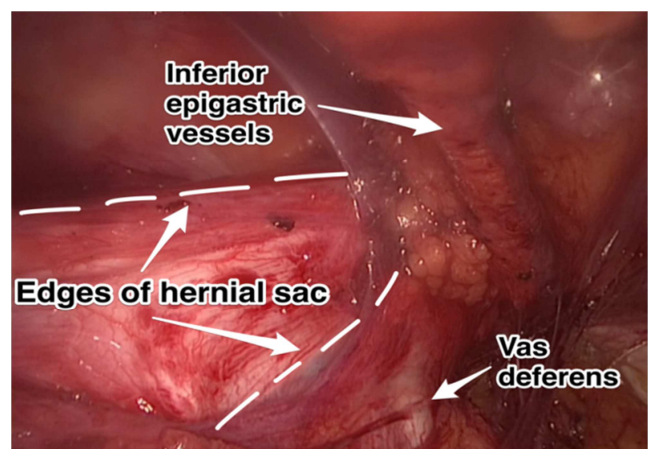
Hospital stay (days)	Number of Cases	%
1	15	75%
2	3	15%
3	2	10%



**Fig. 1.** Trocars positioning.

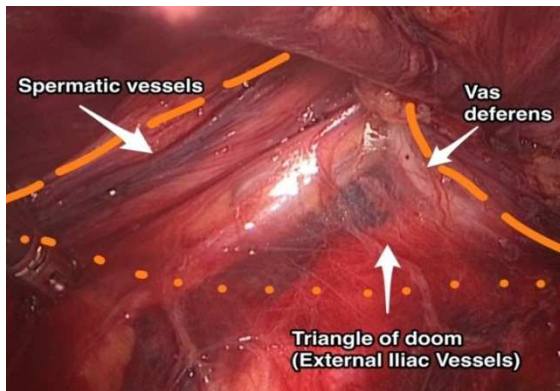


**Fig. 2.** Laparoscopic view of groin area.

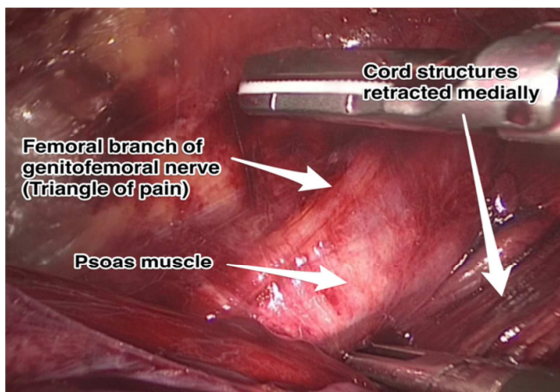


**Fig. 3.** Indirect peritoneal sac.





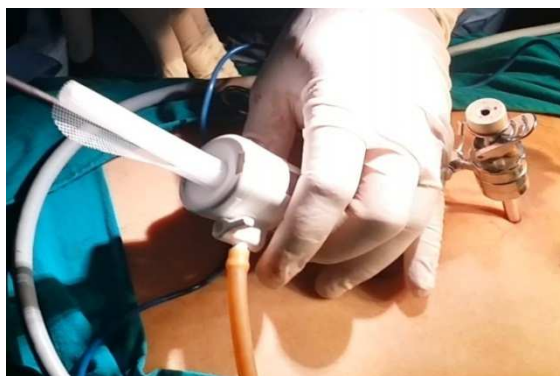*Fig. 4. Triangle of doom.*



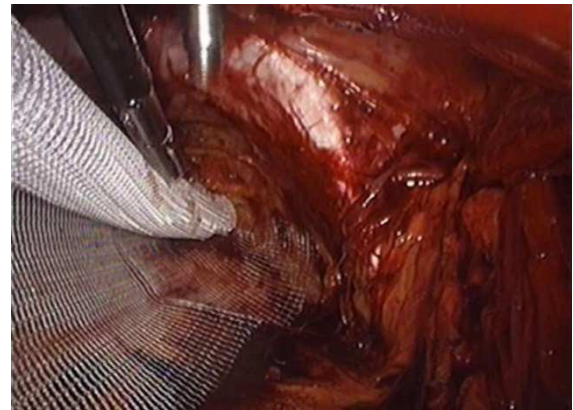
*Fig. 5. Lateral dissection and psoas muscle.*



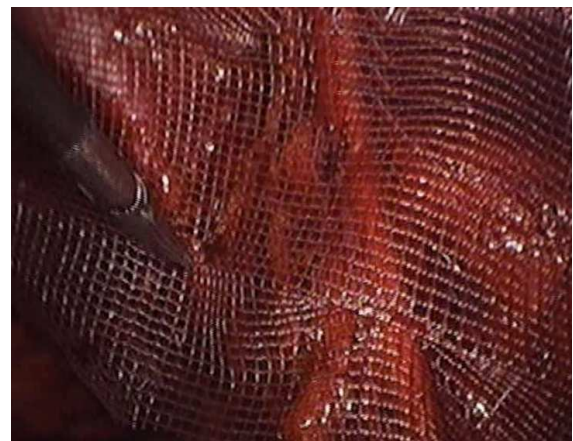*Fig. 6. Fashioned polypropylene mesh.*



*Fig. 7. Mesh insertion via 1<sup>st</sup> trocar.*



*Fig. 8. Unfolding of mesh.*



*Fig. 9. Mesh completely unfolded.*

## 4. Discussion

The tension-free prosthetic inguinal hernia repairs are much more favored nowadays in view of the uniformly reported good results and low recurrence rates [8]. Laparoscopic hernioplasty proved to be an effective minimally invasive operation with low recurrence rate when performed correctly [9]. TEP is more expensive and technically demanding with steep learning curve [10], but, with less postoperative pain, reduced recovery time, easier repair of recurrent and bilateral hernia with highest possible ligation of the sac [11].

Regarding operative time, while some studies showed very short operative time for TEP ( $17 \pm 6$  min.) in 3100 hernia repairs over 15 years [12], this was not the rule. Kuhry et al. [13] found that ten out of fifteen trials reported a TEP repair to be associated with an increased duration of surgery compared to open repair. A study comparing balloon dissection vs. direct telescopic dissection in TEP showed no difference in mean operative time between two groups ( $77.5 \pm 24.1$  vs.  $74.2 \pm 24.4$  min.) [14]. In our study, the operative mean time was  $99.30 \pm 25.13$  min with ranged (60 -160 min) which was longer than many of other studies. This can be attributed to longer learning curve in endoscopic hernia repair than open repair due to the limited working space and different appreciation of the anatomical landmarks [15].

Direct Hernias are easily reduced. At times, a long indirect sac cannot be completely reduced from the deep inguinal ring and is divided, the peritoneal side being ligated with a laparoscopic suture. [16]. In this study, 3 of indirect (oblique) hernias with long sac necessitated proximal ligation of the sac with extracorporeal knotting.

We did not fix the mesh in place in this study. Some investigators advocated not fixing the mesh in place [17]. This idea was bolstered by Stoppa's success with non-fixation of mesh in the open preperitoneal operation [18]. A recently published meta-analysis of six randomised, controlled trials on laparoscopic inguinal hernia repair (LIHR) through the total extraperitoneal approach concluded that the no-mesh fixation (NMF) was not associated with higher recurrence rate but lower cost was an advantage [19].

Peritoneal tears in TEP are the most common reason for conversion and predispose patients to small bowel adhesions. Loss of preperitoneal space may require switching to another technique. Placing a Veress needle into the abdomen to evacuate the intra-abdominal gas in minute perforations or closure by loop ligation, pretied suture, endoscopic stapling and endoscopic suturing is mandatory [20]. In our study, peritoneal tears are dealt with insertion of Veress needle through subumbilical incision to peritoneal space was efficient as a vent in 3 cases. In the 4th case we used 16F cannula instead of Veress needle. In all the four cases, the operative field was sufficient to complete the operation as regular and peritoneal tears were small with no need for ligation or sutures.

In our study, Intensity of pain was recorded 24 hours postoperatively. Mean visual pain score was  $2.8 \pm 1.15$ . This was comparable to other studies recording postoperative pain after 24 hours of TEP; 79.7% of patient take score 2 [21],  $(4.8 \pm 2.33)$  [22], and  $2.9 \pm 1.3$  [14].

There were no cases complaining from chronic groin pain during the period of follow up in this study. The incidence of chronic pain after endoscopic hernia repair varies between 1 and 16% [23]. Postoperative pain (acute or chronic) is a potential complication; injury to the nerves during dissection is a common cause of chronic pain. Such injury can be avoided by gentle dissection in the triangle of pain and not fixing the mesh [24].

There were no reported cases of intraoperative serious visceral or vascular complications in this study. This is matching with the results of other studies [22]. In our study, 25% of patients developed postoperative minor complications in the form of scrotal edema (5%), surgical emphysema (10%) and superficial wound infection (5%). Seroma and scrotal edema are frequent complications after laparoscopic repair of inguinal hernia, with a reported incidence ranging from 1.9% to 11.7 [25]. closed-suction drain can be used to reduce the risk of seroma formation without increased risk of infection [26]. In our study, suction drain 14F was used in all cases to prevent hematoma collection and to drain any remaining gas in the scrotum and preperitoneal space. However, the amounts collected by the drain were small (20-50 c.c.), so, we don't recommend

routine use of drain in these cases. Incidence of subcutaneous emphysema is reported to be in the range 2.2–56% [27] [28]. Superficial infections are rare after endoscopic techniques. The risk is probably about 1–3% for open surgery and less than 1% after endoscopic surgery [29]. There was one case in our study that developed superficial infection (5%) that was treated conservatively. Elective primary abdominal reconstruction with mesh is considered a clean surgery, with infection rates of up to 8% being reported [30]. Another study showed no difference between open and endoscopic approaches in wound infection rate (4.5% vs. 3.3%) [31] [32].

Dulucq JL et al. [12] had studied laparoscopic totally extra-peritoneal inguinal hernia repair retrospectively for 15 years on 3,100 hernia repairs showed that the recurrence rate was 0.46%. The recurrence rate for the first 200 repairs was 2.5%, but it decreased to 0.47% for the subsequent 1,254 hernia repairs. Kuhry et al. [13] showed that most trials ( $n = 14$ ) reported no differences in recurrence rates after either TEP or open repair. In our study, there were no reported cases of hernia recurrence during the period of follow up. In our opinion, these excellent results can be confirmed only by studying large numbers of cases and for longer periods of follow up.

In this study, hospital stay ranged from 1-3 days, and the mean was  $1.35 \pm 0.67$  days. These results coincided with the results of the others as [33] in which the mean hospital stay in laparoscopic TEP group was (1.4) days, (1.48) days [34] and  $(1.5 \pm 0.4)$  days in [12].

In this study the mean time until return to work was  $14.8 \pm 4.26$  days, ranged from 7 – 21 days. Small incision and reduced postoperative pain after laparoscopic TEP are the causes for early ambulation and return to normal activities [36]. Liem et al. [37] proved that patients who underwent laparoscopic repairs regained their physical performance faster than those who underwent conventional hernia repairs.

Laparoscopic TEP repair is an excellent alternative to open preperitoneal repair of inguinal hernia with the ability of using large mesh to cover all inguinal potential defects plus the much better visualization of anatomical landmarks.

Operative time is relatively long but still comparable to many of studies discussing TEP technique and improving over the time of the study indicating the need for long learning curve. TEP proved to be cost effective as we tried in this study to reduce overall cost by using telescopic dissection without balloon and without mesh fixation without any need to convert to other technique in all of our patients. This technique was proved safe, as it was not associated with major morbidity or recurrence. Complication rate was average with other studies while there was no hernia recurrence during the period of follow up.

We recommend TEP technique to be used for uncomplicated inguinal hernia when the experience exists and to undergo other studies on large number of cases with more extended periods of follow up to confirm our given results.

## References

- [1] Zollinger RM (2003): Classification systems for groin hernias. *Surg. Clin. N. Am.* 83; 1053-63.
- [2] Kurzer M, Belsham PA and Kark AE (2003): The Lichtenstein repair for groin hernias. *Surg Clin N Am* 83; 1099-117.
- [3] Ger R, Monroe K, Duvivier R and Mishrick A (1990): Management of indirect inguinal hernias by laparoscopic closure of the neck of the sac. *Am J Surg*; 159:370-3.
- [4] Mckernan JB and Laws HL (1993): laparoscopic repair of inguinal hernia by total extraperitoneal approach. *Surg. Endosc.* 7; 26-8.
- [5] Bruce R (2006): Laparoscopic Total Extraperitoneal Inguinal Hernia Repair. *Operative Techniques in General Surgery* Volume 8, Issue 1, Pages 34-44.
- [6] Froeling FM, Deprest JA, Ankum WM, Mendels EL, Meijer DW and Bannenber J (2000): Controlled balloon dilatation for laparoscopic extraperitoneal bladder neck suspension in patients with previous abdominal surgery. *J Laparoendosc Adv Surg Tech A* 10(1): 27-30.
- [7] Misra C, Kumar S and Bansal V (2008): Total extraperitoneal (TEP) mesh repair of inguinal hernia in the developing world: comparison of low-cost indigenous balloon dissection versus direct telescopic dissection: a prospective randomized controlled study. *Surg Endosc* 22:1947-58.
- [8] Cuschieri A (2002): Disorders of abdominal wall and peritoneal cavity: Hernias in: *Essential surgical practice*. Cuschieri A., Steele R.J.C. and Abdool Rahim Moosa. 4th edition, London, Arnold, section 6. 8: 167-79.
- [9] Reddick EJ, Morton CE, Bradham WG and O'Reilly MJ (1998): Kugel Herniorrhaphy: An Outpatient Option to Laparoscopic Hernia Repair. *Sixth World Congress of Endoscopic Surgery*, Rome, Italy, June 3-6.
- [10] Anniballi R and Fitzgibbon JR (2005): *Operative strategies in Laparoscopic surgery*. Berlin Springer. P. 57-82.
- [11] Fitzgibbons RJ, Filipi CJ and Quinn TH (2005): Inguinal hernia, In: *Swartz's principles of surgery*. edited by Brunicaardi F, Anderson D Dunn D, 8th ed., McGraw-Hill, Vol 4, Ch 36, p 1353-94.
- [12] Dulucq JL, Wintringer P & Mahajna A (2009): Laparoscopic totally extraperitoneal inguinal hernia repair: lessons learned from 3,100 hernia repairs over 15 years. *Surg Endosc* 23: 482-6.
- [13] Kuhry E, van Veen RN, Steyerberg EW and Jeekel J (2007): Open or endoscopic total extraperitoneal inguinal hernia repair? A Systematic Review. *Surg Endosc*; 21(2):161-6.
- [14] Misra C, Kumar S and Bansal V (2008): Total extraperitoneal (TEP) mesh repair of inguinal hernia in the developing world: comparison of low-cost indigenous balloon dissection versus direct telescopic dissection: a prospective randomized controlled study. *Surg Endosc* 22:1947-58.
- [15] Schouten N, Simmermacher RKJ, Dalen TV, Smakman N, Clevers G J, Davids P H P, Verleisdonk EJMM & Burgmans JPI (2013): Is there an end of the "learning curve" of endoscopic totally extraperitoneal (TEP) hernia repair?, *Surg Endosc* 27:789-94.
- [16] Ferzli G, Shapiro K, Chaudhry G and Patel S (2004): Laparoscopic extraperitoneal approach to acutely incarcerated inguinal hernia. *Surg Endosc* 18: 228-31.
- [17] Van Steensel CJ and Weidema WF (1994): Laparoscopic inguinal hernia repair without fixation of the prosthesis. In: Arregui ME, Nagan RF, editors. *Inguinal hernia: advances or controversies?* New York: Radcliffe Medical Press; p. 435-6.
- [18] Stoppa R, Henry X and Verhaeghe P (1996): Repair of inguinal hernias without tension and without suture using a large Dacron mesh prosthesis and by preperitoneal approach: a method of reference for selective indication. *Ann Chir*, 50: 808-13.
- [19] Teng YJ, Pan SM, Liu YL, Yang KH, Zhang YC, Tian JH and Han JX (2011): A meta-analysis of randomized controlled trials of fixation versus nonfixation of mesh in laparoscopic total extraperitoneal inguinal hernia repair. *Surg Endosc*; 25: 2849-58.
- [20] Lau H, Patil NG, Yuen WK and Lee F (2002): Management of peritoneal tears during endoscopic total extraperitoneal hernia repair. *Surg. Endosc.* 16: 1474-7.
- [21] Garg P, Rajagopal M, Varghese V & Ismail M (2009): Laparoscopic total extraperitoneal inguinal hernia repair with nonfixation of the mesh for 1,692 hernias. *Surg Endosc* 23: 1241-5.
- [22] Hamza Y, Gabr E, Hammadi H and Khalil R (2010): Four-arm randomized trial comparing laparoscopic and open hernia. *Int J Surg.* 8 (1): 25-8.
- [23] Burgmans JPI, Schouten N, Clevers GJ, Verleisdonk EJMM, Davids PHP, Voorbrood CEH, Simmermacher RKJ and Van Dalen T (2015): Pain after totally extraperitoneal (TEP) hernia repair might fade out within a year, *Hernia* 19:579-85.
- [24] Stark E, Oestreich K, Wendl K, Rumstadt B and Hagmuller E (1999): Nerve irritation after laparoscopic hernia repair. *Surg Endosc.* 13: 878-81.
- [25] Lau H & Lee F (2003): Seroma following endoscopic extraperitoneal inguinal hernioplasty, *Surg Endosc* (2003) 17: 1773-7.
- [26] Bittner R, Montgomery MA, Arregui E, Bansal V, Bingener J, Bisgaard T, Buhck H, Dudai M, Ferzli GS, Fitzgibbons RJ, Fortelny RH, Grimes KL, Klinge U, Koeckerling F, Kumar S, Kukleta J, Lomanto D, Misra MC, Morales-Conde S, Reinhold W, Rosenberg J, Singh K, Timoney M, Weyhe D & Chowbey P (2015): Update of guidelines on laparoscopic (TAPP) and endoscopic (TEP) treatment of inguinal hernia (International Endohernia Society). *Surg Endosc* 29:289-321.
- [27] Singh K, Singhal A, Saggarr VR, Sharma B and Sarangi R (2004): Subcutaneous carbon dioxide emphysema following endoscopic extraperitoneal hernia repair: possible mechanisms. *Laparoendosc Adv Surg Tech A* 14(5):317-20.
- [28] Murdock CM, Wolff AJ and Van Geem T (2000): Risk factors for hypercarbia, subcutaneous emphysema, pneumothorax and pneumo-mediastinum during laparoscopy. *Obstet Gynecol* 95(5): 704-9.
- [29] Simons MP, Aufenacker T, Bay-Nielsen M, Bouillot JL, Campanelli G, Conze J, de Lange D, Fortelny R, Heikkinen T, Kingsnorth A, Kukleta J., Morales-Conde S, Nordin P, Schumpelick V, Smedberg S, Smietanski M, Weber G & Miserez M (2009): European Hernia Society guidelines on the treatment of inguinal hernia in adult patients in *Hernia* 13:343-403.

- [30] Falagas ME & Kasiakou SK (2005): Mesh-related infections after hernia repair surgery. *Clin Microbiol Infect* 2005; 1: 3–8.
- [31] Finan KR, Vick CC, Kiefe CI, Neumayer L, Hawn MT (2005): Predictors of wound infection in ventral hernia repair. *Am J Surg*; 190: 676–81.
- [32] Falagas ME & Makris GC (2010): Mesh-Related Infections After Hernia Repair, in *Hernia Repair Sequelae* edited by Schumpelick V. and Fitzgibbons RJ: Springer Medizin; CH 13, P 97-102.
- [33] Cheah WK, So JB and Lomanto D (2004): Endoscopic Extraperitoneal inguinal hernia repair. *Singapore Med. J.* vol. 45(6): 267-70.
- [34] Halm J, Hiesterkamp J and Boelhouwer R (2005): Totally extraperitoneal repair of inguinal hernia. *Enclose 19*: 1373-6.
- [35] Ujiki MB, Gitelis ME, Carbray J, Lapin B, Linn J, Haggerty S, Wang C, Tanaka R, Barrera E, Butt Z and Denham W (2015): Patient-centered outcomes following laparoscopic inguinal hernia repair, *Surg Endosc* (2015) 29:2512–9.
- [36] Colack T, Akca T and Aydin S (2003): Randomized clinical trial comparing laparoscopic totally extraperitoneal approach with open mesh repair of inguinal hernia repair. *Surg. Lap. Endosc. Percut. Tech.* 13: 191-5.
- [37] Liem MS, Van Der Graaf Y, Zwart RC and Vroonhoven TJ (1997): A randomized comparison of physical performance following laparoscopic and open inguinal hernia repair. *Br. J. Surg.*; 84: 64-57.