

**Case Report**

# Research and Analysis of the Anti-aging Treatment Process of L-polylactic Acid Injection Therapy in Plastic Surgery - A Case Report

Li Qian\*, Ali Napih Nasution, Sri Lestari

Clinical Medicine, Specialization of Clinical Surgery, Faculty of Medicine, Dentistry, and Health Science, Universitas Prima Indonesia, Medan, Indonesia

**Email address:**

13975633000@163.com (Li Qian), alinapihnasution@unprimdn.ac.id, (Ali Napih Nasution),

srilestariramadhaninasution@unprimdn.ac.id (Sri Lestari)

\*Corresponding author

**To cite this article:**

Li Qian, Ali Napih Nasution, Sri Lestari. Research and Analysis of the Anti-aging Treatment Process of L-polylactic Acid Injection Therapy in Plastic Surgery - A Case Report. Journal of Surgery. Vol. 11, No. 5, 2023, pp. 94-98. doi: 10.11648/j.js.20231105.11

**Received:** April 2, 2023; **Accepted:** April 17, 2023; **Published:** September 6, 2023

---

**Abstract:** *Research background:* In the world, youth and beauty are what everyone likes to pursue. In the medical discipline, the medical cosmetology discipline has gradually formed and become powerful. Our research is to learn the application of L-polylactic acid injection therapy in anti-aging therapy. We used L-polylactic acid injection therapy to compare the beauty effect on the pictures before and after the anti-aging treatment of patients. It provides research data and basis for the anti-aging effect of L-polylactic acid injection therapy in subsequent cosmetic medicine. *Research Purpose:* to expand the field of knowledge and skills for medical cosmetology, and lay a medical research data and theoretical foundation for the field of anti-aging treatment. *Research method:* This study is to explore a patient who requires left-polylactic acid beauty, anti-aging and filling treatment. Study the changes of their faces before and after surgery; after treatment. Draw conclusions, study and discuss. *Research Results:* a cosmetic patient with L-polylactic acid had a significant beauty effect after anti-aging and filling treatment, and no one had bleeding, necrosis, infection, allergy and other complications. *Research Conclusion:* L-polylactic acid has only an immediate filling effect, and cannot have the therapeutic effect of hyaluronic acid, that is, the long-term (3-12 months) filling effect. It mainly relies on L-polylactic acid to stimulate tissue after entering the human body to produce regeneration, so as to achieve the filling beauty effect. L-polylactic acid injection for anti-aging and filling has a certain limit in a single stimulation. It requires 2 to 5 times of multiple stimulation to achieve the patient's satisfactory effect. The interval between each stimulation is about 3-6 months. The effect of the patient varies according to the patient's own situation (under the age of 40) and the better the regeneration ability. The older you are, the worse the effect. The fatter the person, the better the effect and the better the regeneration ability. The thinner the physique, the worse the effect. The effect of patients varies according to the doctor's dosage. When using a double dose, the effect is more obvious on the same individual than the single dose.

**Keywords:** L-polylactic Acid, Anti-aging, Beauty Treatment, Beauty Medicine, Plastic Treatment

---

## 1. Introduction

Face rejuvenation is an upgrade technology of skin tightening and wrinkle removal system. There are two types of methods for facial rejuvenation: surgery and non-surgery [1]. Surgical treatment is to make certain adjustments to the facial structure through targeted surgical operations to improve and

tighten the soft tissue to restore the young appearance of the face [2-5]. Non-surgical treatment is to treat facial aging problems through a certain technique or equipment that targets a specific depth of facial structure, such as fine wrinkles, skin relaxation, pigment spots, pigmentation, capillary dilation, etc.

[6-8]. Such treatment methods include physical therapy, chemotherapy, biological therapy, etc. [9-12]. This study is to study the application analysis of one patient using left-polylactic acid injection therapy in the anti-aging treatment process, explore the facial beauty effect before and after the use of the treatment method, and provide a practical basis for subsequent research.

## 2. Clinical Information

### 2.1. Patient Information

A 30-year-old young female patient with an average BMI:  $26.4\text{kg/m}^2$  and a height of 165.0cm.

### 2.2. Laboratory and Imaging Examination

There were no obvious abnormalities in the patient's blood routine examination, coagulation function examination, complete set of blood transfusion examination, electrocardiogram examination, chest X-ray examination and abdominal color ultrasound examination.

### 2.3. Face Examination

The patient showed yellow and dark skin. The cheekbones and cheeks are sunken. Facial fat atrophy. The lower face is relaxed and wrinkled. The lower orbit is sunken.

## 3. The Operation Process

The first operation: L-polylactic acid 160mg + saline 10ml + 0.2% lidocaine 2ml is fully mixed evenly and stationary with a 20ml syringe for 20 minutes. Then, when injecting, you need to select the cheek depression of the injection first, and then wipe it with iodine volt disinfection three times. The disinfection range is smaller and smaller at a time. Spread the towel. One-half of the zygomatic arch is the needle point, and local anesthesia is given. The skin is broken with a 5ml syringe needle, in the direction of  $30^\circ\text{-}40^\circ$ , and the deep layer of the shallow temporal SMAS with a blunt needle of 23G\*50MM. The shallow area of the deep SMAS is fan-shapedly flattened in the temporal part, hairline, eyebrow and other concave area. The most depression is about 10mm higher than the original area, and the connection at the secondary depression is about 5mm, as shown in Figure 1. After injection of L-polylactic acid, the protruding plane of the depression is 5-10mm, the expansion range radius is 5mm, and the diameter is 10mm. The principle is shown in Figure 2. The right temporal area and cheek area are obviously sunken on the left side, and the right cheek takes the same needle point to be tiled into the SMAS layer of the cheek. The filling amount of the right temporal area is 4ml. The filling amount of the right cheek is 3ml, and the filling amount of the left temporal area is 3ml. The filling amount of the left cheek is 2ml. After the treatment, a certain massage is given, and the acupuncture eye is applied with erythromycin eye ointment. At the end of the treatment, the photos before and after the operation are shown in Figures 3

and 4.

The second operation process: after 1 year, the patient made an appointment for a reexamination, and the effect of cosmetic filling treatment was poor; and another operation was required. Once again, we gave L-polylactic acid (children's face needle) treatment (PLLA POWER 160mg), and we gave L-cyclopolylactic acid 160mg specification \* 2 + saline 18ml + 0.2% lidocaine 2ml with a 20ml syringe to be fully mixed evenly and stationary for 20 minutes on the operating table. The patient was given a preoperative design, routine disinfection of the towel, took half of the zygomatic arch as the needle point, local anesthesia, broke the skin with a 5ml syringe needle, and entered the deep layer of the superficial temporal SMAS with a 23G\*50MM blunt needle. The shallow area of the deep SMAS was fan-shaped flattened in the temporal part, hairline, eyebrow and other depression area. The most depression was about 20mm higher than the original area, about 20mm above the secondary depression. The connection was about 10mm, and the secondary connection was about 10mm. The principle was shown in Figure 5. The right temporal area and cheek area are obviously sunken on the left side, and the right cheek takes the same needle point to be tiled into the SMAS layer of the cheek. The filling amount of the right temporal area is 8ml, the filling amount of the right cheek is 6ml, the filling amount of the left temporal area is 6ml, and the filling amount of the left cheek is 4ml. Preoperative and postoperative photos are shown in Figures 6 and 7. After half a year of observation, the patient felt satisfied with the therapeutic effect.

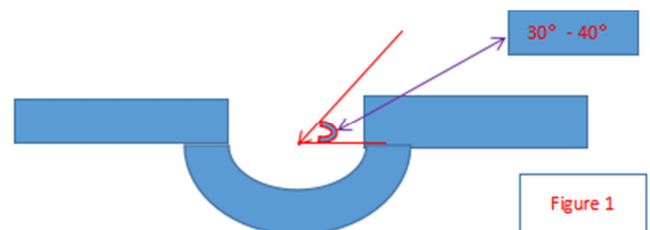


Figure 1. Schematic diagram of the process of injection of L-polylactic acid.

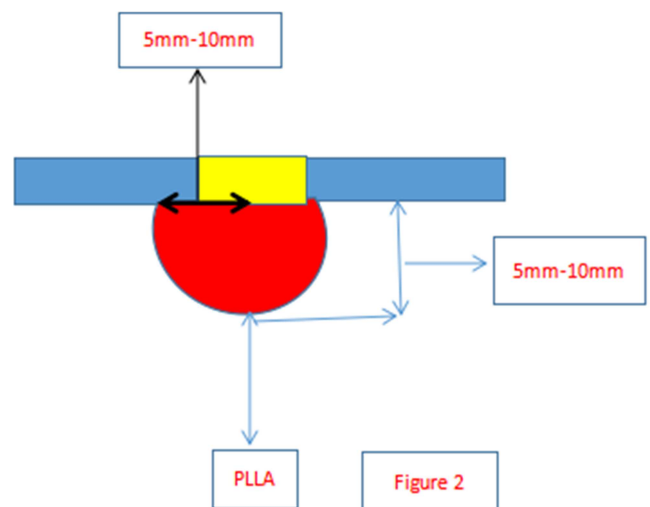
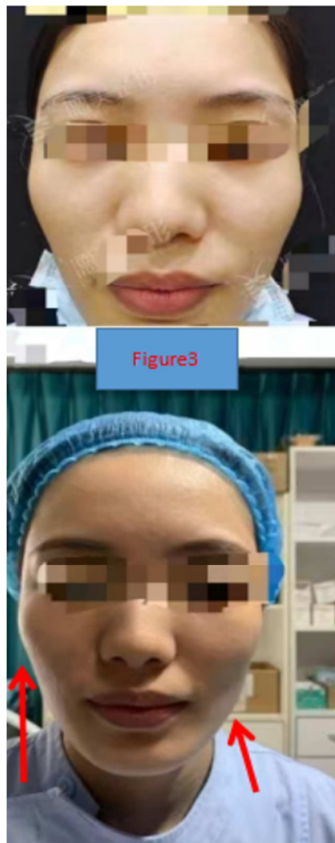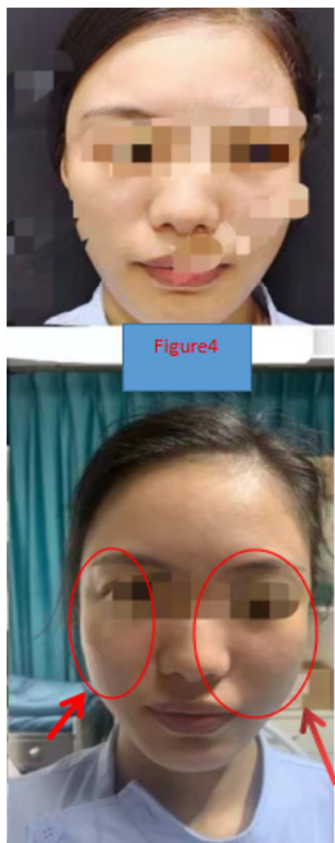


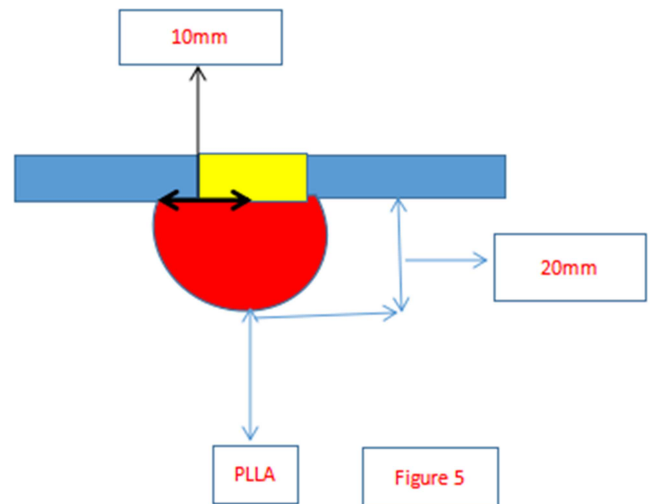
Figure 2. Injection of L-polylactic acid filling range.



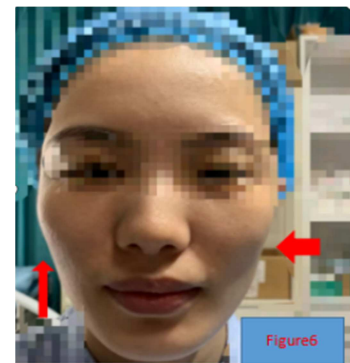
**Figure 3.** Comparison of facial cosmetic filling treatment before and after the patient's first operation. (Preoperative).




**Figure 4.** Comparison of facial cosmetic filling treatment before and after the patient's first operation. (Postoperative).



**Figure 5.** The second surgical injection of L-polylactic acid filling range.



**Figure 6.** Comparison of the effect of the second surgical injection of L-polylactic acid cosmetic filling treatment. (Preoperative).



**Figure 7.** Comparison of the effect of the second surgical injection of L-polylactic acid cosmetic filling treatment. (Postoperative).

## 4. Discussion

Tongyan needle (lev-polylactic acid) is an injection cosmetic filler. Its main ingredient is L-polylactic acid (Sculptra). L-polylactic acid can be used to fill and shaping in subside down or loose areas of the skin or correct fat atrophy caused by disease [13-14]. Its effect can usually last for 1 to 3 years [15-17]. L-polylactic acid is a man-made substance that integrates with the human body and can be decomposed and absorbed. It has two characteristics: good biocompatibility

and degradability. Its principle of action is to achieve anti-aging and tightening lifting by stimulating its own collagen hyperplasia [18]. At present, Tongyan needles have been approved for use in Hong Kong and Taiwan, and some brands in mainland China have obtained the approval of the makeup brand approved by the State Food and Drug Administration, so they still need to be cautious when using them. There are still indications and contraindications for L-polylactic acid for cosmetic filling treatment [19]. Contraindications include patients with severe chronic systemic diseases, such as heart disease, hypertension, autoimmune diseases, etc. Scar or allergic constitution, or allergic to narcotic drugs or collagen. Patients with severe hemorrhagic diseases or those who have been using antiplatelet drugs such as aspirin for a long time. There is skin damage, infection focal, or acute and chronic infection at the injection site. Mentally abnormal, or have unrealistic illusions about the effect of surgery. Women in special periods, such as menstruation, pregnancy and lactation. Indications include patients with HIV-positive (including during retroviral treatment) facial fat atrophy. Patients with good health and facial fat atrophy. Patients with sunken cheeks and cheeks. The lower face is relaxed and wrinkled. Lower orbital depression. The aging of neck lines and hands and hope to improve through non-surgical methods. Postoperative complications include infection; it is related to the failure to strictly perform sterile operations during the operation, and the inflammation of the skin before the operation is not completely cured. Allergic reactions; rarely, it may be allergic constitution or allergic to imported fluid. Redness, swelling and pain; children's face needles, like other injection materials, have some adverse reactions after injection, such as redness, swelling and pain at the injection site. Other reactions; bruises, nodules, etc. may also occur. Accurate injection is the most important factor to avoid complications. Physicians are required to fully understand the anatomical level and strictly control the injection dose and the interval between the two injections. Although there are some individual differences, if the operation is standardized, it can basically avoid complications. A small amount of uniformity is the most important injection principle. How long can the treatment effect generally last? Maintenance time: The effect of children's facial acupuncture is not permanent, and the beauty filling effect may disappear later over time [20-23]. Influencing factors: Children's face needles can stimulate collagen hyperplasia and achieve anti-aging and tightening lifting. However, the effect and specific maintenance time will be affected by the personal physique, the specific type of L-polylactic acid, the operation level, and postoperative care. Time change: Over time, L-polylactic acid will be gradually metabolized and decomposed by the human body, and the beauty effect will disappear. Beauty seekers can consider a secondary injection after consulting a doctor [24-28]. We need to fully communicate with patients about the effect, dosage, injection range, etc. of L-polylactic acid before surgery, so that patients can fully understand and support such operations, and the patient can carry out surgical treatment after signing.

## 5. Conclusion

In this study, the effect of patients was satisfactory after two injections of L-polylactic acid filling. Actively communicate with the precautions for treatment before surgery, and the patient expressed understanding and consent, and signed the treatment. L-polylactic acid injection treatment of anti-aging and filling treatment has a certain limit in a single stimulation. It requires 2 to 5 multiple stimuli to achieve the satisfactory effect of patients. The interval of each stimulation is about 3-6 months. The patient's effect varies according to the patient's own situation (under the age of 40), the better the regenerative ability. The older you are, the worse the effect. The fatter the person, the better the effect, and the better the regenerative ability. The thinner the physique, the worse the effect. The effect of the patient varies according to the doctor's dosage. When using double dosage, the effect is more obvious than double dosage in the same individual. Therefore, it is of far-reaching significance to study the application of L-polylactic acid in beauty filling therapy, which adds a practical theoretical basis for post-beauty filling therapy.

## Author's Statement

This study is approved by the author, and its case data is used for academic research. The research data is provided by Li Qian, ORCID: 0009000684424696.

Li qian: Write a paper. Ali Napiyah Nasution and Sri Lestari : Statistics, review essays and paper drawing.

## Conflicts of Interest

All authors have no conflicts of interest.

## Consent for Publication

The patient agreed to use her pictures for research and publication. The patient signed and agreed.

## References

- [1] Long Anyin. (2021). Study of high-frequency ultrasound to evaluate the safety of left-polylactic acid in facial rejuvenation [D]. Peking Union Medical College, 69 (3): 129-139.
- [2] Cui Haiyan, Zhao Haiguang, Xu Haisong, Wang Guobao, and Tan Linlin,(2021). Asian facial injection rejuvenation and aesthetic image overall design new scheme, *Aesthetic Surgery Journal Open Forum*, Volu Me 3, Issue 3, 10.
- [3] Ran Weizhi, Gao Songying. (2020). Progress in facial rejuvenation treatment in the past decade [J]. *Chinese Journal of Prosthetic and Reconstruction Surgery*, 32 (7): 809-814.
- [4] Qu Le, Cao Jiang, Huang Xinmiao. (2012). Clinical application of biodegradable poly-polyoxycyclohexanone materials [J]. *China Organizational Engineering Research and Clinical Rehabilitation*, 15 (3): 527-530.

- [5] Ren Rongxin, Ma Xiaobing, Bao Shiwei, etc. (2021). Progress in the clinical application of facial injection filling materials [J]. Chinese Journal of Aesthetic Plastic Surgery, 32 (02): 96-98.
- [6] Jiang Zhongyu, Feng Xiangru, Ding Jianxun, etc. (2020). Progress in the clinical application of polymer facial fillers [J]. Chinese Journal of Aesthetic Plastic Surgery, 29 (08): 504-506+515.
- [7] Zhao Hua, Li Hengjin. (2020). Skin filler [J]. International Journal of Dermatology, 36 (05): 262-265.
- [8] Sizhen Wang, Jie Li, Zhiqiang Ma, Linhong Sun, Lei Hou, Ying Huang, Yunchang Zhang, Beibei Guo, Feng Yang, A Sequential Therapeutic Hydrogel With Injectability and Antibacterial Activity for Deep Burn Wounds' Cleaning and Healing, *Frontiers in Bioengineering and Biotechnology*, 2023. (3) 145-149.
- [9] Lu Hongli; Xu Renchao. (2021). Detection and analysis of facial skin thickness by 24 MHz high-frequency ultrasound in healthy adults [J]. Chinese Journal of Dermatology, (04): 12-18.
- [10] Yu Ruixing; Xue Ke; Shen Xue; Cui Yong. (2020). High-frequency ultrasound detection of skin thickness and echo density of healthy adults [J]. Chinese Journal of Dermatology, (06): 25-30.
- [11] Hexsel Doris; Camozzato Fernanda; Valente Bezerra Indira; Silva F. Aline; Siega Carolina. (2021). L-Lift Technique Using Poly-L-Lactic Acid: A Pilot Study [J]. *Dermatologic Surgery*, 45-53.
- [12] Ali Nilforoushzadeh Mohammad; Zare Sona; Farshi Susan; Mahmoudbeyk Mona; Nouri Maryam; Jaffary Fariba; Nikkhah Nahid. (2021). Clinical, biometric and ultrasound assessment of the effects of the autologous fibroblast cells transplantation on nasolabial fold wrinkles. [J]. *Journal of cosmetic dermatology*, 1-13.
- [13] Mlosek Robert Krzysztof; Migda Bartosz; Skrzypek Ewa; Soboda Katarzyna; Migda Micha. (2020). The use of high-frequency ultrasonography for the diagnosis of palpable nodules after the administration of dermal fillers [J]. *Journal of Ultrasonography*, (83): 66-68.
- [14] Phillip M. Kemp Bohan; Laura E. Cooper; Khang N. Lu; David M. Raper; Maria Batchinsky; Anders H. Carlsson; Leopoldo C. Cancio; Rodney K. Chan. (2020). Fractionated Ablative Carbon Dioxide Laser Therapy Decreases Ultrasound Thickness of Hypertrophic Burn Scar: A Prospective Process Improvement Initiative. [J]. *Annals of plastic surgery*, 138-145.
- [15] Nikolis Andreas; Enright Kaitlyn M; hrlund ke; Winlf Per; Cotozana Sebastian. (2020). A randomized, split-face, double-blind, comparative study of the safety and efficacy of small- and large-particle hyaluronic acid fillers for the treatment of nasolabial folds. [J]. *Journal of cosmetic dermatology*, (5): 1-15.
- [16] Mazzuco Rosemarie; DalForno Taciana; Afonso Dini Simone. (2020). Subcutaneous Versus Supraperiosteal Injections of Poly-L-Lactic Acid: A Clinical and Imaging Study. [J]. *Dermatologic surgery: official publication for American Society for Dermatologic Surgery* [et al.], 345-349.
- [17] Subarna Ray; Hang T Ta. (2020). Investigating the Effect of Biomaterials Such as Poly-(L-Lactic Acid) Parti. *Journal of Functional Biomaterials*, (3) 145-149.
- [18] Nilforoushzadeh Mohammad Ali; Alavi Shiva; Heidari-Kharaji Maryam; Hanifnia Amir Reza; Mahmoudbeyk Mona; Karimi Zahra; Kahe Farima. (2020). Biometric changes of skin parameters in using of microneedling fractional radiofrequency for skin tightening and rejuvenation facial. [J]. *Skin research and technology: official journal of International Society for Bioengineering and the Skin (ISBS) [and] International Society for Digital Imaging of Skin (ISDIS) [and] International Society for Skin Imaging (ISSI)*, (6).
- [19] Bravo Bruna Souza Felix; de Melo Carvalho Raquel; Souza Eduardo; Vargas Thiago Jeunon De Souza; Bravo Leonardo Gonaves. (2020). Ultrasound-guided poly-l-lactic acid nodule excision: The importance of the injector ultrasonographic experience. [J]. *Journal of cosmetic dermatology*, (2).
- [20] K. C. Lee; A. Bamford; F. Gardiner; A. Agovino; B. ter Horst; J. Bishop; L. Grover; A. Logan. (2020). Burns objective scar scale (BOSS): Validation of an objective measurement devices based burn scar scale panel [J]. *Moiemen. Burns*, (1).
- [21] Lima Vanessa Guimaraes de Freitas; Regattieri Neysa Aparecida Tinoco; Pompeu Marcelo Faro; Costa Izelda Maria Carvalho. (2019). External vascular compression by hyaluronic acid filler documented with high-frequency ultrasound. [J]. *Journal of cosmetic dermatology*, (6): 111-117.
- [22] Lin Matthew J. Dubin Danielle P. Goldberg David J. Khorasani Hooman. (2019). Practices in the Usage and Reconstitution of Poly-L-Lactic Acid [J]. *Journal of drugs in dermatology: JDD*, (9).
- [23] Wortsman Ximena; Carreo Laura; Ferreira-Wortsman Camila; Poniachik Rafael; Pizarro Kharla; Morales Claudia; Calderon Perla; Castro Ariel. (2019). Ultrasound Characteristics of the Hair Follicles and Tracts, Sebaceous Glands, Montgomery Glands, Apocrine Glands, and Arrector Pili Muscles. [J]. *Journal of ultrasound in medicine: official journal of the American Institute of Ultrasound in Medicine*, (8): 1-9.
- [24] Ibrahim Omer; Ionta Sarah; Depina Joaninha; Petrell Kathleen; Arndt Kenneth A; Dover Jeffrey S. (2019). Safety of Laser-Assisted Delivery of Topical Poly-L-Lactic Acid in the Treatment of Upper Lip Rhytides: A Prospective, Rater-Blinded Study. [J]. *Dermatologic surgery: official publication for American Society for Dermatologic Surgery* (7): 234-236.
- [25] Madni Tarik D; Lu Karen; Nakonezny Paul A; Imran Jonathan B; Cunningham Holly B; Clark Audra T; Taveras Luis; Hoopman John E; Wolf Steven E; Kenkel Jeffrey M; Phelan Herb A. (2019). Treating Hypertrophic Burn Scar With 2940-nm Er: YAG Laser Fractional Ablation Improves Scar Characteristics as Measured by Noninvasive Technology. [J]. *Journal of burn care & research: official publication of the American Burn Association*, (4): 1-5.
- [26] Bohnert Krista; Dorizas Andrew; Lorenc Paul; Sadick Neil S. (2019). Randomized, Controlled, Multicentered, Double-Blind Investigation of Injectable Poly-L-Lactic Acid for Improving Skin Quality. [J]. *Dermatologic surgery: official publication for American Society for Dermatologic Surgery* [et al.], (5): 678-679.
- [27] Kim Sung Ae; Kim Hyo Seon; Jung Jin Woong; Suh Sung Il; Ryoo Young Wook. (2012). Poly-L-Lactic Acid Increases Collagen Gene Expression and Synthesis in Cultured Dermal Fibroblast (Hs68) Through the p38 MAPK Pathway [J]. *Annals of Dermatology*, (1): 987-988.
- [28] Murad Alam; Rebecca Tung. (2020). Injection technique in neurotoxins and fillers: Indications, products, and outcomes [J]. *Journal of the American Academy of Dermatology*, (3): 6-11.