

**Case Report**

Double Stangulation by an Ileosigmoid Knot About an Observation and Review of the Literature

Bangoura Mohamed Saliou^{1,2,*}, Bouraoui Ridjial Hadar³, Fofana Aminata^{1,2},
Youla Alpha Mohamed^{1,2}, Yattara Abdoulaye³, Soumaoro Labile Togba^{1,2}, Toure Aboubacar^{1,2}

¹Department of General Surgery, Ignace Deen National Hospital, University Hospital of Conakry, Conakry, Guinea

²Faculty of Health Sciences and Techniques, Gamal Abdel Nasser University of Conakry, Conakry, Guinea

³Department of General Surgery, Aristide Le Dantec Hospital, Dakar, Senegal

Email address:

medsaliou@yahoo.fr (Bangoura Mohamed Saliou)

*Corresponding author

To cite this article:

Bangoura Mohamed Saliou, Bouraoui Ridjial Hadar, Fofana Aminata, Youla Alpha Mohamed, Yattara Abdoulaye, Soumaoro Labile Togba, Toure Aboubacar. Double Stangulation by an Ileosigmoid Knot About an Observation and Review of the Literature. *Journal of Surgery*. Vol. 10, No. 5, 2022, pp. 190-192. doi: 10.11648/j.js.20221005.20

Received: September 19, 2022; **Accepted:** October 18, 2022; **Published:** October 28, 2022

Abstract: *Introduction:* Occlusions by ileo-sigmoid nodes are rare etiologies of occlusions by strangulation, which can quickly engage the vital prognosis if the management is not early. *Patient and observation:* herein we reported case of an acute intestinal obstruction by ileo-sigmoid node observed at the regional hospital of Ndioum in the north of Senegal. A patient of 35 years old without any particular history was sent to us for the management of a syndrome of peritoneal irritation. On admission there was abdominal distension with hypogastric arch, diffuse abdominal tenderness, with abdominal meteorism. She performed a plain x-ray of the abdomen which was not diagnostically helpful. She benefited from an exploratory laparotomy during which we highlighted a double grelic and colonic strangulation by an ileo-sigmoid knot, a double grelic and colonic resection was performed and the postoperative course was simple. *Conclusion:* Occlusion by ileo-sigmoid node is a very rare condition, characterized by its clinico-radiological polymorphism, which also means that the diagnosis is made late. Surgical treatment remains the cornerstone of the management of this condition.

Keywords: Occlusion, Ileosigmoid, Surgery

1. Introduction

The ileo-sigmoid node is a double volvulus involving the sigmoid and the small intestine with a rapid evolution towards intestinal necrosis. Its preoperative diagnosis remains difficult, hence the importance of knowing its mechanism and looking for characteristic radiological signs for early diagnosis and appropriate management. [1].

It is most often a volvulus of the hial around the sigmoid colon causing its torsion. More rarely it is the sigmoid colon that twists around the meso of the small intestine. This leads to complex bowel obstruction leading to ischemia and often necrosis of one or both volvulated segments. [1].

2. Patient and Observation

We reported the observation of 35 female, never operated, not known hypertensive or diabetic who was referred for a peritoneal irritation syndrome evolving for 4 hours.

On admission there was a preserved general status, with the following parameters: Blood pressure 10/8cmhg, pulse 120pulsations/min, respiratory rate 26pulsations/min, temperature 37.7°C. The abdomen was distended with a hypogastric arch, there was diffuse abdominal tenderness throughout the abdomen, with periumbilical meteorism. The hernial orifices were free. Examination extended to other systems was normale. An unprepared abdominal X-ray, which contributed little to the diagnosis apart from colonic clarity

with no real double limb (figure 1). Biological explorations were negatives. The indication for an exploratory laparotomy was concluded and performed. The exploration revealed a hematic fluid emanating from the cavity; a torsion of the sigmoid colon on a knot (figure 2) made of hail which was involuted, with single grelic perforation of about 0.5cm on the antemesenteric face located 40cm from the ileo-caecal junction. We observed a long meso-sigmoid which was surely the favoring factor of torsion. A double resection followed by an end-to-end ileo-ileal anastomosis, a sigmoidectomy with end-to-end colorectal anastomosis were performed.

The postoperative follow-up was simple.

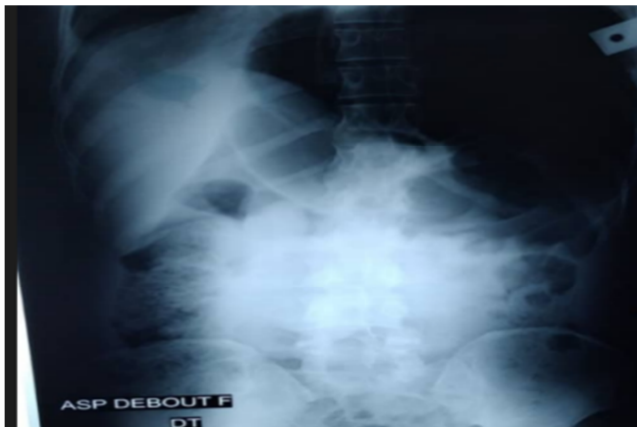

Figure 1. X-ray of the abdomen showing a gaseous hyperclarity.

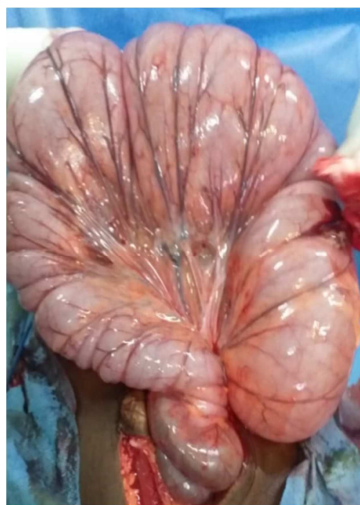


Figure 2. Operative view of the ileo sigmoid knot.

3. Discussion

Volvulus of the sigmoid colon is the most frequent among the intestinal volvulus, it represents 10 to 30% of the intestinal occlusions [1-3]. This percentage increases to reach 20 to 54% in the East while it is only 3 to 5% in Western countries [1].

The ileosigmoid node (NIS) is a rare pathology and mainly affects male subjects in the fourth decade, which is somewhat the opposite in our patient [4-8].

It occurs in the majority of cases when a small bowel loop descends into the left paracolic gutter and turns around the

base of the sigmoid colon clockwise or counterclockwise and forms a knot. However, in a minority of cases the sigmoid may be the active component in the occurrence of the obstruction by increasing peristalsis with twisting of the two portions of intestines and double strangulation. Depending on the tightening force of the knot and the engagement of the mesentery, this compression can rapidly cause ischemic necrosis of the ileum and colon (74-80%) [9].

There are 4 types of mechanisms of formation of the NIS, depending on the active digestive segment responsible for the torsion, in type I the ileum is the active segment wrapping around the passive sigmoid, type II results from the active sigmoid torsion which attracts passive hail, in exceptional type III it is the ileocecal junction that wraps around the sigmoid loop, while in indeterminate type IV it is not possible to differentiate the two segments. [6].

Several factors have been incriminated to explain this pathology, in particular anatomical predispositions, such as hypermobility of the small intestine, too long a meso and a short root can curl at the foot of the sigmoid colon [3, 10, 11].

The radiological diagnosis is difficult in front of the atypia of the signs but the abdomino-pelvic scanner is a key examination making it possible to suspect the diagnosis by highlighting a dilation of the sigmoid and the small loops most often in a state of suffering associated with a defect of parietal enhancement [2, 12-14].

Preoperative diagnosis is difficult because of its rarity and clinico-radiological atypia.

The symptomatology in our patient was atypical, the x-ray of the abdomen without preparation which was made could not help to make the diagnosis of this condition.

The diagnosis of occlusion by ileo-sigmoid node was only made intraoperatively.

The approach is a midline laparotomy above and below the umbilical; the surgical gesture depends on the intraoperative circumstances, when the intestine is viable, some authors opt for the temptation of the simple lifting of the node, others prefer the resection of the sigmoid colon to prevent recurrences. In the event of intestinal necrosis, resection of the hail, colon and node in one piece is recommended. An end-to-end or latero-coecal anastomosis is the rule, associated with an end-to-end colo-colic anastomosis if the local and general conditions allow it, otherwise a left iliac colostomy is required, detorsion and sigmoidopexy is recommended in the rare cases where there is no sigmoid necrosis [15, 16].

We made a median incision above and below the umbilical and the procedure consisted of a double small bowel and sigmoid resection with simple consequences.

4. Conclusion

Occlusion by ileo-sigmoid node is a very rare condition, characterized by its clinico-radiological polymorphism, which also means that the diagnosis is made late. Surgical treatment remains the cornerstone of the management of this condition. In the absence of necrosis, primary anastomosis remains the best surgical procedure in our environment.

References

- [1] RAHIOUI F, DAOUDI A, OUKASSE S AND ALAMI MH. Ileo-sigmoid node, a rare postpartum complication: about a case. Ileosigmoid knotting, a rare postpartum complication: About a case International Journal of advanced research 2020; 8 (06): 234-236.
- [2] MAJDOUB HE, MOUSSA MB, MAROUANE B et al Intestinal obstruction on ileosigmoid node in a postpartum woman: about a case and review of the literature. Bowel obstruction on Ileosigmoidal knotting in the postpartum period: case report and literature review. International Journal of Medical 2020; 4 (8): 14-17.
- [3] ATAMANALP SS, OREN D, BASOGLU M, YILDIRGAN MI et al. Ileosigmoidal knotting: outcome in 63 patients. Say Colon Rectum. 2004; 47 (6): 906-10.
- [4] JAMES DIDIER, CHAIBOU MS, ADAMA. S IDÉ K, ABDOULAYE MB, ADAKAL, ADAMOU H, ISSAKA GAZOBY SIDIBE. T Intestinal Obstructions By Ileo-Sigmoid Node: Diagnostic, Therapeutic And Prognostic Aspects. European Scientific Journal 2017; 13 (33): 1857-7881.
- [5] BENSARDI FZ, ELHATTABI K, FADIL A et al. The ileosigmoid knot: about 2 cases. Pan African Medical Journal. 2012; 11: 43.
- [6] ALVER O, ÖREN D, TIRELI M et al. Ileosigmoid knotting in Turkey Review of 68 cases. Say Colon Rectum. 1993; 36 (12): 1139-47.
- [7] AKGUN Y. Management of Ileosigmoid knotting. Br Surg. 1997; 84: 672-673.
- [8] HACHIMATO T, YAMAGUCHI J, FUJIOKA H et al. Two cases of Ileosigmoid knot: the youngest reported patient and CT findings. Hepato-gastroenterology. 2004; 51: 771-773.
- [9] BOUKHALIT H, ZAMANI O, JROUNDI L. A case of ileosigmoid node in a postpartum woman. Pan African Medical 2019. 32. 106. 13542.
- [10] SHEPHEAD JJ. Ninety two cases of Ileosigmoid knotting in Uganda. Br J Surg. 1967; 54: 561-566.
- [11] UDEZUE NO. Sigmoid volvulus in Kaduna, Nigeria. Dis colon rectum 1990; 33: 647-9.
- [12] UCAR NS, YUKSEL BC, HENGIRMEN S. Did ileal knotting trigger labor or did labor cause ileal knotting? Report of a case. Surg Today. 2009; 39 (5): 440-3.
- [13] TOURE AO, KA I, GNANGNON F, et al. Ileo-sigmoidal nodes about 3 cases European Scientific Journal 2017; 13 (33): 1857-7881.
- [14] SANI R, DIDIER JL, CHAIBOU MS et al. Chirurgical colic emergencies in adults at the national hospital of Niamey (Niger). J Afr Chir Digest 2011; 11 (1): 1162-1166.
- [15] BAWA D IKENNA EC, UGWU BT Ileosigmoid knotting: a case for primary anastomosis Niger J Med 2008; 17 (1): 115-7.
- [16] KOTISSO B, BEKELE A Ileo-sigmoid knotting in Addis Ababa: a three-year comprehension retrospective analysis Ethiop Med J 2006; 44 (4): 377-83.