

# Bifocal Patellar Tendon Avulsion Fracture in a Child

Elisa Mareddu<sup>1,\*</sup>, Jocelyn Corbaz<sup>1,2</sup>, Romain Desmarchelier<sup>1</sup>, Aurélien Traverso<sup>1,2</sup>

<sup>1</sup>Orthopaedics and Traumatology Department, Ensemble Hospitalier de la Côte, Morges, Switzerland

<sup>2</sup>Orthopaedics and Traumatology Department, University of Lausanne (UNIL), Lausanne, Switzerland

## Email address:

elisa.mareddu@gmail.com (E. Mareddu), jocelyn.corbaz@gmail.com (J. Corbaz), romain.desmarchelier@ehc.vd.ch (R. Desmarchelier), aurelien.traverso@ehc.vd.ch (A. Traverso)

\*Corresponding author

## To cite this article:

Elisa Mareddu, Jocelyn Corbaz, Romain Desmarchelier, Aurélien Traverso. Bifocal Patellar Tendon Avulsion Fracture in a Child. *Journal of Surgery*. Vol. 9, No. 4, 2021, pp. 188-192. doi: 10.11648/j.js.20210904.18

**Received:** July 5, 2021; **Accepted:** July 19, 2021; **Published:** July 29, 2021

---

**Abstract:** The avulsion fracture of the patellar tendon from its proximal and distal attachment is extremely rare. Only a few cases have been described in the English literature and many aspects are still poorly understood. During our practice we came across the case of a 13 year old boy with the above mentioned lesion that we present hereby. Other than describing our experience we tried to tackle the different questions surrounding this lesion, with a careful analysis of the previous reports. A “weaker bone” was considered the main risk factor without any connection with a particular disease or condition. We found out that it is a mainly a pediatric problem, due to the particular bone structure of this population, with many of the subjects being affected by Osgood–Schlatter disease. Different authors have reported their experiences and hypothesis concerning the mechanism behind this injury that has yet to be clearly defined. However most of them mentioned an eccentric load over a knee in forced flexion, leading us to believe that this could be the main source of this unique type of disruption of the extensor apparatus of the knee. Moreover the diagnosis can be quite challenging with many authors advocating for the use of advanced imaging. Treatment options are multiples and the choice relies for the most part on the practitioner preference. From what emerged from the available data it is almost exclusively surgical. Independently from the selected technique, the outcomes are generally favorable.

**Keywords:** Patellar Tendon Rupture, Bifocal Patellar Tendon Lesion, Tibial Tuberosity Avulsion, Tibial Tuberosity Fixation, Knee Extensor Lesion

---

## 1. Introduction

An abrupt and intense muscle contraction might easily result in the rupture of the muscle itself, its tendon or an avulsion fracture at its insertion. The latter would be the most probable lesion if the bone is weakened for whichever pathological or physiological condition, such as infancy.

The main difference between the child immature skeleton and the adult skeleton is the presence of physes and apophyses. These regions of growing cartilage make children's bone significantly weaker when compared to the mature one. Moreover even the attached ligaments and tendons are stronger than the surrounding bone; hence a sudden tensile stress will provoke a fracture of the physis rather than tearing of the soft tissue. [1]

Avulsion fractures of the extensor apparatus of the knee

are uncommon and they occur predominantly in the pediatric population for the above mentioned reasons.

Fractures of the tibial tubercle are fairly rare and account for less than 1% of epiphyseal injuries. [2] The same can be said for the inferior patellar pole. [3]

The combination of these two entities is exceedingly rare. To our knowledge only 12 cases were previously documented in the general population, in the whole English literature.

Hereby we report the case of a 13 year old male presenting with two simultaneous avulsion fractures from the distal patella and tibial tubercle following a direct blow on the knee while jumping. We describe the initial examination, radiologic findings, pre-operative plans, and surgical treatment and follow up at 18 months.

The purpose of this report is to increase awareness and knowledge over this atypical injury pattern hoping that our experience might benefit other physicians. Moreover many characteristics are still not clearly understood for instance risk factors, causing mechanism, adequate imaging techniques to be used, choice of treatment and the results of the different therapeutic strategies adopted. Thus we conducted a careful analysis of the available data looking for patterns that might elucidate those aspects.

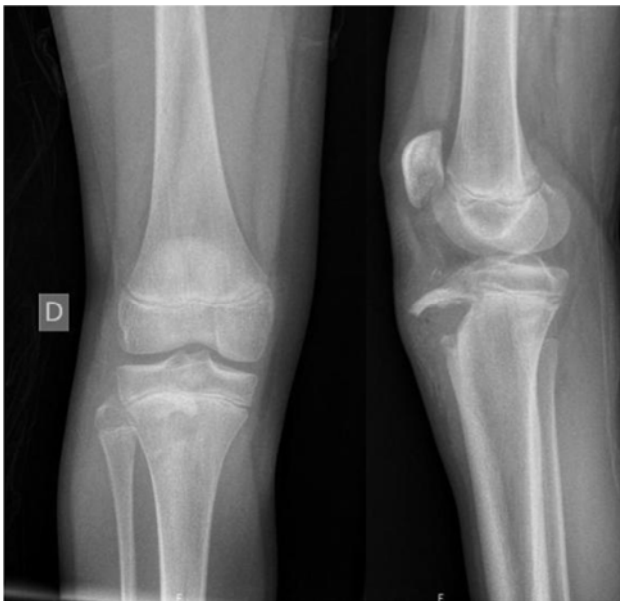## 2. Bifocal Patellar Tendon Avulsion Fracture in a Child

### 2.1. Case Presentation

A 13-year-old boy known for bilateral Osgood–Schlatter disease was brought to our emergency department after a direct impact of his right knee against a metal bar while jumping. He experienced immediate pain and was incapable of weight bearing on the right leg. Moreover, he could not extend his lower leg actively. The knee was oedematous, but without excoriations or skin lacerations. A sharp bony fragment was palpable within the subcutaneous tissues. Neurologic and vascular examinations were unremarkable.

### 2.2. Investigations

Radiographs of the knee (Figure 1) showed an avulsion fracture from the tibial tuberosity with the bony component drawn proximally. The tibial tubercle avulsion was described as being a Watson-Jones type 2 [4] (Ogden IIB [5]) (Table 1), while the distal patellar lesion was characterized as a sleeve-like fracture.



**Figure 1.** Initial AP and lateral X-rays of the right knee of our patient. The tibial tubercle fracture is evident in the lateral views, however the patellar fracture is barely visible.

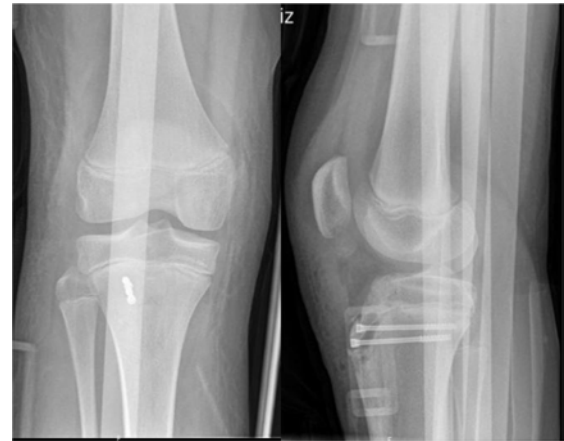**Table 1.** Ogden classification of tibial tubercle fractures in children.

TYPE	DESCRIPTION
IA	Fracture line passes through the ossification center of the tibial tubercle
IB	Same as IA with antero-superior displacement
IIA	Fracture line passes at the junction between the ossification centers of the proximal tibia end and the tibial tubercle
IIB	Same as IIA with comminution of the tibial tubercle
IIIA	Intra-articular fracture line (passes through the ossification center of the proximal tibia end) with discontinuity of the joint surface
IIIB	Same as IIIA with comminution of the tibial tubercle

### 2.3. Treatment

The patient underwent open reduction and internal fixation under general anesthesia.

Anatomic reduction was achieved under direct visualization and fixation was assured by 2 cannulated screws of 4.0 mm with a washer (Asnis III, Stryker, Selzach, Switzerland) (Figure 2). The patellar fracture did not involve the distal pole in its entirety, consequently we let it heal without any surgical interference, with good results.



**Figure 2.** Immediate postoperative AP and lateral X-ray. Surgical fixation with cannulated screws of the tibial tubercle avulsion fracture is evident.

He was subsequently immobilized in a long leg brace with non-weightbearing for 3 weeks after which we allowed him to bear weight as tolerated with crutches for the following 3 weeks.

### 2.4. Follow-up

The Knee Injury Osteoarthritis Score (KOOS)-Child [6] and the Lower Extremity Functional Scale (LEFS) [7] were employed to assess his progress.

At 6 weeks his KOOS child score was satisfactory although he experienced some difficulties in his quality of life and daily living. (Figure 3) His LEFS score was 71/80.

At the 3 months follow-up his KOOS child was 100 for every different dimension and his LEFS 80/80. At this point we authorized the patient to resume sport.

At 1 year his sole complaint was a certain degree of discomfort over the tibial tubercle, for which we performed the hardware removal (Figure 4), with resolution of the symptoms.

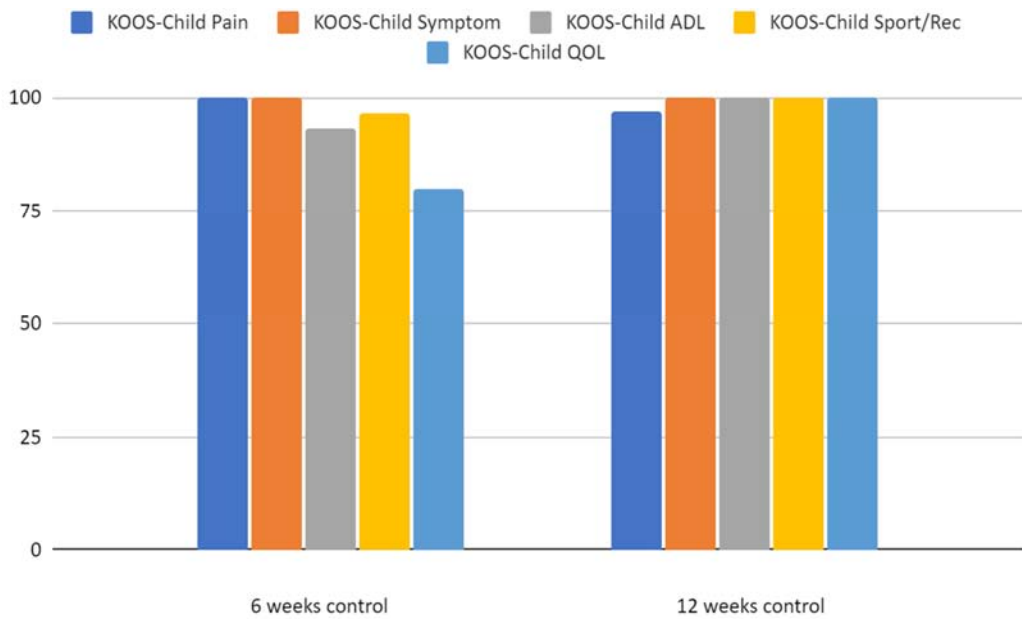


Figure 3. KOOS-Child score progression at 6 weeks and 12 weeks.

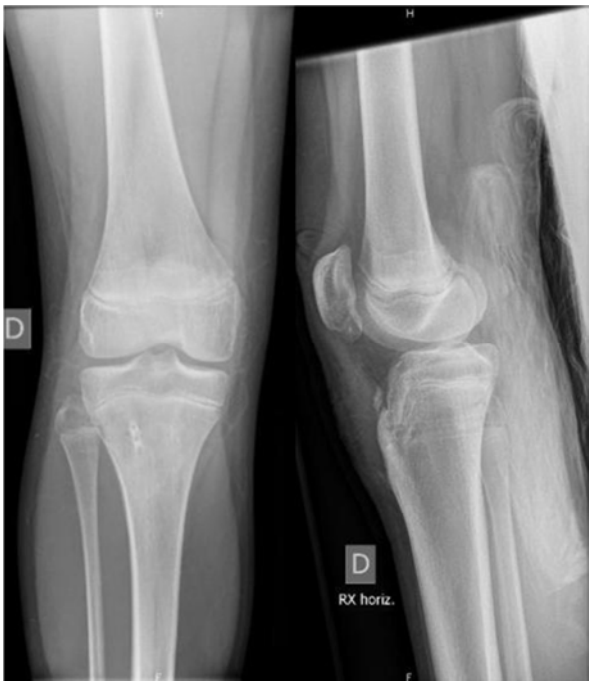

Figure 4. AP and lateral X-rays after the hardware removal showing consolidation of the fractures.

We want to stress the absence leg length discrepancy or recurvatum deformity (growth arrest anteriorly and continues

posteriorly leading to decrease in tibial slope) throughout the follow-up.

2.5. Discussion

The classification of tibial tubercle fractures in adolescents was firstly described in 1955 by Watson-Jones [4] and was later modified by Ogden et al. [5] in the 80s. This system identifies three types of fracture involving progressively the tubercle, the physis and the knee joint with type A and B sub-divisions according to the comminution and displacement (Table 1). Given the rarity of a combined fracture of the distal pole of the patella and the tibial tubercle there is no definite classification for this specific lesion, however Frankl et al. [8] in 1990 addressed the possibility of a type C injury involving the patellar ligament avulsion. In more recent years Kang et al. [9] proposed a five types classification (Table 2) of double disruption of the knee extensor mechanism based on anatomical locations and injury patterns. Accordingly we describe a type 4—avulsion fracture of the tibial tubercle with avulsion fracture of the inferior pole of the patella, described as exceedingly rare by the author himself since at the time of Kang publication there was just a previous episode documented.

Table 2. Kang classification of bifocal disruption of the knee extensor mechanism.

TYPE	DESCRIPTION
I	Fracture of the tibial tubercle with avulsion of the patella ligament from the tibial tubercle
II	Fracture of the distal pole of the patella with avulsion of the patella ligament from the tibial tubercle
III	Fracture of the tibial tubercle with avulsion of the quadriceps tendon from the proximal pole of the patella
IV	Fracture of the tibial tubercle with fracture of the inferior pole of the patella
V	Avulsion of the quadriceps tendon and the patellar tendon from the patella

**Table 3.** Summary of all the reported cases.

Author	Age	Sex	Medical History	Mechanism	Diagnosis	Treatment		Evolution > 6 months
						Inferior pole of patella	Tibial footprint	
S. Sidharthan et al. 2020	12+5	M	None known	Eccentric load on the knee	Intra-operatively			Extensor Lag 10°, normal activity
S. Sidharthan et al. 2020	14+2	M	None known	Eccentric load on the knee	X-ray + MRI			Full ROM, activities as tolerated
S. Sidharthan et al. 2020	12+10	M	None known	Eccentric load on the knee	X-ray + MRI	Suture anchor with heavy nonabsorbable suture	Double row suture anchor repair with heavy nonabsorbable suture with Krakow stitch	Full ROM, normal activity
S. Sidharthan et al. 2020	14+6	M	Osgood-Schlatter disease	Eccentric load on the knee	X-ray + MRI			Full ROM, activities as tolerated, mild quad atrophy
S. Sidharthan et al. 2020	11+2	F	Osgood-Schlatter disease	Eccentric load on the knee	X-ray + MRI			Full ROM, activities as tolerated
R Chautems et al. 2001	90	F	Diabetes + Osteoarthritis	Direct blow on the knee	X-ray	Two vertical pins and a figure-eight wire cerclage	Three staples and wire cerclage	Good recovery; specifics not given
L. Hermansen et al. 2016	12	M	Patellar dislocation	Eccentric load on the knee	X-ray (challenging)	Two JuggerKnot anchors with Maxbraid suture	Two JuggerKnot anchors and wire cerclage	Full ROM, normal activity
S. Kang at al. 2013	84	M	None known	Direct blow on the knee	X-ray	Three non-absorbable 2.0 Ethibond sutures in a vertical wiring technique	One 4.0 mm diameter cannulated screw	Full ROM, mild quad atrophy
V. Bradko et al. 2018	13	M	Patellar dislocation (controlat.)	Eccentric load on the knee	Intra-operatively	Non-absorbable suture in a Krakow type pattern run through two bone tunnels in the patella	One staple	Full ROM, normal activity
V. Bradko et al. 2018	12	M	Osgood-Schlatter disease	Eccentric load on the knee	X-ray + MRI		Screw and staple + Krackow sutures over bone bridge in anterior tibia	Full ROM, normal activity
J. Yoon et al. 2007	72	M	Ectopic ossification of patellar tendon + Osteoarthritis	Twist	X-ray	Double tension band wirings technique		Full ROM, normal activity
Stepanovich et al., 2016	12	M		Direct blow on the knee	CT-scan	Three cannulated screws and sutures		Full ROM, normal activity
Mareddu et al., 2021	13	M	Osgood-Schlatter disease	Direct blow on the knee	X-ray	Two cannulated screws and sutures		Full ROM, normal activity

Bifocal fracture avulsion of the patellar tendon is an extremely rare occurrence with only a handful of cases reported in the English literature [1, 9-14]. It involves primarily male children (mean age 12.8) (Table 3), with only 3 adult cases. Hence a fragile bone seems to be the main risk factor. This is further highlighted by the presence of an underlying bone disease in the majority of the subjects (61.5%) (Table 3). Interestingly up to 44% of the pediatric population were affected by Osgood-Schlatter disease [10, 11] (Table 3). Other conditions reported in the literature are previous episodes of patellar dislocation [1, 11], ectopic ossifications of the patellar tendon [13], osteoarthritis [12, 13] and diabetes [12].

Pathophysiology is poorly understood. L. Hermansen et al. [1] suggested three main mechanisms of injury: a direct hit on the distal patella with the knee forced in flexion; an impact in the central portion of the patellar tendon with forces spreading towards the two bony insertions; an overload of the quadriceps that causes an eccentric contraction of the muscle as the knee is forced into flexion. According to the scarce reports available an eccentric load over the knee was found responsible in 62% of the cases (Table 3), leading us to believe that this might be the main causing mechanism, 30% of the patients presented after a direct strike on their patella (Table 3). One patient claimed a twisting injury even though the authors evoked a bidirectional force acting at the bony attachments of

the tendon as a result of it. Consequently the available data confirms Hermansen's hypothesis.

The radiographic evaluation can be quite challenging. Our patient presented with an evident fracture of the tibial tubercle and a much less obvious sleeve-like fracture on the distal pole of the patella that we were still able to identify on plain X-ray. However most authors report the need of advanced imaging to reach the proper diagnosis, such as magnetic resonance (MRI) [1, 10, 11, 14]. S. Sidharthan et al. [10] employed MRI for the evaluation of all their patients and in one of them the bifocal nature of the lesion was appreciated only intra-operatively. Bradko et al. [11] described similar experience with the need of MRI and intraoperative diagnosis. Overall X-ray was not sufficient in more than two-thirds of the cases. (Table 3)

Operative methods are multiples and chosen accordingly the institution protocols and surgeon preference. Most of the authors opted for suture anchor repair with heavy nonabsorbable sutures for the patella repair [15] and staples and/or screws for proximal tibia (Table 3). We decided to perform an osteosynthesis with screws in the optic of leaving to our patient the possibility of a material removal and recover a knee without any foreign body.

Optimal functional results were noticed on both clinical exams and self-assessed validated patient scores independently from the choice of treatment (Table 3). All

patients retrieved a full range of motion, except one that developed a 10° extension lag [10]. A mild quadriceps atrophy was signaled twice [9, 10]. Two cases disclosed some impediment in restoring normal activity [10]. In the pediatric population neither leg length discrepancy nor recurvatum deformity was observed.

### 3. Conclusion

In conclusion an immature and brittle bone seems to be the main risk factor since it occurs mostly in children, and almost half of this population was affected by Osgood-Schlatter disease. The mechanism is poorly understood, however statistically the majority of the patients presented after an eccentric contraction of the quadriceps during forced knee flexion or a direct blow on the patellar tendon with forces extending through the bony insertions. Diagnosis can be problematic with some authors reporting an intra-operative discover of the bifocal avulsion-fracture and suggesting the use of advanced imaging. Independently from the surgical technique chosen the outcomes are generally favorable with a preponderance of cases going back to their pre-injury state.

### References

- [1] Hermansen LL, Freund KG. Bifocal osseous avulsion of the patellar tendon from the distal patella and tibial tuberosity in a child. *Knee Surg Sports Traumatol Arthrosc.* 2016 Mar; 24 (3): 712-4. doi: 10.1007/s00167-015-3800-8. Epub 2015 Sep 26. PMID: 26410095.
- [2] Bolesta MJ, Fitch RD. Tibial tubercle avulsions. *J Pediatr Orthop.* 1986 Mar-Apr; 6 (2): 186-92.
- [3] Galla M, Lobenhoffer P. Patella fractures. *Chirurg.* 2005 oct; 76 (10): 987-97.
- [4] Watson-Jones R (1955) *Fractures and joint injuries*, vol 2, 4th edn. Williams & Wilkins, Baltimore, MD.
- [5] Ogden JA, Tross RB, Murphy MJ (1980) Fractures of the tibial tuberosity in adolescents. *J Bone Joint Surg Am* 62: 205-215.
- [6] Örtqvist M, Roos EM, Broström EW, Janarv PM, Iversen MD. Development of the Knee Injury and Osteoarthritis Outcome Score for children (KOOS-Child): comprehensibility and content validity. *Acta Orthop.* 2012 Dec; 83 (6): 666-73. doi: 10.3109/17453674.2012.747921. Epub 2012 Nov 11. PMID: 23140110; PMCID: PMC3555443.
- [7] Mehta SP, Fulton A, Quach C, Thistle M, Toledo C, Evans NA. Measurement Properties of the Lower Extremity Functional Scale: A Systematic Review. *J Orthop Sports Phys Ther.* 2016 Mar; 46 (3): 200-16. doi: 10.2519/jospt.2016.6165. Epub 2016 Jan 26. PMID: 26813750.
- [8] Frankl U, Wasilewski SA, Healy WL. Avulsion fracture of the tibial tubercle with avulsion of the patellar ligament. Report of two cases. *J Bone Joint Surg Am.* 1990 Oct; 72 (9): 1411-3. PMID: 2229123.
- [9] Kang S, Chung PH, Kim YS, Lee HM, Kim JP. Bifocal disruption of the knee extensor mechanism: a case report and literature review. *Arch Orthop Trauma Surg.* 2013 Apr; 133 (4): 517-21. doi: 10.1007/s00402-013-1696-7. Epub 2013 Feb 15. PMID: 23411937.
- [10] Sidharthan S, Schlichte LM, Green DW, Scher DM, Fabricant PD. Bifocal Patellar Tendon Avulsion Fractures in Children and Adolescents: Diagnosis and Treatment Considerations for a Unique Injury Pattern. *Arthrosc Sports Med Rehabil.* 2020 Dec 27; 3 (1): e97-e103. doi: 10.1016/j.asmr.2020.08.013. PMID: 33615253; PMCID: PMC7879166.
- [11] Bradko V, Stoll WT, Haruno LS, Rosenfeld SB, McKay SD. Two cases of combined patellar tendon avulsion from the tibia and patella. *SICOT J.* 2018; 4: 17. doi: 10.1051/sicotj/2018014. Epub 2018 May 23. PMID: 29792785; PMCID: PMC5967859.
- [12] Chautems R, Michel J, Barraud GE, Burdet A. Avulsion osseuse bifocale du tendon rotulien chez un adulte: à propos d'un cas [Bifocal avulsion of the patellar tendon in an adult: a case report]. *Rev Chir Orthop Reparatrice Appar Mot.* 2001 Jun; 87 (4): 388-91. French. PMID: 11431635.
- [13] Yoon JR, Kim TS, Kim HJ, Noh HK, Oh JK, Yoo JC. Simultaneous patellar tendon avulsion fracture from both patella and tibial tuberosity: a case report. *Knee Surg Sports Traumatol Arthrosc.* 2007 Mar; 15 (3): 225-7. doi: 10.1007/s00167-006-0168-9. Epub 2006 Aug 5. PMID: 16897070.
- [14] Stepanovich MT, Slakey JB. Combined Tibial Tubercle Avulsion Fracture and Patellar Avulsion Fracture: An Unusual Variant in an Adolescent Patient. *Am J Orthop (Belle Mead NJ).* 2016 Jan; 45 (1): E31-4. PMID: 26761925.
- [15] Kim KS, Suh DW, Park SE, Ji JH, Han YH, Kim JH. Suture anchor fixation of comminuted inferior pole patella fracture-novel technique: suture bridge anchor fixation technique. *Arch Orthop Trauma Surg.* 2020 Oct 30. doi: 10.1007/s00402-020-03671-5. Epub ahead of print. PMID: 33125547.