



CSF Leak Post COVID-19 Swab in a Patient with Preexisting Meningocele

Alzuwayed Abdullah^{1,2}, Algouhi Amani^{1,2,*}, Al Mahdi Mohammad^{1,2}, Alhedaithy Riyadh^{1,2}

¹Department of Otolaryngology and Head and Neck Surgery, King Abdulaziz Medical City, Riyadh, Saudi Arabia

²Ministry of National Guard Health Affairs, Riyadh, Saudi Arabia

Email address:

Dr.alzuwayed@gmail.com (A. Abdullah), amani.algouhi@gmail.com (A. Amani), Almahdimom@nnga.med.sa (Al M. Mohammad), Alhedaithy@hotmail.com (A. Riyadh)

*Corresponding author

To cite this article:

Alzuwayed Abdullah, Algouhi Amani, Al Mahdi Mohammad, Alhedaithy Riyadh. CSF Leak Post COVID-19 Swab in a Patient with Preexisting Meningocele. *Journal of Surgery*. Vol. 9, No. 4, 2021, pp. 176-179. doi: 10.11648/j.js.20210904.16

Received: May 30, 2021; **Accepted:** June 19, 2021; **Published:** June 28, 2021

Abstract: A 45-year-old female with medical background significant for bronchial asthma, hypothyroidism, polycystic kidney disease and obesity presented to the emergency department in December 2020 with one week history of severe headache, unilateral rhinorrhea and metallic taste. Her symptoms started two days after she had nasopharyngeal swab as post travel screening routine. Radiological investigations revealed features of increased intracranial pressure and a suspicious skull base defect for which patient undergone endoscopic transnasal skull base repair. Intraoperative findings were positive for CSF leak from a skull base defect and an incidental finding of Meningocele. Patient was seen after three weeks with no more CSF rhinorrhea, but was complaining of persistent mild headache, for which she was referred to neurology for further management. Conclusion: CSF leak is one of the rare, yet serious complications of nasopharyngeal swab especially in patients with previous skull base surgery, trauma, patients with pre-existing skull base defects or with elevated intracranial pressure. Meningocele found in this case report was presumed to be a predisposing factor for CSF leak post nasopharyngeal swab. Education about safe administration of nasopharyngeal swabs as well as understanding the nose anatomy is important to reduce the overall risk profile of nasopharyngeal sampling. Moreover, an alternative method of testing such as oropharyngeal specimen should be considered in populations with increased risk of CSF leak.

Keywords: Case Report, CSF Leak, COVID-19 Swab, Meningocele

1. Introduction

Coronavirus disease (COVID-19) has emerged as a global pandemic in March 2020. Community testing is one of the important pillars in COVID-19 detection and control. The US Centers for Disease Control and Prevention (CDC) has recommended 5 main methods for specimen collection in community screening including; nasopharyngeal, anterior nasal, and mid-turbinate swabs [1]. Bilateral deep nasal and oropharyngeal swabs are becoming standard of practice as an alternative upper airway testing methods. Other methods used for COVID-19 detection include saliva, sputum and blood cultures [2]. However, there are limited studies investigating complications associated with nasal swab. To our knowledge, only 5 case reports published in the English

literature describing cerebrospinal fluid (CSF) leak as a complication post nasal testing for COVID-19. Four of them had previous history of otolaryngology surgery. Herein, we report the 6th case in the English literature and the first case in Saudi Arabia describing CSF leak as a complication of COVID-19 diagnostic swab. This case was presented, diagnosed, managed and followed in King Abdulaziz Medical city in Riyadh.

2. Case Presentation

A 45-year-old obese female presented to the emergency department in December 2020 with severe headache and unilateral rhinorrhea with metallic taste for 1 week. Her symptoms started 2 days after she had nasopharyngeal swab as post travel screening routine. Nasal swab was conducted

by a registered nurse and it was negative for COVID-19. The patient's past medical history was significant for bronchial asthma, hypothyroidism and polycystic kidney disease. She denied any history of major skull base trauma, meningitis, recurrent sinusitis, or previous nasal or sinus surgery. She denied prior history of similar headache or other symptoms of raised intracranial pressure. Clinical exam revealed persistent right nostril rhinorrhea of clear nasal discharge that increases with valsalva maneuver and when bending forward (positive reservoir sign). Flexible nasopharyngoscopy revealed right-sided rhinorrhea. However, source of the fluid was not identified.

MRI revealed right sphenoidal sinus opacification with high signal on T2-weighted image, which was highly suspicious for CSF leak. Sinus CT showed a bony defect over the right upper part of the sphenoidal sinus Figure 1. Findings of bilateral dilated peri-optic sheet, enlarged empty sella, flattening of posterior ocular globe as well as mild intraocular protrusion of the optic nerve head were present, suggesting increased intracranial pressure. CT cisternogram was planned. However, patient refused the test.

Due to unavailability of beta-2-transferrin test in our institute, sample was sent to another facility. However, we could not retrieve the result back.

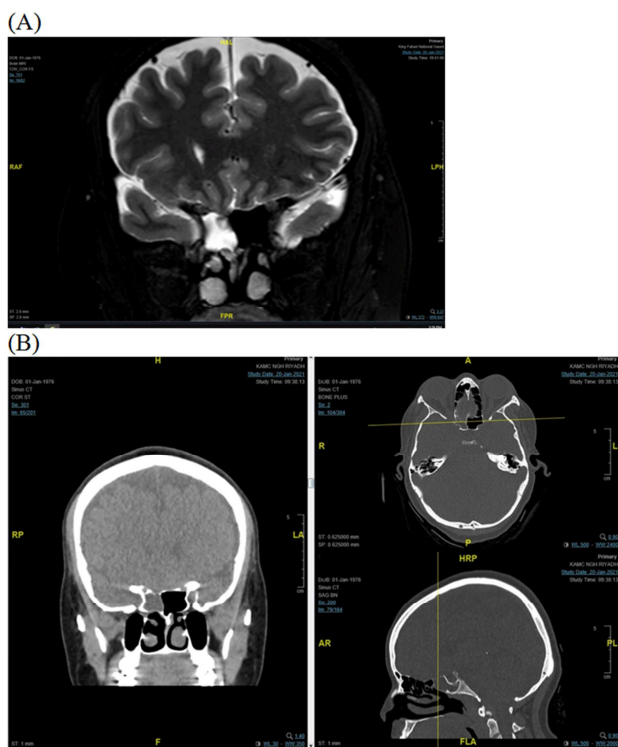


Figure 1. Brain MRI Showed hyperintensity in the right sphenoid sinus, (B) CT sinus showing right sphenoid opacification with bone defect at sphenoid roof

3. Management

Patient was referred to ophthalmology for formal visual testing and fundoscopy, which was unremarkable apart from mild optic disc swelling.

Patient was also evaluated by neurology team and was cleared from signs and symptoms related to increased intracranial pressure. Headache was attributed to CSF leak.

Patient was initially managed with observation and CSF leak protocol. Unfortunately, she developed chemical pneumonitis and was admitted under pulmonology for management and optimization prior surgery Figure 2.

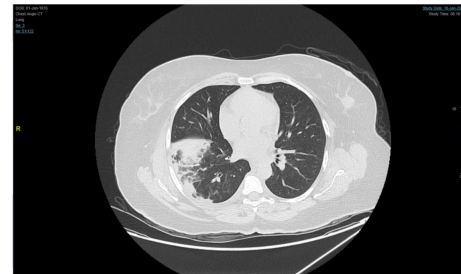


Figure 2. CT Angio showing right lung lobe opacification.

Patient underwent endoscopic transnasal skull base repair. Using 0-degree rigid endoscope, examination of the nasal cavity showed clear fluid dripping from sphenoid ostium. A small meningocele was found bulging from sphenoid roof. Fluorescein staining confirmed CSF leakage from meningocele site, which was cauterized using EVS cautery (Figure 3). The defect was less than 10 mm (Figure 4). and was repaired in overlay fashion using the right middle turbinate flap, sphenoid sinus was obliterated using fat graft harvested from paraumbilical area, eventually we ended our repair by adding fibrin sealant. Patient was kept post operatively for observation, and then was discharged after few days in stable condition.

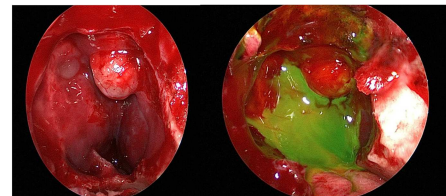


Figure 3. Intra-OP of right sphenoid sinus showing meningocele at the sphenoid roof in left picture, Fluorescein became green colour after it was applied at suspected CSF leak location which was confirming.

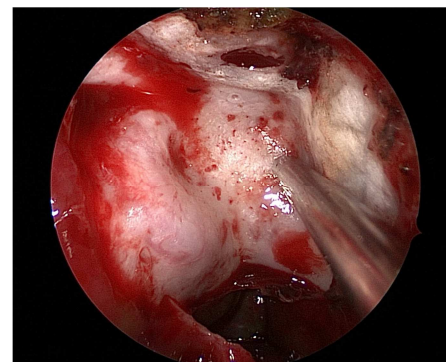


Figure 4. Skull base defect after cauterizing the meningocele and removing sphenoid mucosa.

4. Outcome and Follow up

Patient was seen after three weeks with no more CSF rhinorrhea, but was complaining of persistent mild headache, for which she was referred to neurology for further management

5. Discussion

COVID -19 outbreak was officially announced as a pandemic disease on March 11, 2020 [3]. In response, public health services around the world have worked enormously to slow COVID-19 transmission rates. Mass testing and trace programs have been utilized to achieve this goal and to identify and isolate cases rapidly. RT-PCR test is considered the gold standard diagnostic modality for COVID-19 detection and nasopharyngeal swab is considered the most sensitive technique for obtaining samples for RT-PCR testing [4]. Other acceptable anatomic sites for COVID-19 screening include anterior nares, mid-turbinate, oropharyngeal, tracheal and bronchoalveolar lavage specimens [5]. Nasopharyngeal swab is relatively a low risk screening method if performed correctly, with patient discomfort being the most significant concern. Immediate minimal epistaxis is the most reported side effect post nasopharyngeal swab [6]. Techniques and correct directions for safe nasal swabs collection has been described by multiple health organizations [7]. However, improperly directed nasal swabs can cause mucosal injury as well potential damage to the skull base as highlighted in our case report.

Iatrogenic CSF rhinorrhea most commonly occur after nasal surgeries with cribriform plate damage being the most attributed etiology [8]. It results from disturbing the barriers between nasal cavity and paranasal sinuses and the subarachnoid spaces. CSF rhinorrhea is confirmed by biochemical detection of beta-2 transferrin from nasal discharge [9]. Contrast-enhanced MR Cisternography is considered the gold standard for the diagnosing CSF leak [6].

Persistent CSF rhinorrhea is unlikely to close spontaneously and as time passes, the risk of meningitis increases significantly. In fact, the risk of meningitis before surgical intervention can reach up to 30.6% [10]. Therefore, urgent attention and management of CSF leak is mandatory with endoscopic skull base repair and VP shunt placement being the most commonly used treatment modalities [11].

Congenital defects at the fusion plane of ossified cartilaginous precursors of the sphenoidal sinus are commonly occurring during development. Those defects act as weak points at the skull base, which may lead to meningocele and encephalocele protrusion into the sphenoid sinus. Moreover, idiopathic intracranial hypertension is a well recognized risk factor for meningocele formation [12].

In this case report, it is believed that our patient had asymptomatic elevated intracranial pressure with pre-existing skull base defect and the nasal swab disrupted the mucosa surrounding the meningocele causing the CSF leak.

6. Conclusion

Coronavirus has emerged as a global pandemic disease in March 2020. Community testing is one of the important pillars in COVID-19 detection and control. CDC has recommended 5 main methods for specimen collection of which deep nasal and oropharyngeal swabs are becoming the standard of practice. However, there are limited studies investigating complications associated with nasal swab. To our knowledge, only 5 case reports was published in the English literature describing cerebrospinal fluid (CSF) leak as a complication post nasal testing for COVID-19. Four of them had previous history of otolaryngology surgery. Herein, we report the 6th case in the English literature and the first case in Saudi Arabia describing CSF leak as a complication of COVID-19 diagnostic swab. This case was presented, diagnosed, managed and followed in King Abdulaziz Medical city in Riyadh.

A 45-year-old female with medical background significant for bronchial asthma, hypothyroidism, polycystic kidney disease and obesity presented to the emergency department in December 2020 with one week history of severe headache, unilateral rhinorrhea and metallic taste. Her symptoms started two days after she had nasopharyngeal swab as post travel screening routine. Radiological investigations revealed features of increased intracranial pressure and a suspicious skull base defect for which patient undergone endoscopic transnasal skull base repair. Intraoperative findings were positive for CSF leak from a skull base defect and an incidental finding of Meningiocele. Patient was seen after three weeks with no more CSF rhinorrhea, but was complaining of persistent mild headache, for which she was referred to neurology for further management.

Despite nasopharyngeal swab is considered a safe procedure, adverse events may happen especially if was obtained by non-experienced hands. This case report highlights CSF leak as one of the rare, yet serious complications of nasopharyngeal swab. Education about safe administration of nasopharyngeal swabs as well as understanding the nose anatomy is important to reduce the overall risk profile of nasopharyngeal sampling. Moreover, an alternative method of testing such as oropharyngeal specimen should be considered in populations with increased risk of CSF leak. This includes patients with previous skull base surgery, trauma, patients with pre-existing skull base defects and with elevated intracranial pressure.

Conflicts of Interests

All the authors do not have any possible conflicts of interest.

Informed Consent

Written informed consent was obtained from the patient for publication of this case report and accompanying images.

A copy of the written consent is available for review by the Editor-in-Chief of this journal on request

References

- [1] Interim Guidelines for Collecting, Handling, and Testing Clinical Specimens for COVID-19. Published 2020. <https://www.cdc.gov/coronavirus/2019-ncov/lab/guidelines-clinical-specimens.html>. Accessed July 29, 2020.
- [2] Department of health 2020, accessed 2 December 2020, <https://www.health.gov.au/resources/publications/phln-guidance-on-laboratory-testing-for-sars-cov-2-the-virus-that-causes-covid-19>.
- [3] Cucinotta D, Vanelli M. WHO Declares COVID-19 a Pandemic. *Acta Biomed.* 2020 Mar 19; 91 (1): 157-160. doi: 10.23750/abm.v91i1.9397.
- [4] Hanson KE, Caliendo AM, Arias CA, Hayden MK, Englund JA, Lee MJ, Loeb M, Patel R, El Alayli A, Altayar O, Patel P, Falck-Ytter Y, Lavergne V, Morgan RL, Murad MH, Sultan S, Bhimraj A, Mustafa RA. Infectious Diseases Society of America Guidelines on the Diagnosis of COVID-19: Molecular Diagnostic Testing. *Infectious Diseases Society of America* 2020; Version 2.0.0.
- [5] Centers for Disease Control and Prevention. Interim Guidelines for Collecting, Handling, and Testing Clinical Specimens for COVID-19. Feb. 26, 2021.
- [6] Alberola-Amores FJ, Valdeolivas-Urbelz E, Torregrosa-Ortiz M, Álvarez-Sauco M, Alom-Poveda J. Meningitis due to cerebrospinal fluid leak after nasal swab testing for COVID-19. *European Journal of Neurology.* 2021 Jan. DOI: 10.1111/ene.14736.
- [7] Rajah, J., & Lee, J. (2021). CSF rhinorrhoea post COVID-19 swab: A case report and review of literature. *Journal of Clinical Neuroscience*, 86, 6–9. <https://doi.org/10.1016/j.jocn.2021.01.003>.
- [8] Daele JJM, Goffart Y, Machiels S. Traumatic, iatrogenic, and spontaneous cerebrospinal fluid (CSF) leak: endoscopic repair. *B-ENT* 2011; 7 (suppl 17): 47–60.
- [9] De Divitiis E, Laws Jr E. The Transnasal versus Transcranial Approach to Lesions of the Anterior Skull Base. *World Neurosurg.* 2013; 80: 728-731.
- [10] Eljamel MS, Pidgeon CN, Toland J. MRI cisternography and the localization of CSF fistulae. *Br J Neurosurg.* 1994; 8: 433-7.
- [11] Samuel K, White TG, Black K, Rebeiz T, Weintraub D. Cerebrospinal fluid leak as a complication of intranasal COVID-19 swabbing following remote transsphenoidal surgery. *Open J Clin Med Case Rep.* 2020; 1694.
- [12] Bialer OY, Rueda MP, Bruce BB, Newman NJ, Biousse V, Saindane AM. Meningoceles in idiopathic intracranial hypertension. *AJR AmJ Roentgenol.* 2014; 202 (3): 608-613. doi: 10.2214/AJR.13.10874\.