

# Reconstruction of Type V Hepatic Arterial in the Adult and Pediatric Liver Transplant Recipient

**John Abraham Geha<sup>1</sup>, Matthew Benjamin Goss<sup>2</sup>, Joseph Daniel Geha<sup>1</sup>, Christine Ann O'Mahony<sup>1</sup>, Nhu Thao Nguyen Galvan<sup>1</sup>, Abbas Rana<sup>1</sup>, Ronald Timothy Cotton<sup>1</sup>, Michael Louis Kueht<sup>1</sup>, John Alan Goss<sup>1,\*</sup>**

<sup>1</sup>Division of Abdominal Transplantation, Michael E. DeBakey Department of Surgery, Baylor College of Medicine, Houston, USA

<sup>2</sup>John P. and Katherine G. McGovern Medical School, University of Texas Health Science Center at Houston, Houston, USA

## Email address:

John.geha@yahoo.com (J. A. Geha), matthew.b.goss@uth.tmc.edu (M. B. Goss), gehajoe@gmail.com (J. D. Geha), comahony@bcm.edu (C. A. O'Mahony), thao.galvan@bcm.edu (N. T. N. Galvan), abbas.rana@bcm.edu (A. Rana), ronaldc@bcm.edu (R. T. Cotton), mlkueht@utmb.edu (M. L. Kueht), jgoss@bcm.edu (J. A. Goss)

\*Corresponding author

## To cite this article:

John Abraham Geha, Matthew Benjamin Goss, Joseph Daniel Geha, Christine Ann O'Mahony, Nhu Thao Nguyen Galvan, Abbas Rana, Ronald Timothy Cotton, Michael Louis Kueht, John Alan Goss. Reconstruction of Type V Hepatic Arterial in the Adult and Pediatric Liver Transplant Recipient. *Journal of Surgery*: Vol. 8, No. 1, 2020, pp. 1-4. doi: 10.11648/j.js.20200801.11

**Received:** November 24, 2019; **Accepted:** January 3, 2020; **Published:** January 13, 2020

**Abstract:** The replaced common hepatic artery (RCHA) is an uncommon arterial anomaly that, when present, makes hepatic arterial reconstruction during liver transplantation technically challenging. At our institution, the reconstruction of the recipient RCHA consists of 2 techniques that include either an infrarenal donor iliac artery aortic conduit or a direct donor celiac trunk anastomosis to the proximal RCHA. Our experience demonstrates that the direct anastomosis to the RCHA provides a reliable source of arterial inflow, allows preservation of the recipient arterial anatomy, and minimizes the dissection required to create an infrarenal aortic conduit. Between September 1998 and April 2019, we performed 1782 liver transplants (1230 adults, >18 years; 552 pediatric, <18 years). There were 36 (2.92%) adult and 20 (3.07%) pediatric liver transplant recipients that possessed a RCHA. Allograft and patient survivals were 94.70% and 94.10%, in both the infrarenal conduit and direct Type-V anastomosis cohorts at 1 year, respectively. To date, hepatic artery thrombosis (HAT) has not occurred in the 2 cohorts of pediatric transplant recipients. In conclusion, the direct donor celiac trunk to RCHA anastomosis is a safe and effective way to perform arterial reconstruction with low hepatic artery thrombosis and biliary complication rates.

**Keywords:** Liver Transplantation, Arterial Reconstruction, Arterial Anomaly

## 1. Introduction

The replaced common hepatic artery (RCHA) is an uncommon arterial anomaly that most commonly arises from the superior mesenteric artery (SMA). Classified by Hiatt et al. [1] as type V, its incidence is reported to be from 9-15% of the population [1, 2]. While unusual, this arterial variation when present may make the hepatic arterial reconstruction during liver transplantation technically challenging [3, 4]. Knowledge of the hepatic arterial anatomy is paramount and proper identification prior to or during liver transplantation is essential in establishing arterial blood flow to the liver allograft [5, 6]. Currently, there is limited literature describing

the most effective method to approach the recipient RCHA during liver transplantation. Potential difficulties encountered include size discrepancies, insufficient allograft inflow, disruption to normal vascular anatomy, and thrombus formation resulting in liver allograft failure [2, 7-9]. Previous described techniques include the branch patch and infrarenal aortic conduit [10-13]. At our institution, the reconstruction of the recipient RCHA has evolved and now consists of 2 techniques that include either an infrarenal donor iliac artery aortic conduit or a direct donor celiac trunk anastomosis to the proximal RCHA (Figure 1). Our experience demonstrates that the direct anastomosis to the RCHA provides a reliable source of arterial inflow, allows preservation of the recipient arterial

anatomy, and minimizes the dissection required to create an infrarenal aortic conduit. In addition, the direct RCHA anastomosis allows a sized matched arterial anastomosis as the donor celiac trunk and recipient RCHA are usually similar in diameter and eliminates the extra arterial anastomosis required in the creation of the aortic conduit.

## 2. Materials and Methods

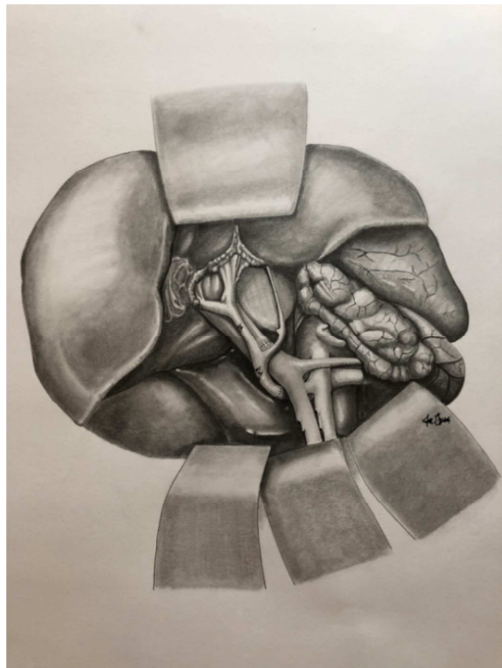
Between September 1998 and April 2019, we performed 1782 liver transplants (1230 adults, >18 years; 552 pediatric, <18 years). There were 36 (2.92%) adult and 20 (3.07%) pediatric liver transplant recipients that possessed a RCHA. In the 36 adult recipients with RCHA, 19 patients underwent hepatic arterial reconstruction utilizing an infrarenal donor iliac artery aortic conduit and 17 patients underwent a direct donor celiac trunk to RCHA anastomosis (Figure 1). Of the 17 pediatric recipients with RCHA, hepatic artery reconstruction was achieved in 9 patients utilizing an infrarenal donor iliac artery aortic conduit, whereas, 8 patients had their hepatic artery reconstruction completed via a direct donor celiac trunk to recipient RCHA anastomosis (Figure 2). There has been a definite evolution in our transplant program toward the use of the direct RCHA anastomosis in both the adult and pediatric cohorts, and since 2013 we have categorically attempted to use the RCHA if feasible and have resorted to the aortic conduit only after finding that the RCHA was not a suitable source of inflow for the hepatic arterial reconstruction. In the recipients that underwent hepatic arterial reconstruction utilizing the aortic conduit it was constructed in the infrarenal position and in the usual previously published manner [14]. As demonstrated in Figure 1, the 17 adult recipients and 8 pediatric recipients that underwent the direct donor celiac axis to RCHA end-to-end anastomosis were all performed utilizing interrupted Prolene sutures. To perform this anastomosis, we have discovered a few caveats. To prepare the RCHA for the anastomosis the recipient bile duct, duodenum and associated pancreas all must be rolled anteriorly and inferiorly to gain access to the RCHA. The RCHA then needs to be dissected free of all of the surrounding soft and pancreatic tissue and the small arterial branches encountered need to be ligated and divided to create adequate length on the RCHA. We feel that this dissection needs to be carried deep enough so that the proximal RCHA may be used for the anastomosis. We have found that that inflow in the RCHA at this proximal level is brisk and is sufficient to support the donor liver allograft. As shown in Figures 1 and 2 to reach this proximal RCHA requires being posterior to the portal vein from a depth point of view. At this point a small or micro Statinsky clamp can be used to occlude the RCHA while performing the interrupted 7.0 or 8.0 Prolene anastomosis. When preparing to perform the hepatic arterial anastomosis the alignment of the donor celiac trunk is important and as demonstrated in Figures 1 and 2 the splenic artery needs to be oriented so that it is almost pointing directly anteriorly to allow a gentle anterior-lateral course to the donor liver allograft and avoid unwanted twisting of the donor arterial

circulation. To date the donor celiac trunk and hepatic arterial circulation has been long enough so we have not had to worry about tension on the arterial anastomosis. If this occurs, we would propose adding a short donor iliac arterial interposition graft as previously published [15]. If length is still a problem, we would proceed with the performance of an infrarenal donor iliac artery aortic conduit. Retrospectively, the incidence of hepatic artery thrombosis (HAT), liver allograft survival and patient survival were assessed. Posttransplant HAT was defined as sonographic Doppler evidence of hepatic artery occlusion occurring any time during the patient's posttransplant course. Survival time was calculated as time of transplant to last follow-up with the transplant recipient. A time-to-event analysis was achieved with Kaplan-Meier survival curves. It should be pointed out that the direct anastomosis of the donor celiac trunk to the Type-V recipient hepatic artery does not interfere with a choledochocholedochostomy or a Roux-en-Y hepaticojejunostomy biliary reconstruction as the Type-V hepatic artery is posterior and inferior to the biliary reconstruction.

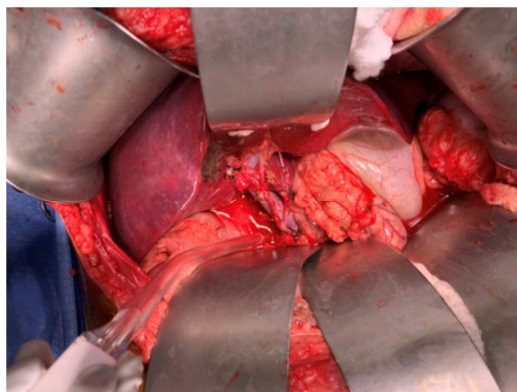
Retrospectively, of the 36 adult and 17 pediatric recipients identified who underwent liver transplantation with Type-V hepatic arterial anatomy, 19 of the 36 adult recipients (52.80%) underwent hepatic arterial reconstruction utilizing an infrarenal donor iliac artery aortic conduit while 17 of the adults (47.20%) underwent arterial reconstruction via a direct anastomosis of the donor celiac trunk to the Type-V native hepatic artery (Figure 1). None of these recipients in either the infrarenal conduit or direct Type-V arterial anastomosis cohort developed HAT. Allograft and patient survivals were 94.70% and 94.10%, in both the infrarenal conduit and direct Type-V anastomosis cohorts at 1 year, respectively. Both of these adult patients were lost due to sepsis and multisystem organ failure without hepatic arterial difficulties. In the pediatric cohort of 17 patients, 9 (52.90%) underwent hepatic arterial reconstruction via an infrarenal donor iliac artery aortic conduit while 8 (47.10%) had hepatic arterial reconstruction via the direct anastomosis of the donor celiac trunk to the Type-V recipient hepatic artery (Figure 2). To date, HAT has not occurred in these 2 cohorts of pediatric transplant recipients. One pediatric patient in the infrarenal aortic conduit cohort was lost secondary to posttransplant lymphoproliferative disorder (PTLD) involving the central nervous system [16]. All 8 of the patients who underwent hepatic artery reconstruction via a direct arterial anastomosis of the donor celiac trunk to the recipient Type-V hepatic artery are currently alive and well.

Biliary reconstruction was performed via choledochocholedochostomy (CDCD) in 17 of the 19 adult patients undergoing hepatic arterial reconstruction with an infrarenal aortic conduit and 16 of the 17 adult patients with a direct RCHA arterial anastomosis. This leaves 3 adult patients with Roux-en-Y hepaticojejunostomies (2 patients in the infrarenal aortic conduit cohort and 1 in the direct anastomosis cohort). The combined incidence of biliary stricture in the infrarenal aortic conduit and direct RCHA anastomosis

cohorts was 10.50% and 11.70%, respectively. In the pediatric patients 6 of the 9 patients with an infrarenal aortic conduit had biliary reconstruction via Roux-en-Y hepaticojejunostomy while 3 patients had a CDCD. Six of the 8 pediatric recipients that underwent arterial reconstruction via the direct donor celiac to RCHA underwent biliary reconstruction via Roux-en-Y hepaticojejunostomy. Five of the pediatric recipients underwent biliary reconstruction via CDCD, 3 with aortic conduits and 2 with a direct RCHA anastomosis. The incidence of biliary stricture in these two pediatric cohorts was 11.10% and 0.00% for the infrarenal aortic conduit and direct RCHA anastomosis cohorts, respectively.



**Figure 1.** Illustration depicting the type V arterial reconstruction utilizing the recipient's proximal hepatic artery with anastomosis to the donor celiac axis with interrupted Prolene sutures. The donor celiac axis is rotated approximately 75° with ligated donor splenic artery facing inferiorly to avoid twisting/kinking. The reconstructed arteries travel posterior to anterolateral to the portal vein.



**Figure 2.** Intra operative photograph showing type V arterial reconstruction with arterial supply passing from posterior to anterolateral to the portal vein. Following ligation of the donor splenic and left gastric arteries, the donor celiac trunk is anastomosed to the recipient's RCHA.

### 3. Discussion

RCHA originating from the SMA is a relatively rare hepatic artery anatomy that can create challenges when performing orthotopic liver transplantation. To date, there is a paucity of literature published regarding the hepatic arterial reconstruction in these patients. In this letter, we propose a novel technique that allows a direct donor celiac trunk to the RCHA and avoids additional dissection and suture line necessary to create an infrarenal donor iliac artery aortic conduit. Our results demonstrate low and acceptable HAT and biliary complication rates. Therefore, despite the relatively small number of cases and the dissection required to prepare the RCHA for anastomosis, we preferentially attempt the direct donor celiac trunk to RCHA anastomosis in this patient population.

### References

- [1] Johnathan Hiatt, Joubin Gabbay, Ronald W. Busuttil. Surgical Anatomy of the Hepatic Arteries in 1000 Cases. *Annals of Surgery*. July 1994; 220 (1): 50-52.
- [2] Astrid Herrero, Regis Souche, Emmanuel Joly, Gildas Boisset, Hussein Habibeh, Hassan Bouyabrine, Fabrizio Panaro Jose Ursic-Bedoya, Samir Jaber, Boris Guiu, Georges Philippe Pageaux, Francis Navarro. Early Hepatic Artery Thrombosis After Liver Transplantation: What is the Impact of the Arterial Reconstruction Type? *World Journal of Surgery*. August 2017; 41 (8): 2101-2110.
- [3] Joel R. Schroering, Chandrashekhar A. Kubal, Jonathan A. Fridell, Taylor J. Hathaway, Ross C. Robinson, Richard S. Mangus. Impact of Variant Donor Hepatic Arterial Anatomy on Clinical Graft Outcomes in Liver Transplantation. *Liver Transplantation*. October 2018; 24 (10) 1481-1484.
- [4] Taizo Hibi, Seigo Nishida, David M. Levi, Daisuke Sugiyama, Kyota Fukazawa, Akin Tekin, Ji Fan, Gennaro Delvaggi, Phillip Ruiz, Andreas G. Tzakis. Long-Term Deleterious Effects of Aortohepatic Conduits in Primary Liver Transplantation: Proceed With Caution. *Liver Transplantation*. 2013 August; 19 (8): 916-925.
- [5] Salvatore, Gruttadauria, Carlo Scotti Foglieni, Cataldo Doria, Angelo Luca, Augusto Lauro, Ignazio R Marino. The Hepatic Artery in Liver Transplantation and Surgery: Vascular Anomalies in 701 Cases. *Clinical Transplantation*. October 2001; 15 (5): 359-363.
- [6] Paolo Muiasan, Mohamed Rela, Franco Nodari, Hector Vilca Melendez, Vassilis Smyrniotis, Vassilis Vougas, Nigel Heaton. Use of Infrarenal Conduits for Arterial Revascularization in Orthotopic Liver Transplantation. *Liver Transplantation and Surgery*. May 1998; 4 (3): 232-235.
- [7] Ioannis Fouzas, Vasilios Papanikolaou, Georgios Katsanos, Nikolaos Antoniadis, Nikolaos Salveridis, Katerina Karakasi, Soterios Vasileiadou, Aegues Fouza, Eleni Mouloudi, Gakis Imvrios, Caedmon Papanikolaou. Hepatic Artery Anatomic Variations and Reconstruction in Liver Grafts Procured in Greece: The Effect on Hepatic Artery Thrombosis. *Transplantation Proceedings*. March 2019; 51 (2): 416-420.

- [8] Ailin C. Rogers, Sandhya Chalasani, Anthony G. Ryan, Keith Simon Cross, Morgan P. McMonagle. The Twin Evils of Concomitant Rare Pathology with Variant Anatomy: Superior Mesenteric Artery Aneurysm and a Replaced Right Hepatic Artery. *Annals of Vascular Surgery*. January 2017; 38: 318.e1-318.e6.
- [9] Marcio F. Chedid, Tomaz J. M. Grezzana-Filho, Aljamir D. Chedid, Luiz Pedro P. Hendges, Ian Leipnitz, Mario R. Alvares-da-Silva, Ariane N. Backes, Matheus J. Reis, Cleber Dario P. Kruel, Cleber R. P. Kruel. Liver Transplantation Utilizing Mixed Biologic and Synthetic Arterial Conduits. *Case Reports in Surgery*. 2016: 9245079.
- [10] Caitlin W. Hicks, Richard. A. Burkhart, Matthew J. Weiss, Christopher L. Wolfgang, Andrew M. Cameron, Timothy M. Pawlik. Management of Type 9 Hepatic Arterial Anatomy at the time of Pancreaticoduodenectomy: Considerations for Preservation and Reconstruction of a Completely Replaced Common Hepatic Artery. *Journal of Gastrointestinal Surgery*. July 2016; 20 (7): 1400-1404.
- [11] Osamu Aramaki, Yasuhiko Sugawara, Norihiro Kokudo, Tadatoshi Takayama, Masatoshi Makuuchi. Branch Patch Reconstruction in Living Donor Liver Transplantation: Arterialization of Grafts with Replaced Type Arteries. *Transplantation*. December 2006; 82 (11): 1541-1543.
- [12] Massimo Del Gaudio, Gian Luca Grazi, Giorgio Ercolani, Matteo Ravaioli, Giovanni Varotti, Matteo Cescon, Gaetano Vetrone, Giovanni Ramacciato, Antonio Daniele Pinna. Outcome of Hepatic Artery Reconstruction in Liver Transplantation with an Iliac Arterial Interposition Graft. *Clinical Transplantation*. 2005 May; 19 (3): 399-405.
- [13] Yi Ma, Qiang Li, Zhi-Ming Ye, Xiao-Feng Zhu, Xiao-Shun He. Use of Arterial Conduit for Arterial Revascularization During Liver and Multivisceral Transplantation. *Chinese Medical Journal*. 2011 October; 124 (19): 2986-2989.
- [14] Dong-Hwan Jung, Cheon-Soo Park, Tae-Yong Ha, Gi-Won Song, Gil-Chun Park, Yong-Pil Cho, Sung-Gyu Lee. Placement of an Aortohepatic Conduit as an Alternative to Standard Arterial Anastomosis in Liver Transplantation. *Annals of Transplantation*, 2018; 23: 61-65.
- [15] John A. Geha, N. Thao Galvan, Michael Kueht, Dor Yoeli, Joe D. Geha, Abbas Rana, Ronald T. Cotton, Christine A. O'Mahony, John A. Goss. Celiac Axis Extension Grafts in Orthotopic Liver Transplantation. *Liver Transplantation*. August 2018; 24: 1138-1141.
- [16] Philip K. Ng, Abbas Rana, Ramya P. Masand, Kalpesh Patel, Andras A. Heczey, John A. Goss, Ryan W. Himes. Fatal Central Nervous System Post-Transplant Lymphoproliferative Disease in a Patient Who Underwent Liver Transplantation for Hepatoblastoma. *Journal of Pediatric Gastroenterology and Nutrition*. January 2018; 66 (1): e21-e23.