

**Case Report**

# A Case Report on Diaphragmatic Rupture, in the Visceral Surgery of Hospital of Conakry, Guinea

**Abdoulaye Korse Balde<sup>1</sup>, Oumar Taibata Balde<sup>1</sup>, Fode Lansana Camara<sup>1</sup>, Soriba Naby Camara<sup>2</sup>, Hamidou Sylla<sup>1</sup>, Amadou Dioulde Diallo<sup>1</sup>, Aissatou Taran Diallo<sup>3</sup>, Alpha Madiou Barry<sup>1</sup>, Ahmed Boubacar Barry<sup>1</sup>, Sneha Ballah<sup>4</sup>**

<sup>1</sup>Department of Visceral Surgery, University Gamal Abdel Nasser of Conakry, Conakry, Guinea

<sup>2</sup>Department of Pancretic Surgery, Huazhong University of Science and Technology, Wuhan, China

<sup>3</sup>Department of General Surgery, University Gamal Abdel Nasser of Conakry, Conakry, Guinea

<sup>4</sup>Department of General Surgery, University of Mauritius, Mauritius, Mauritius

**Email address:**

[baldakor@gmail.com](mailto:baldakor@gmail.com) (A. K. Balde), [taibataoumar@yahoo.fr](mailto:taibataoumar@yahoo.fr) (O. T. Balde), [csoribanaby@yahoo.com](mailto:csoribanaby@yahoo.com) (S. N. Camara)

**To cite this article:**

Abdoulaye Korse Balde, Oumar Taibata Balde, Fode Lansana Camara, Soriba Naby Camara, Hamidou Sylla, Amadou Dioulde Diallo, Aissatou Taran Diallo, Alpha Madiou Barry, Ahmed Boubacar Barry, Sneha Ballah. A Case Report on Diaphragmatic Rupture, in the Visceral Surgery of Hospital of Conakry, Guinea. *Journal of Surgery*. Vol. 4, No. 3, 2016, pp. 76-80. doi: 10.11648/j.js.20160403.13

**Received:** June 5, 2016; **Accepted:** June 14, 2016; **Published:** July 18, 2016

---

**Abstract:** The aim of this case report is to share our experience in the management of this rare case of traumatic diaphragmatic rupture in the visceral surgery department of the Hospital of Conakry. Traumatic diaphragmatic rupture is an unfamiliar diagnosis to make and exceptionally seen in some cases of high velocity injuries which involve the abdomen. The high energy from blunt trauma transmitted across the abdomen gives rise to an excessively high pressure in the abdominal cavity which causes shearing of the diaphragmatic muscle. It is indeed considered as a surgical emergency as impaired diaphragmatic movement has a big impact on ventilation and oxygenation of blood. The delay in making appropriate diagnosis due to the lack of overt clinical signs relating to this type of injury accounts for the high mortality rates reaching 31%. We are reporting on a case concerning a 28-year old male patient who was admitted at the department of visceral surgery at the National Hospital of Donka, Conakry, Guinea, for emergency evaluation and treatment of a left sided traumatic diaphragmatic rupture associated with eventration of viscera into the thoracic cavity and contusion of the ascending colon. The mechanism of rupture was determined as a force vector directed frontally and was transmitted across the diaphragmatic wall. A clinical diagnosis was made and confirmed by radiological imaging preoperatively. Prompt surgical intervention was provided within the 1<sup>st</sup> 24 hours from the time of admission. No complications had been encountered during the post-operative recovery period. The best way to evaluate traumatic diaphragmatic rupture in a patient is through a well-devised systematic approach. It is not advised to perform lengthy imaging tests in a hemodynamically unstable patient and thus, compromising the success of the surgical outcome.

**Keywords:** Diaphragm, Trauma, Rupture, Injury, Surgery

---

## 1. Introduction

The diaphragm is the major muscle of inspiration, responsible for approximately two-thirds of quiet breathing in healthy humans. In a healthy adult with a vital capacity of 4.5 litres, some 3 litres is accounted for by diaphragmatic excursion. [1] The incidence of traumatic diaphragmatic rupture secondary to blunt trauma, most commonly motor

vehicle collisions, ranges from 0.8-8% in patients who had undergone thoracotomy or laparotomy for repair of visceral injuries [2, 3]. Diaphragmatic rupture is a potentially life threatening clinical condition [4, 19] both due to the lack of apparent clinical signs and diagnostic delays. Associated injury to abdominal organs is common during blunt trauma and may obscure the presentation of a concomitant diaphragmatic rupture. The location of the injury is unclear

and it is difficult to discern the extent of injuries, which largely determines the outcome [5, 6, 22]. An overall mortality of 31% reflects the severity of the trauma [5].

Occupants who sustain lateral impact forces in impact motor vehicle collisions are more susceptible to rupture of the diaphragm than with frontally directed forces. With lateral collisions, left sided impacts are more likely to produce a diaphragmatic rupture than the right side. This is due to the cushioning effect of the liver on the right hemidiaphragm which makes it more resistant to shearing forces emerging from lateral collisions. [7, 8, 9, 10]. The mechanism which compels physicians to suspect possibility of diaphragmatic rupture is based on the side of the diaphragm involved and the direction of the force of impact. [7]

Since diaphragmatic rupture is hard to discern among other injuries, the degree of success depends on the ability of the physician in recognizing the clinical situation early and providing timely surgical intervention. [11]

When there is suspected herniation of intra-abdominal organs, the initial diagnosis is made with radiological imaging of the diaphragm. Sensitivity between 27 and 73% has been described. Multiple detectors computed tomography (MDCT) has become the diagnosis method of choice in cases of suspected traumatic diaphragmatic hernia suspicion. Echo graphic examination of patients with non-penetrating trauma (echo-fast) allows for lung bases analysis and the suggestion of a diaphragmatic rupture, observing the absence of diaphragmatic excursion (in patients without assisted respiration), loss of continuity or protrusion of the viscera to the pleural space. [12] However, right-sided injuries of the diaphragm may not be as evident and are misinterpreted as thoracic trauma. In this setting, a high index of suspicion coupled with selective use of radionuclide scanning, ultrasound, and CT or magnetic resonance imaging is necessary for early detection of this uncommon injury. [13]

Surgical management is based on the side of the diaphragm involved and depending on the accompanying organ injuries. It may require an approach through the chest, or abdomen or thoracoabdomen. In the acute phase, the left hemi diaphragm is best accessed through the abdomen, or may be even be initially through a chest incision followed laparotomy when necessary. Acute right-sided injuries and chronic injuries are accessed from the chest. [11]

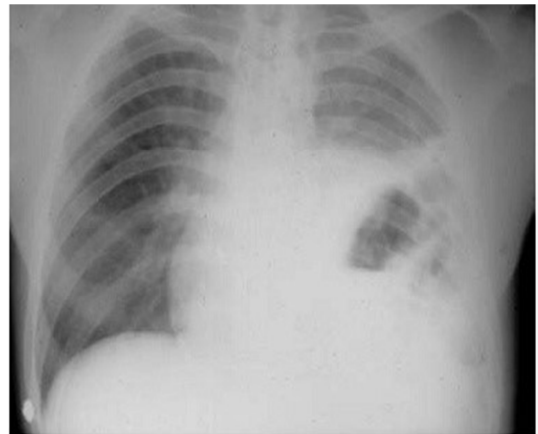
This case report describes acute diaphragmatic rupture associated with an injury of the ascending colon. It lays stress on the need to recognize the mechanisms involved in its pathophysiology as well as the diagnostic and therapeutic modalities.

## 2. Case Presentation

A 28 year-old male patient without any significant antecedent medical history, victim in a car collision with a tree, was admitted to the emergency department in Conakry Hospital. He initially complained of diffuse thoraco-abdominal pain, dyspnea and nausea. 12hours after admission, he was transferred to the visceral surgical unit and

a rapid physical examination was performed. The thorax was found to be asymmetrical in shape, with bowel tympanic sounds heard on the side of the left hemi thorax. The patient displayed abdominal guarding on palpation of the right side of the abdominal wall. The pouch of Douglas was full but painless to palpation. The rest of the physical examination proved to be unremarkable.

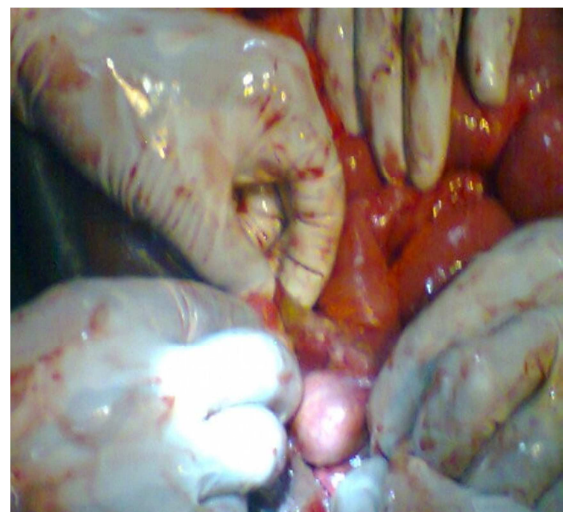Radiological imaging revealed upward displacement of the greater curvature of the stomach and 1/3 of the transverse colon into the thoracic cavity. Diagnosis of traumatic diaphragmatic rupture was made and patient was rapidly prepared for surgery. Other necessary pre operative tests such as coagulation tests, complete blood count and blood glucose were simultaneously obtained.



**Figure 1.** Xray image of the chest showing an upward displacement of the greater curvature of the stomach and 1/3 of the transverse colon, and elevation of the left hemi diaphragm.

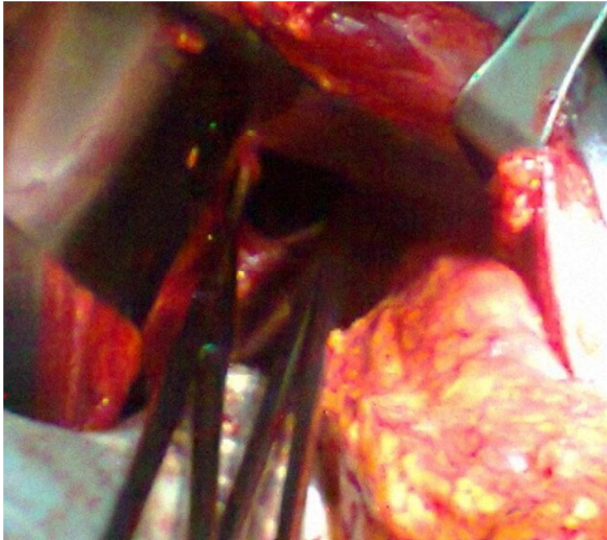
## 3. Surgical Management

A laparotomy was performed, with a midline horizontal incision made under the level of the umbilicus. Exploration revealed that 1/3 of the transverse colon and greater curvature of the stomach had herniated through a 10cm diaphragm laceration into the chest.

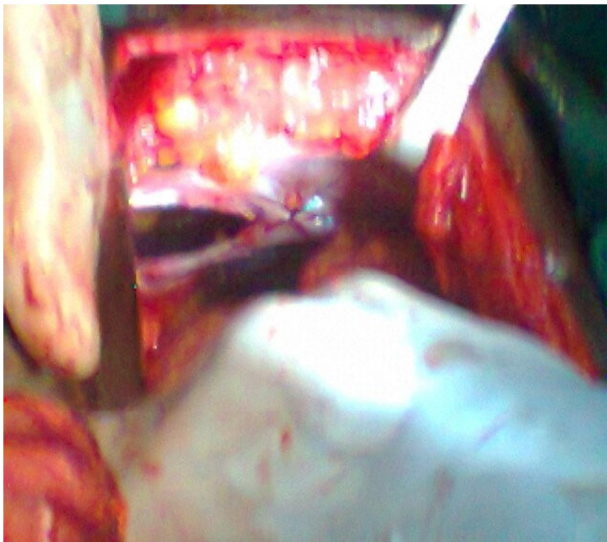


**Figure 2.** Contusion of ascending colon of about 2cm in length.

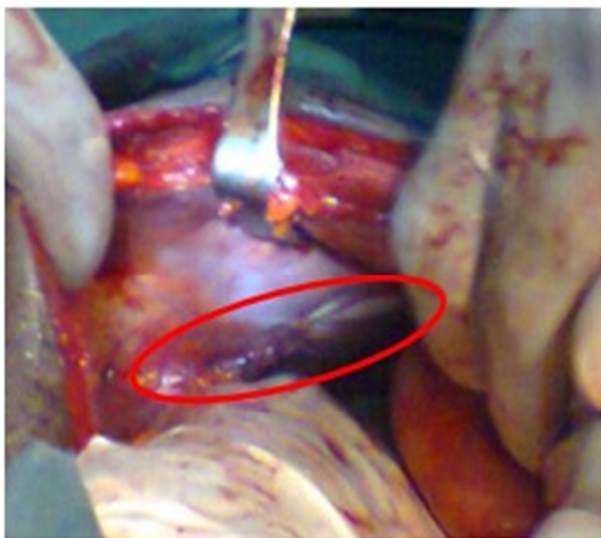




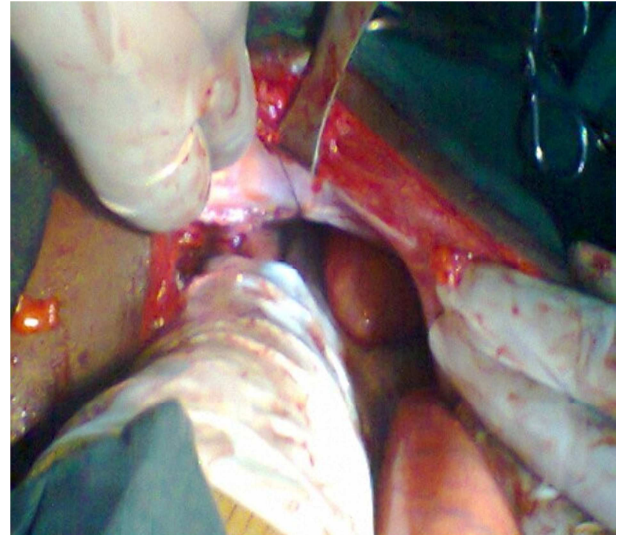
**Figure 3.** Diaphragmatic tear over a length of 10cm with herniation of the Transverse colon and greater Curvature of the stomach.



**Figure 4.** Suturing the breach with non Absorbable sutures.



**Figure 5.** Diaphragmatic laceration closed up.



**Figure 6.** Hemostatic control.

A contusion measuring 2cm in length was also located on the ascending colon. Surgical intervention comprised of restoring diaphragmatic continuity with a large monofilament non-absorbable suture, placed as horizontal mattress stitches and returning the viscera into the abdominal cavity. The abdominal cavity was copiously lavaged before closing up. The patient had an uneventful recovery.

#### 4. Discussion

In general, diaphragmatic rupture arises when the intra-abdominal pressure is exceedingly elevated in traumatic events such as high speed motor vehicle collisions. Under normal conditions, intraabdominal pressure has a mean of 2cm H<sub>2</sub>O, rises to over 10cm H<sub>2</sub>O during inspiration and may reach 100cm H<sub>2</sub>O during Valsalva maneuver. During impact, the maximum value may rise to 1000cm H<sub>2</sub>O. Frontally directed forces are more commonly encountered (3:1), and lead to a blunt deformation of the thoracic cage. [13] This force is transmitted to the diaphragm where it shears the diaphragm and may even cause avulsion injury. [14] The most commonly incarcerated viscera are the spleen, the left colon or the stomach. [15]

In cases of laterally directed forces, thoracic deformation and rib fractures result in a tearing injury of the diaphragm. [3] It is then followed by a herniation of abdominal viscera into the thoracic cavity. The rupture most commonly involves the left hemi diaphragm while bilateral involvement is seen only in exceptionally rare cases. [3] The mechanism can be explained by the lesser resistant left hemi diaphragm from its embryonic development, while the right hemi diaphragm is protected by the liver thus, reducing the energy transfer from blunt force. However, it is critical to recall that right sided ruptures are associated with greater extent of injuries to vital structures and higher mortality rates due to the close proximity of the liver, portal vein, inferior vena cava. [3, 4, 15, 16]

The principal pathophysiological phenomena following a diaphragmatic rupture are insufficiency of the diaphragm,

compression of the lungs from herniated viscera, mediastinal displacement and decreased venous return. [3, 16]

The position of the diaphragm and its anatomic relationship with intrathoracic and visceral organs can explain the high proportion of lesions associated, observed in 52-100% of cases. In this patient, the diaphragmatic rupture was associated with an injury to the ascending colon, followed by herniated of visceral contents into the thoracic cavity.

Early diagnosis is difficult due to its rare incidence, nonspecific clinical presentation and associated lesions which may mask its presence. A chest roentogram and ultrasound are the most common diagnostic modalities for revealing the specific signs indicative of diaphragmatic rupture which are; marked elevation of the hemi diaphragm, intrathoracic herniation of viscera seen by loops of intestine. [17] Occasionally, more complex diagnostic maneuvers may be used such as magnetic resonance imaging, scintigraphy, and colonoscopy, thoracoscopy [3, 16, and 18]. However, these tests can only be performed in a hemodynamically stable patient as they are often lengthy. It is now recognized that the most preferred way to evaluate for a diaphragmic rupture is through a systemic approach.

In this case, the history of trauma and clinical signs pertaining to thoracoabdominal injury such as thoracoabdominal pain, asymmetry of thorax, dyspnea and gurgling bowel sounds over the left hemi thoracic region and radiologic signs showing elevation of the left diaphragmatic dome, herniation greater curvature of the stomach and 1/3 of the left colon, further pointing towards a diagnosis of diaphragmatic rupture

Shah et al, had noted that 43.5% of ruptures were diagnosed before surgical intervention, 41.4% during the perioperative period or during autopsy, and 14.6% in post-operative period. [19] The differential diagnosis of pneumothorax during radiologic imaging should be ruled out while making the final diagnosis. The classification for diaphragmatic lesions provided by the American association of traumatic surgery has been created with the aim of providing a better description of these injuries for aiding accurate diagnosis and guiding interventional therapy: Grade I: Contusion; Grade II: Laceration  $\leq$  2cm; Grade III: Laceration 2-10cm; Grade IV: Laceration  $>$ 10cm with tissue loss  $\leq$  25sq cm; Grade V: Laceration with tissue loss  $>$ 25sq cm; Advance one grade for bilateral injuries. [20]

In the acute phase, a medial approach for laparotomy is the routine choice for access. [16, 20] It offers the possibility for better exploration and repair of lesions in surrounding abdominal organs. Thoracoscopy or laparoscopy is indicated in the hemodynamically stable patient [19, 20]. In general, closure of the defect is performed with interrupted stitches using non absorbable sutures. Use of prosthesis is reserved for delayed repairs in which the diaphragm is retracted and can no longer contribute to adequately to excursion. [4, 18] It is important to adequately wash out the abdominal cavity prior to closure, to remove any clot or contamination. [21]. Prompt recognition of this potentially life-threatening injury is challenging because of the typical associated injuries. Despite

the advent of new techniques in imaging and surgical interventional therapy, the gold standard for diagnosis and treatment has not been described yet. There is still a considerable amount of misdiagnosis, associated with high mortality and high morbidity [22].

## 5. Conclusion

Traumatic rupture of the diaphragm is a rare and challenging diagnosis in the event of a blunt traumatic injury involving several organ systems. The clinical suspicion should be scrutinized in all cases of thoracoabdominal injuries and the decision for surgical intervention should not be delayed for longer than 24 hours. In this patient, the choice for laparotomy has permitted proper exploration of the abdominal organs and adequate restoration of the diaphragmatic continuity.

## Conflict of Interest Statement

The authors declare that there is no conflict of interest with any financial organization or corporation or individual that can inappropriately influence this work.

## References

- [1] Gray's Anatomy: The Anatomical Basis of Surgical Practice. Forty-First Editions. 2016, Elsevier Limited.
- [2] Killeen KL, Mirvis SE, Shanmuganathan K. Helical CT of diaphragmatic rupture caused by blunt trauma. *AJR Am J Roentgenol.* 1999; 173 (6): 1611-6. *AJR Am J Roentgenol* (abstract) – PubMed.
- [3] Slim K. Ruptures et plaies du diaphragme. *J Chir Masson, Paris,* 1999; 136: 67-75.
- [4] Al-Nouri O, Hartman B, Freedman R, Thomas C, Esposito T. Diaphragmatic rupture: Is management with biological mesh feasible? *Int J Surg Case Rep* 2012; 3 (8): 349-53.
- [5] Rodríguez-Morales G, Rodríguez A, Shatney CH. Acute rupture of the diaphragm in blunt trauma: analysis of 60 patients. *J Trauma* 1986; 26 (5): 438-444.
- [6] Gokhan Hacıbrahimoglu, Okan Solak, Aysun Olcmen, Mehmet Ali Bedirhan, Nur Solmazer, Atilla Gurses, Management of Traumatic Diaphragmatic Rupture, *Surgery Today*, February 2004, Volume 34, Issue 2, pp 111-114.
- [7] MD Paul A Kearney, PhD Stephen W Rouhana †, MD Richard E Burney, Blunt rupture of the diaphragm: Mechanism, diagnosis, and treatment, *Annals of Emergency Medicine*, Volume 18, Issue 12, December 1989, Pages 1326-1330.
- [8] Nchimi A, Szapiro D, Dondelinger RF. Injuries of the diaphragm. In: Dondelinger RF, ed. *Imaging and intervention in abdominal trauma*. Berlin, Germany: Springer-Verlag, 2004; 205-236.
- [9] Estrera AS, Platt MR, Mills LJ. Traumatic injuries of the diaphragm. *Chest* 1979; 75 (3): 306-313.
- [10] Shanmuganathan K, Killeen K, Mirvis SE, White CS. Imaging of diaphragmatic injuries. *J Thorac Imaging* 2000; 15 (2): 104-111.

- [11] Go khan Hacıibrahimoglu, Okan Solak, Aysun Olcmen, Mehmet Ali Bedirhan, Nur Solmazer, Atilla Gurses, Management of Traumatic Diaphragmatic Rupture, Surgery Today, February 2004, Volume 34, Issue 2, pp 111-114.
- [12] Gimena Alexandra Ramírez 1, Jorge Alberto Carrillo 2, Liliana Arias 2, Traumatic diaphragmatic Hernia; Case series and topic review, Rev Colomb Radiol. 2012; 23 (4): 3579-86.
- [13] Amber A. Guth, MD 1, H. Leon Pachter, MD 1, Unsup Kim, MD 2, Pitfalls in the diagnosis of blunt diaphragmatic injury, July 1995, Volume 170, Issue 1, Pages 5-9, doi: 10.1016/S0002-9610(99)80242-6.
- [14] Walchalk LR, Stanfield SC: Delayed Presentation of Traumatic Diaphragmatic Rupture. Journal of Emergency Medicine. 2008.
- [15] Bocchini G; Guida F; Sica G; Codella U& Scaglione M. Diaphragmatic injuries after blunt trauma: are they still a challenge? Emerg Radiol (2012) 19: 225–235.
- [16] Turki M, Barhoumi MH, Hajji H, Chemchik H, M'barek B Rupture diaphragmatique droite avec passage total et isolé du foie en intrathoracique Pan African Medical Journal. 2011; 10: 28: 1-7.
- [17] Chao CM, Chang CH, Lai CC. Traumatic rupture of diaphragm. Am J Med Sci. 2012 Aug; 344 (2): 127.
- [18] Mutter D., Schmidt-Mutter C., Marescaux J. Contusions et plaies de l'abdomen. EMC (Elsevier SAS, Paris), Urgences, 24-100-B-30, 2005.
- [19] Hwang SW, Kim HY, Byun JH. Management of Patients with Traumatic Rupture of the Diaphragm. Korean J Thorac Cardiovasc Surg 2011; 44: 348-354.
- [20] <http://www.aast.org/Library/TraumaTools/InjuryScoringScales.aspx#diaphragm>, From Moore et al. [3]; with permission.
- [21] Karim Brohi, CLASSIC CASES Late presentation of diaphragm rupture following blunt thoracic trauma, trauma.org (7:1) January 2002.
- [22] Abha Chandra, M. Ch., Alok Samantaray\*, MD, Govini Balasubramani, MS, Rajendra Sonawane\*\*, M. Ch, Surgical management of diaphragmatic injuries, IJTCVS 203 2007; 23: 202–207.