

Case Report

Abdominal Pregnancy with Live Fetus: A Case Report at Dassa-Glazoue Regional Hospital, Benin 2019

Fanny Hounkponou^{1,*}, Kabibou Salifou¹, Jacques Aubin Kotchofa³, Max Eouani⁵, Hubert Laourou⁴, Aurelle Ahouingnan¹, Chabi Olaniran Alphonse Biaou⁶, Clautaire Itoua⁵, René Xavier Pérrin², Léon Hervé Iloki⁵

¹Maternal and Child Care Department, Faculty of Medicine, University of Parakou, Parakou, Benin

²Maternal and Child Care Department, Faculty of Health Sciences of Cotonou, University of Abomey-Calavi, Abomey-Calavi, Benin

³National Higher Institute of Applied Biosciences and Biotechnology, National University of Science, Technology, Engineering and Mathematics, Dassa-Zoumé, Benin

⁴Human Biology Department, Claude Bernard Lyon 1 University, Villeurbanne, France

⁵Maternity and Surgery Department, Faculty of Health Sciences, Mariën Ngouabi University, Brazzaville, Congo

⁶Epidemiology and Biostatistics Department, Public Health Regional Institute, Ouidah, Benin

Email address:

noumafanny@yahoo.fr (F. Hounkponou)

*Corresponding author

To cite this article:

Fanny Hounkponou, Kabibou Salifou, Jacques Aubin Kotchofa, Max Eouani, Hubert Laourou, Aurelle Ahouingnan, Chabi Olaniran Alphonse Biaou, Clautaire Itoua, René Xavier Pérrin, Léon Hervé Iloki. Abdominal Pregnancy with Live Fetus: A Case Report at Dassa-Glazoue Regional Hospital, Benin 2019. *Journal of Gynecology and Obstetrics*. Vol. 8, No. 4, 2020, pp. 81-84. doi: 10.11648/j.jgo.20200804.12

Received: April 2, 2020; Accepted: May 25, 2020; Published: June 28, 2020

Abstract: We present a case of viable abdominal pregnancy in a 34-year-old gravida 8 para 3 (2 alive) jobless woman living in Glazoué. She had no medicosurgical history and had not been using any contraceptive method. She was referred to Dassa-Glazoué regional Hospital after an obstetrical ultrasound performed four weeks prior to her admission at Abbraccio Sokponta Hospital revealed viable abdominal pregnancy at an estimated gestational age of 31 weeks and 1 day. She had ultrasound scan upon admission to Dassa-Glazoué regional Hospital confirming viable abdominal pregnancy at an estimated gestational age of 34 weeks and 3 days. Exploratory laparotomy was done with delivery of a live female baby via the podalic pole. The neonate was immersed in a clear amniotic fluid, weighting 2,600 g, head circumference 33 cm, chest circumference 31 cm, height 48 cm and Apgar score of 8-9-10. The placenta was extensively attached to the omentum, the bowel and the left uterine appendage. It was fully expelled after ligation of omental and placental feeding vessels, following adhesiolysis. Post-operative evolution was satisfactory, and the patient discharged on the 6th post-operation day with her newborn baby in apparent good health.

Keywords: Abdominal Pregnancy, Live Fetus, Benin

1. Introduction

Abdominal pregnancy (AP) is a rare ectopic pregnancy that is seriously dangerous for both mother and fetus [1-2]. It happens when a fertilized ovum implants outside of the uterine cavity [3]. It occurs in 1 out of 10,000 live births [1]. AP with live fetus is a rare condition which is described by some authors [4, 5]. In Benin, Hounkponou et al. reported a case of

abdominal pregnancy in the same health facility with 1/1337 frequency in the year 2016 [6]. Viable forms of such pregnancies carried to full-term are exceptional, with high morbidity and perinatal mortality, including maternal complications such as intestinal obstruction, infection and severe bleeding [6]. Sometimes, maternal and fetal prognosis could be appreciable. It is one of those rare cases of abdominal pregnancy with live fetus reported by the authors in this article.

2. Clinical Observation

We present the case of a 34-year-old patient, living in Glazoué with no occupation, gravida VIII, 3rd parity, 2 living children, 1 deceased child and 4 spontaneous miscarriages, with neither surgical and medical history nor contraceptive method.

She was referred to the maternity ward with an ultrasound revealing viable abdominal pregnancy at 31 weeks + 1-day gestation. Her last menstrual period was unknown, and she attended no antenatal care. A clinical examination revealed good condition with normal vital signs (blood pressure=110/70 mmHg, temperature=36.9°C, pulse=74 bpm) and jaundice-free bulbar colored mucous eyelid. She did not develop edema of the lower limb and her abdomen was expanded.

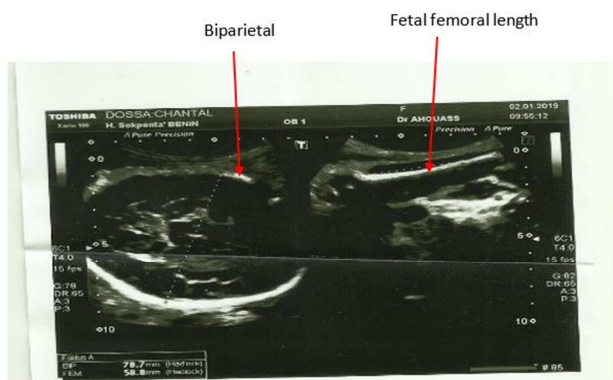


Figure 1. Intra-abdominal fetus.

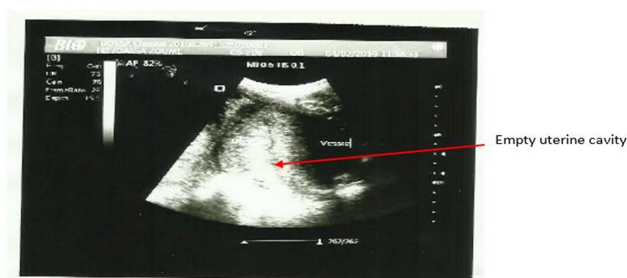


Figure 2. Uterus non gravid.

Abdominal palpation indicated a highly sensitive fetus with a feeling of obvious fetal active movements. Uterine height was estimated at 41 cm. It was difficult to identify fetal pole, therefore Leopold's and Budin's maneuvers were not performed. Fetal heart sounds were barely appreciable with a fetoscope. The vulva was clean. Speculum was used to examine the cervix which was macroscopically healthy looking. Upon vaginal examination, the cervix was semi-long, firm and dehiscent. It was difficult to assess the uterus. The perineum was flexible and vaginal discharge was perceived on the fingerstall. Obstetric ultrasound performed with the abdominal ultrasound transducer at 3,5 MHz confirms active abdominal pregnancy at 34 weeks + 3 days gestation (figure 1) with estimated weight of 2200 g +/- 200 and a barely appreciable placental location, though implanted outside the

liver and spleen. The uterus was empty with a thickened endometrium and a clearly visible cavity line (figure 2).

A minimum preoperative evaluation was performed after diagnosis. This assessment revealed normocytic normochromic anemia with 9.1 g/dl and a B Rh+ blood type. The number of white blood cells and platelets were within normal range. Coagulation profile and magnetic resonance imaging (MRI) of the abdomen and pelvis were not available and could not be carried out. Laparotomy was performed after pre-anesthetic consultation. A subumbilical midline incision was performed under general anesthesia. Through coeliotomy, we perceived a spongy mass and a fetus in the amniotic sac, all contained in the abdominal cavity (figure 3).

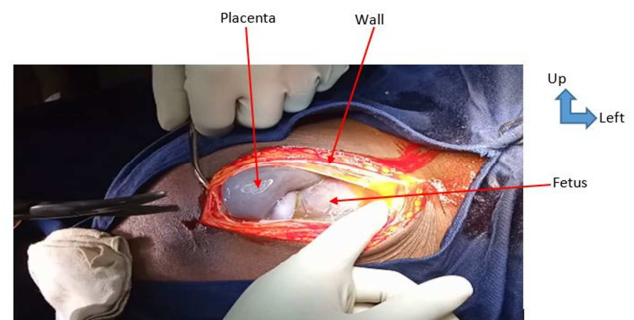


Figure 3. Coeliotomy revealing the fetus and the placenta.

A female newborn was then extracted from the podalic pole. She was immersed in a clear amniotic fluid (AF), weighed 2,600 g, cranial perimeter 33 cm, thoracic perimeter 31 cm, height 48 cm, Apgar score of 8-9-10 and with no apparent malformation. The placenta was strongly adherent to the omentum and the left fallopian tube in the infundibulum (figure 4).

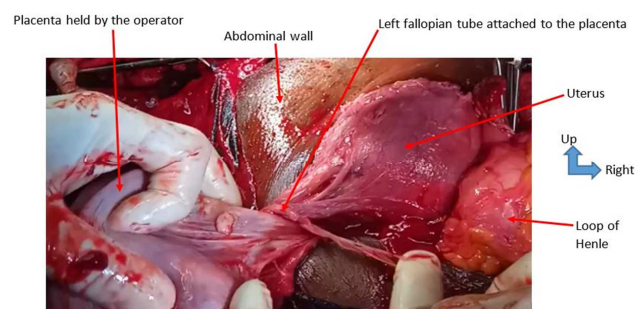


Figure 4. Placenta attached to the left fallopian tube.

The large vessels of the omentum irrigated the placenta. Heavy bleeding occurred after fetal extraction. Omental and placental feeding blood vessels were then ligated and cut for the purpose of hemostasis, followed by left salpingectomy for placenta extraction after meticulous adhesiolysis of the omentum and placenta without omental resection. Hemostasis was satisfactory. Examination of the abdominal cavity revealed a slightly more voluminous uterine and a normal right appendage. The abdominal cavity is cleaned, and the abdominal wall closed in layers, with skin interrupted sutures. Blood loss was estimated at about 850 ml. Urine was

light-colored after surgery. Post-operative evolution was satisfactory, and the patient discharged on the 6th post-operation day with her newborn baby in apparent good health.

3. Discussion

Known as one of the indicators of underdevelopment, abdominal pregnancy is the implantation and development of fertilized egg into the abdominal cavity [7]. A second case discovered in the same health facility in Benin is being reported. The case described in this study was diagnosed in Dassa-Glazoué regional hospital in Benin. In 2016, the same health facility recorded a case of abdominal pregnancy with a 30-year woman [6]. The expectant mother was aged 34 years. Mahi et al described in Rabat in 2000 the case of a 30-year old expectant mother [8]. These features suggest that abdominal pregnancy is a disease that mostly affects young woman. Angela highlighted this aspect in her study [9]. For 1,650 deliveries carried out in a year, one case of abdominal pregnancy successfully managed with laparotomy was realized and resulted in the extraction of a living newborn in apparent good health. This represents 0.060 cases per 100 deliveries. These rare cases of abdominal pregnancies with live fetus may be associated with a viable intrauterine pregnancy. It was the case of heterotopic pregnancy reported by Eouani et al in Congo Brazzaville [10]. The literature corroborates the scarcity of abdominal pregnancies, especially viable AP near term with viable fetus, as reported by the authors in this article. Abdominal pregnancy with viable fetus is less common in developed countries. It is more acute in developing countries as a result of late diagnosis, with a reported incidence between 1/10,000 in developed countries [11] and 3.4/10,000 in sub-Saharan countries, especially in Nigeria [12]. Two main factors account for higher frequency of abdominal pregnancies in developing countries: genital infection and poor prenatal consultations [13]. Although an ultrasound was performed and viable abdominal pregnancy at 31 weeks + 1-day gestation was established, the patient only returned to hospital a month later, despite being referred and sensitized. This attitude reflects expectant mothers' lack of interest in medical examination results and awareness, if they are in apparent good health. According to a Congolese study, women's education level justifies such attitudes [13]. The lack of and/or poor prenatal consultations, and the absence of early diagnosis of the disease contribute to the development of abdominal pregnancy [13]. Kangulu et al inquired whether the development of such pregnancies was not the result of poor prenatal consultations due to service providers' incompetence [13]. We cannot rule out this possibility in the context of Benin given that, rural areas of the country are not all provided with health facilities staffed with qualified personnel. Conducting good clinical and ultrasonographic follow-up of the pregnancy and educating or raising awareness of women on risk exposure during pregnancy could provide opportunity for early diagnosis and prevent the occurrence of complications in relation to this disease [13]. The major peculiarity of this

observation lies in the fact that the live fetus was extracted in apparent good health. It is a rare situation as generally, cases of abdominal pregnancy lead to extraction of stillborn fetus either macerated or not [6, 13]. A case has been reported in Côte d'Ivoire; it was an abdominal pregnancy with live fetus diagnosed through ultrasound at 24 weeks gestation with prospective follow-up and birth expected at 34 weeks gestation. The male neonate weighed 1900 g with Apgar score of 6/9. The placenta was implanted on the small bowel and sigmoid. The newborn had external congenital anomalies including cleft lip, torticollis, feet and limb tendon retraction in the form of talipes equinovarus. He died in neonatology unit 48 hours after birth as a result of respiratory distress [14]. However, in our case the newborn weighed 2600 g, Apgar score of 8-9-10 and without external physical deformity which could be explained by the fact that the fetus was immersed in clear amniotic fluid. The placenta was strongly adherent to the omentum, and the left uterine appendage. With its large vessels, the placental insertion enabled adequate irrigation which ensured proper development and facilitated smooth uteroplacental interactions. The large vessels of the omentum irrigated the placenta. Heavy bleeding occurred but, hemostasis was satisfactory. Recovery was simple for both the mother and the newborn.

As in our study, Hailu et al, also report a case of abdominal pregnancy with a live male infant. The viable newborn weighed 1800 g with Apgar scores of 7 and 8 at 1 and 5 minutes respectively. Both the fallopian tubes and the uterus in the mother's womb looked normal. No rupture or fistula was observed on the uterus. The ovaries were normal and the placenta was implanted on the posterior surface of the uterus and the right broad ligament. It should be noted that the placenta was removed by detaching it from the fundamental part of the uterus to the cul-de-sac [15].

4. Conclusion

Abdominal pregnancy is a rare ectopic pregnancy, especially when it develops normally and is near term. The pregnancy outcome was aided by the fact that the placenta was adherent to the left fallopian tube, thus facilitating fetomaternal circulation. This observation raises the issue of inadequate prenatal consultations, especially the particularity of abdominal pregnancies with live fetus in apparent good health.

Consent

Verbal and written consent was obtained from each patient for the development of this manuscript. The study was anonymous; we have taken care to ensure that no identifiable data was included in the manuscript.

Conflicts of Interest

None of the authors has any possible conflicts of interest.

References

- [1] Beddock R, Naepels P, Gondry C, et al. Diagnosis and currents concepts of management of advanced abdominal pregnancy. *Gynécol Obstét Fertil*. 2004; 32: 55-61.
- [2] Rabinerson D, Berezowsky A, Gabbay-Benziv R. Grossesse abdominale avancée. *Harefuah*. 2017; 156 (2): 114-7.
- [3] Hendriks E, Rosenberg R, Prine L. Ectopic Pregnancy: Diagnosis and Management. *Am Fam Physician*. 2020; 101 (10): 599-606.
- [4] Odelola OI, Akadri AA, LA Agaga, SA Dada. Abdominal Pregnancy: A Case Report of a Viable Nondysmorphic Fetus. *Niger Med J*. 2019 Jan-Feb; 60 (1): 43–5.
- [5] Fouelifack FY, Fouogue JT, Fouedjio JH, Sando Z. Viable abdominal pregnancy: a case report in Yaoundé (Cameroon). *Pan Afr Med J*. 2014; 18: 181.
- [6] Hounkponou NFM, Tchaou B, Obossou A, Salifou K, Sidi RI, Kochoffa JA, Perrin RX- Grossesse abdominale: à propos d'un cas à l'hôpital de zone de Dassa (Bénin). *Méd d'Afr Noire*. 2016; 63 (9): 501-6.
- [7] ISS Sarr, M Faye, PM Faye, M Seck, O Ka, M Dieng. Occlusion intestinale aiguë révélant une grossesse abdominale: à propos d'un cas. *The Pan African Medical Journal*. 2018; 31: 155 p.
- [8] M. Mahi, H. Boumdin, S. Chaouir, T. salaheddine, D. Attioui, T. Amil et al. Un nouveau cas de grossesse abdominale. *J. Radiol*. 2002; 83: 989-92.
- [9] Angela MA, Kovachev EG, Kozovski I, Kornovski YD, Kisyov SV, Ivanova VR. A case of Secondary Abdominal Pregnancy after in Vitro Fertilization Pre-Embryo Transfer (IVF-ET). *Jr Medical Science*. 2015; 3 (3): 426-8.
- [10] Eouani LME, Itoua C, Kombo DB, Iloki LH. Grossesse hétérotopique: particularité anatomo-pathologiques et cliniques à propos d'un cas à l'hôpital général de Loandjili à Pointe-Noire. *Med Afr Noire*. 2015; 62 (4): 184-6.
- [11] Badria L, Amarin Z, Jaradat A, Zahawi H, Gharaibeh A, Zobi A, et al. Full-term viable abdominal pregnancy: A case report and review. *Arch Gynecol Obstet*. 2003; 268: 340–2.
- [12] Sunday-Adeoye I, Twomey D, Egwuatu EV, Okonta PI. A 30-year review of advanced abdominal pregnancy at the Mater Misericordiae Hospital, Afikpo, southeastern Nigeria (1976-2006). *Arch Gynecol Obstet*. 2011; 283 (1): 19–24.
- [13] IB Kangulu1, Ekn Umba1, DK Cibuabua1, CM Ilunga, AU Ndolo1, MK Nzaji1, PKM Kayamba. A propos d'un cas de grossesse abdominale très prolongée. *Pan African Medical Journal*. 2013 16: 26 p.
- [14] E Bohoussou, P Guié, C Saki, G Okon, S Anongba, K Touré-Coulibly. Diagnostic et prise en charge d'une grossesse abdominale avancée. (Abidjan, Côte d'Ivoire). *Rev Int Sc Méd*. 2013; 15 (1): 30-2.
- [15] Hailu, FG, Yihunie, GT., Essa, AA. et al. Advanced abdominal pregnancy, with live fetus and severe preeclampsia, case report. *BMC Pregnancy Childbirth*. 2017, 243: 4p.