

# In Vitro Therapeutic Potential of Leaf Extract of *Eugenia uniflora* linn on Acute – inflammation Rat Model

Elizabeth Finbarrs Bello\*, Abireh Ifeanchi Ezeteonu, Ude Vincent

Department of Anatomy, Faculty of Basic Medical Sciences, Enugu State University of Science and Technology, Parklane, Enugu, Enugu State, Nigeria

## Email address:

elizabeth.finbarrs-bello@esut.edu.ng (E. F. Bello), fenacious@gmail.com (A. I. Ezeteonu), vincentude04@gmail.com (U. Vincent)

\*Corresponding author

## To cite this article:

Elizabeth Finbarrs Bello, Abireh Ifeanchi Ezeteonu, Ude Vincent. In Vitro Therapeutic Potential of Leaf Extract of *Eugenia uniflora* linn on Acute – inflammation Rat Model. *Journal of Diseases and Medicinal Plants*. Vol. 6, No. 2, 2020, pp. 31-38. doi: 10.11648/j.jdmp.20200602.11

Received: February 27, 2020; Accepted: March 18, 2020; Published: May 12, 2020

**Abstract:** The leaves of *Eugenia uniflora* are used as anti-inflammatory and analgesic in the treatment of tissue injury in traditional medicine. The study evaluates the anti-inflammatory, analgesic, hematological and histological effects of ethanol extract of *E. uniflora*. The anti-inflammatory effect was accessed in test groups given different doses (50, 100 and 200 mg/kg, p. o) of the extract, a control group (0.1 mL/kg, normal saline) and standard drug group (Ibuprofen 100mg/kg, p. o) on formalin-induced paw edema. Body weight, paw weight, thickness and volume were evaluated. Analgesic property was accessed on separate group of animals by acetic acid-induced writhing and formalin-induced paw licking tests. Thereafter, hematological parameters were estimated and sections of the edematous skin were processed and stained with H and E. The *Eugenia uniflora* decreased paw volume and thickness after 3hr. There was dose dependent significant ( $P<0.05$ ) decrease in the number of abdominal writhing and insignificant reduction in the second or late phases of formalin-induced paw licking test group. Reduction in RBC, HB, PCV and increase in platelet, ESR, WBC were observed in the formalin-induced paw edema group. Histopathological assessment revealed aggregation of inflammatory cells in skin sections of the untreated group of the formalin-induced paw edema but a noticeable reversal in the extract and Ibuprofen treatment groups. These profiles indicate *E. uniflora* has potent anti-inflammatory and analgesic effects comparable to Ibuprofen a non steroidal anti-inflammatory drug (NSAIDs) and justifies its use in the treatment of inflammation and local tissue injury.

**Keywords:** Edema, Inflammation, Analgesic, *E. uniflora*, Ibuprofen, Formalin

## 1. Introduction

The use of natural remedies for the treatment of local tissue injury has a long history in Ayurveda and other systems of traditional medicine. Presently, Non-Steroidal Anti-Inflammatory drugs (NSAIDs), opioid and corticosteroids are the first line of drugs for the management of pain and inflammatory conditions. These drugs have direct and/or indirect adverse drug effects on the gastrointestinal tract which could cause gastrointestinal bleeding and peptic ulceration [1]. There is scarce literature on the histological impact of the plants that are accessed for anti inflammatory and analgesic activity as drugs. Thus, there is need to source for safer alternatives that have minimal adverse effects and affordable.

*Eugenia uniflora* L. (*E. uniflora*) is a plant in the family

myrtaceae, widely grown in tropical regions, native to Brazil and other countries in the Northern America [2]. The plant is also found in parts of Africa including Nigeria. The decoction of the leaves and fruits of *E. uniflora* have been used in folk medicine for treatment of diarrhea, inflammation, rheumatic pains, fever, stomach problems and hypertension [3, 4]. In Nigeria, the leaves are used as antipyretics, local anti-inflammatory and analgesic in the treatment of tissue injury [5, 6]. Amongst its wide range of biological activities, *E. uniflora* has exhibited hypoglycemic as well as hypolipidemic effects [7]. *E. uniflora* contains primary metabolites like total soluble carbohydrate, protein, total amino acids and secondary metabolites such as flavonoids, total phenol and tannins [6]. A pharmacological study on the leaf extract of *E. uniflora* indicates that its flavonoid fraction inhibits the activity of the xanthine oxidase enzyme, decreases blood pressure via direct

vasodilatation and a slight diuretic effect which could be due to an increase in renal blood flow [4, 8].

Inflammation is part of the complex biological response of body tissues to harmful or injurious stimuli such as pathogens, damaged cells, or irritants and is a protective response involving immune cells, blood vessels and other chemical mediators [9]. It is characterized by classical signs which include heat, pain, redness, swelling, and loss of function [9]. Acute inflammation is the initial response of the body to harmful stimuli is achieved by the increased movement of plasma cells and leukocytes (especially granulocytes) from the blood into the injured tissues. A series of biochemical events propagate and nurture the inflammatory response, involving the local vascular system, the immune system and various cells within the injured tissue. In chronic inflammation, a prolonged inflammatory response involves a progressive change in the type of cells present at the site of inflammation and characterized by simultaneous destruction and repair of the tissue [10]. This can be caused by physical factors like burns, biological factors such as pathogens and trauma due to ionizing radiation, psychological factors like excitement and chemical irritants such as formalin [11].

Formalin is an aqueous (water) 40% solution of formaldehyde, a pungent gas, which can be used as antiseptic, disinfectant and as a fixative for histological tissues. Injection of formalin into the paw of rodents induces an inflammatory process that is associated with edema of the affected area [12, 13]. This study investigates the anti-inflammatory, analgesic, hematological and histological effects of *Eugenia uniflora* extract in rat models in order to establish the likely potential of the plant as source of an anti inflammatory and analgesic drug.

## 2. Materials and Methods

### 2.1. Collection and Preparation of Plant Material

The plant material was harvested from a private botanical garden in Enugu. It was authenticated by a curator in the Department of Plant Science and Biotechnology of the University of Nigeria, Nsukka. The *Eugenia uniflora* leaves were air dried at room temperature for 6 days and pulverized into powdery form using electric grinder (Binatone Inc. BLG-402-1.5L. England). 1762.359g of the powdered sample was soaked in 3litres of 75% ethanol for 24 hours with continuous stirring. Thereafter, the mixture was filtered with whatman paper NO1 and the filtrate was concentrated using water bath at 60°C to obtain the crude ethanol extract of 144.087g which yielded 8.175% of extract. The extract was preserved in refrigerator at 4°C in a dark container until required for the experiment.

### 2.2. Animal Husbandry

Total of fifty-six (56) Wistar rats were purchased from the animal house of the College of Medicine, University of Nigeria, Enugu campus. The rats were bred in the animal facility of animal house of the College of Medicine ESUT,

Parklane Enugu. The animals were housed in netted iron cages in groups of six, fed twice daily with grower's mash and provided water *ad-libitum*. The animals were maintained under standard laboratory conditions (temperature 24°C ~ 25°C, with relative humidity of 60-70% and 12 hours light-dark cycle). They were allowed to acclimatize for two weeks before the commencement of the experiment. Thereafter, the animals were randomly divided into six groups of four animals each, a normal control group and 5 experimental groups. The body weights of the animals were obtained using a weighing scale before and after acclimatization.

### 2.3. Ethical Statement

The experimental procedures and techniques used in the study were in accordance with accepted principles for laboratory animal use and care. All protocols and techniques used in this study were approved by the Faculty of Medicine Research Ethic Committee.

### 2.4. Assessment of Anti-inflammatory Property

Twenty-four rats were used and subdivided into six groups (1-6) of 4 rats each, inflammation was induced in all the groups except group 1 which served as a normal control group. Group 2 animals were injected with 0.1 ml of 2.5% formalin on the sub-plantar region of the left hind paw (untreated). Group 3 animals were injected 0.1ml of formalin (2.5%) and treated with 50mg/kg/bw of *E. uniflora*. Group 4 animals were injected 0.1ml of formalin (2.5%) and treated with 100mg/kg/bw of *E. uniflora*. Group 5 animals were injected 0.1ml of formalin (2.5%) and treated with 200mg/kg/bw of *E. uniflora*. Group 6 animals were injected 0.1ml of formalin (2.5%) and treated with 100mg/kg of standard drug (Ibuprofen).

#### 2.4.1. Paw and Body Weight Measurements

Paw weight was measured using the digital weighing scale at the baseline (0) and end of the 3rd hour. The sole of the right hind paw (that wasn't injected formalin) was measured and was used to estimate the change in paw weight to the left hind paw that was injected with formalin. Therefore the right hind paw served as an initial paw weight. The weight of the paw was measured at the zero hour and 3rd hour after formalin injection.

#### 2.4.2. Paw Volume Paw and Thickness Measurements

Paw volume was estimated using the formula: paw volume (mm)=1/2 (length of long axis × length of short axis × paw thickness [14] at the zero hour and 3rd hour according to the interval as used by Onasanwo [15]. The thickness of the hind paw was measured using a vernier caliper. The baseline paw thickness was first measured before the injection of formalin on the hind paw and then the changes in paw thickness was measured at the zero hour and 3rd hour for each group.

## 2.5. Assessment of Analgesic Property

### 2.5.1. Formalin -induced Paw Licking Test

Sixteen (16) Wistar rats were used for this study. The method of Ardeshtir [16] was adopted; 0.1ml of 2.5% formalin was injected into the subcutaneous region of the left hind paw 60 minutes after oral administration of saline and extract (50,100,200mg/kg) and ibuprofen (100mg/kg) respectively. The licking of the formalin injected paw was indicative of pain. The numbers of licking within 0-5 minutes and 15-30 minutes after injection of formalin were counted. The initial, acute nociceptive response within 0-5 minutes after injection of formalin indicated the first phase while within 15-30 minutes indicated the chronic phase. These phases represented the neurogenic and inflammatory pain responses respectively.

### 2.5.2. Acetic Acid-induced Abdominal Writhing Test

Twenty (20) Wistar rats were used for this study which received intraperitoneal injection of 0.1ml/kg/bw of 3% acetic acid solution 60mins after oral pre-treatments with 0.1ml saline (vehicle), extract (50, 100, 200mg/kg) and ibuprofen (100mg/kg). The number of writhing was observed between 5-15 minutes.

## 2.6. Hematological Evaluation

2ml of blood were collected from each animal at the end of the anti-inflammatory study via the retro-orbital plexus under ester anesthesia into plain and EDTA blood sample bottles as appropriately required to perform analysis of blood hematology included hemoglobin level indicator, hematocrit level, erythrocyte number, and leukocyte number. Hemoglobin level (%) was measured using a hemoglobin Tall Quist scale. Hematocrit level (%), PCV was measured when collecting blood put in microhematocrit heparinized tubes then centrifuged. The erythrocytes and leukocytes were counted directly viewed at 400 x magnifications using a Neubauer chamber [17] Platelet count estimation was done using the Neubauer-Haemocytometer method. Determination of Erythrocytes Segmentation Rate using the Westergen Method.

## 2.7. Histopathological Assessment

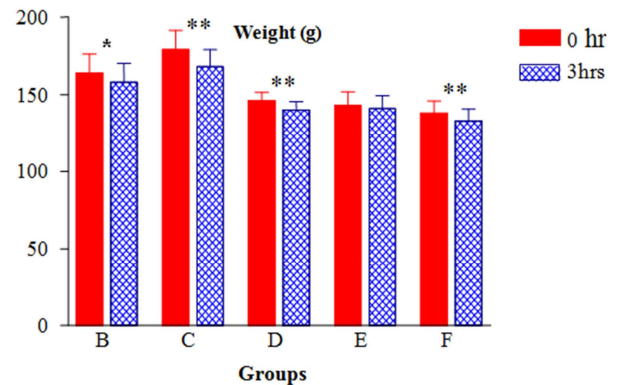
At the end of the formalin-induced inflammation test and after the blood sample have been collected, the animals were sacrificed under inhaled ether anesthesia. The edematous skin was excised and fixed in 10% formal-saline. It was processed, embedded in paraffin; 5µm-thick sections were obtained. Deparaffinized sections were stained with hematoxylin and eosin (H&E). The photomicrographs of each group was captured and interpreted for histopathological changes.

## 2.8. Data Analysis

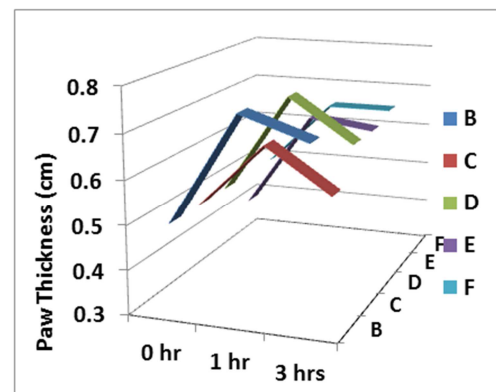
Data on the hematological, inflammatory and analgesic parameters, were analyzed by one-way ANOVA ( $P < 0.05$ ) using statistical package for social sciences (SPSS) version 23, USA, followed by the Bonferroni test. Data are represented as the mean  $\pm$  standard deviation (SD).

## 3. Results

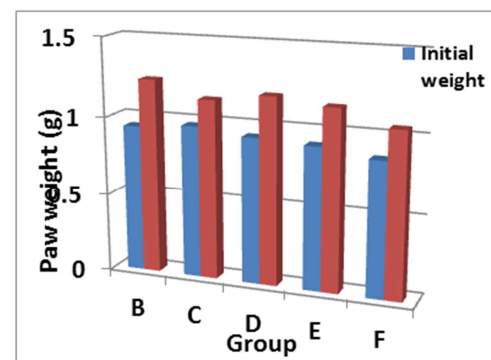
### 3.1. Assessment of Anti-inflammatory Property



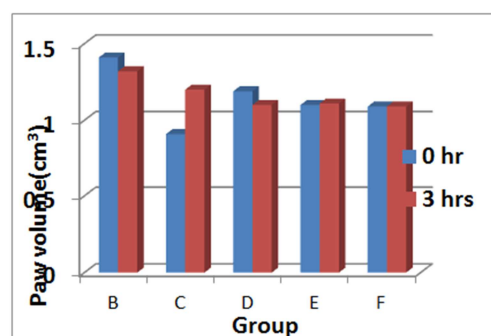
**Figure 1.** Mean weight of animals before (0 hr) and 3 hrs after treatment. Weights showed no significant differences ( $P > 0.05$ ) in treatment groups when compared with the control group at 0 and 3 hrs. However, significant differences were observed in group B ( $p < 0.05$ ), C, E and F ( $p < 0.01$  respectively) after 3 hours of extract administration when compared with the baseline weight before treatment.



**Figure 2.** Anti-inflammatory effect of *E. uniflora* in treated groups. Maximum paw thickness was observed from 1 hour in all groups B, C, D, E and F at  $0.75 \pm 0.03$ ,  $0.65 \pm 0.03$ ,  $0.73 \pm 0.05$ ,  $0.65 \pm 0.05$  and  $0.65 \pm 0.03$  respectively. No significant differences were observed between treatment groups compared to A the control. Analysis of trend showed significant differences in groups A ( $p = 0.0043$ ), E ( $p = 0.0088$ ) and F ( $p = 0.0015$ ).



**Figure 3.** Effect of *E. uniflora* on paw weight of formalin induced inflammation in rats. No statistical significant changes ( $p > 0.05$ ) were observed between treatment groups. Group B, C, E and F revealed statistical significant increase,  $p = 0.003$ ,  $p = 0.029$ ,  $p = 0.014$  and  $p = 0.016$  respectively) in paw weight 3 hours after extract administration when compared with their corresponding baseline paw weight.



**Figure 4.** Mean paw volume of treated animals. No significant changes in paw volume before treatment and 3 hours after treatment in all the study groups. However statistical significant changes were observed in treatment groups (C  $P<0.01$ , E  $p<0.05$  and F  $p<0.05$ ) when compared with the control at baseline and no significant difference ( $p>0.05$ ) 3 hours after administration.

### 3.2. Analgesic Assessment

In group A, early phase ( $66.75\pm14.49$ ) compared with late phase ( $102.5\pm32.65$ ), it showed an increase though statistically insignificant. A statistically non-significant increase also occurred in groups B, early phase ( $60.75\pm29.55$ ) and late phase ( $72.25\pm5.94$ ), C early phase ( $50.25\pm27.51$ ) and late phase ( $60.75\pm55.45$ ) and E early phase ( $48.25\pm38.58$ ) and late phase ( $60.75\pm30.67$ ) when each of these groups late and early phases were compared. Group D, an exception, showed a statistically non-significant decrease when the early phase ( $6.25\pm4.25$ ) and late phase ( $0.75\pm0.75$ ) were compared. Though, there were increases in groups A, B, C and E and a decrease in group D, all were not statistically significant as all their p-values are higher than 0.05.

**Table 1.** Effect of Formalin –Induced Paws Licking.

	Group a	Group b	Group c	Group d	Group e	Pvalue
Early phase	66.75±14.4	60.75±29.55	50.25±27.51	6.25±4.25	48.25±38.5	0.529
Late phase	102.5±32.6	72.25±5.94	60.75±55.45	0.75±0.75	60.75±30.6	0.302

**Table 2.** Abdominal writhing test.

Group A	Group B	Group C	Group D	Group E	P-Value
19.25±2.29	22.5±1.84	A 9.00±0.71	C 1.00±0.71	D 8.00±0.41	<0.001

### 3.3. Hematological Result

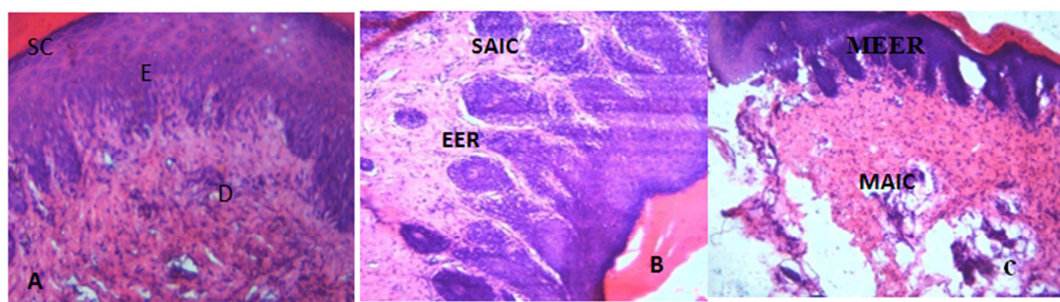
**Table 3.** Hematological parameters.


Parameter	Group a	Group b	Group c	Group d	Group e	Group f	Pv
PCV	45.75±3.73	44.0±5.82	40.0±3.16	44.0±2.94	52.5±0.96	46.25±1.11	0.202
HB	15.55±1.27	14.95±1.95	13.60±1.07	14.93±0.49	17.88±0.34	15.68±0.37	0.194
WBC	7950±170.78	9800±408.25	9000±355.90	ab 8925±288.87	Ab 7750±221.74	Ab 8700±129.10	<0.01
PLATELET	97.5±8.54	267.5±12.5	A 245±17.08	Ab 225±8.66	Ab 188.75±11.97	Ab 235±6.45	<0.01
ESR	102.5±24.28	122.5±8.54	77.5±12.33	85.0±3.53	132.5±4.79	86.25±8.51	0.03
R BC	197.5±20.16	195±28.72	175.0±10.4	185±6.45	230.0±4.08	180.0±10.8	0.227

It is statistically significant when  $p<0.05$ . Group A ( $19.25\pm2.29$ ) compared with group B ( $22.5\pm1.84$ ) revealed a statistically non-significant increase while group A and group C when compared showed a statistically significant decrease in group C ( $p<0.01$ ). Furthermore, group A compared with group D and E, both showed a statistically significant decrease; group D ( $p<0.001$ ) and group E ( $p<0.001$ ) respectively. All the values are expressed as mean±SD (n-6 for each group). values not sharing a common alphabet as superscripts are significantly different from each other at the level of ( $P<0.01$ ) and ( $P<0.05$ ) respectively.

### 3.4. Histopathological Findings

Section of hind paw of control showed normal skin tissue histology (A), Section of hind paw of animal lesions which include the elongation of the epidermal ridge (EER) and severe aggregation of inflammatory cells. However, hind paw sections of group treated with different doses of the extract (C – E), showed improvement of the above symptoms, reduced skin lesion and aggregation of inflammatory cells. Ibuprofen (F) treatment showed a significant improvement, but not up to high dose of extract (E).





**Figure 5.** A Control section of hind paw shows normal section of hind paw of skin with epidermis (E), dermis (D) and stratum corneum (SC). B-section of hind paw induced with formalin only shows skin lesion with elongation of the epidermal ridges (EER) and severe aggregation of inflammatory cell (SAIC). C- section of hind paw induced with formalin and 50mg /kg of *Eugenia uniflora* leave extract shows mild healing with moderate elongation of the epidermal ridges (MEER) and moderate aggregation of inflammatory cell (MAIC). D- section of hind paw induced with formalin and 100mg /kg of *Eugenia uniflora* leave extract shows mild healing with moderate aggregation of inflammatory cell (MAIC) and focal area of ulceration within the dermal layer. E- section of hind paw induced with formalin and 200mg /kg of *Eugenia uniflora* leave extract shows moderate healing in epidermis. However there focal area of ulceration (FAU). F- section of hind paw induced with formalin and 100mg /kg of ibuprofen shows moderate healing in the layers of the skin shown and area of ulceration (AU) within the dermis. (X100)(H/E).

## 4. Discussions

Inflammation is a normal and pathological reaction following an injury, and characterized by redness, swelling, heat, pain and loss of function. The anti-inflammatory effect of *Eugenia uniflora* was evaluated using formalin- induced acute inflammation model which has been used in screening candidates for anti-inflammatory property in preclinical studies [17]. Its effect was compared with ibuprofen a standard non steroidal anti inflammatory drug (NSAID) which exhibits its anti inflammatory effect via prostaglandin, cyclooxygenase -1 and, cyclooxygenase -2 inhibition, neutrophil migration suppression, and oxygen free radical inhibition [18]. This plays an important role retarding inflammatory processes after acute injury, limits the area of secondary tissue damage and speed up recovery after acute soft tissue injuries [19].

The findings in this study were positive and treatment with ethanolic extract of *E. uniflora* showed a progressive decrease in body weight reduction in a dose.

Dependent manner when compared with its initial weight (0hr) and weight after 3hrs of formalin induction in each of the extract, groups. This change in body weight observed in 100mg/kg of extract group D was found to be significantly ( $P < 0.05$ ) comparable with that of the ibuprofen pretreated group i.e. when comparing the rate of their ability to return the body weight back to normal (level of the initial weight at 0hr). The significant decrease in body weight of the Wistar rats 3hrs after induction of formalin in the hind paw in 100mg/kg group of extract group was possible due to the presence of protein in the phytochemical content *E. uniflora* [4]. Therefore, this present study shows that high dose (200mg/kg) of extract even though not statistically significant slightly brought the weight to normal which was not observed in the standard drug. A peak increase in paw thickness was exhibited with *E. uniflora* extract treatment. This was previously noted in same model of acute inflammation [16, 20]. Formalin also increased paw volume which correlates with previous reports [13, 21, 22].

However, *E. uniflora* decreased paw volume in a dose dependent manner. Its high dose exhibits similar effect as the standard drug. This implies the anti-inflammatory effect of *E.*

*uniflora* in reduction in paw weight, volume and thickness [13; 23].

The analgesic effect of *Eugenia uniflora* Linn was assessed by the paw licking test, acetic induced abdominal writhing and compared with ibuprofen [24]. Formalin produced a distinct biphasic response, an early and later phase reflecting different stages of pain [15]. The early phase of pain was attributed to the direct activation of nociceptors and primary afferent fibers by formalin, leading to the release of bradykinin and tachykinin [25, 26]. *E. uniflora* decreases the number of paw licking in a dose dependent manner with the most effective dose being the high dose of the extract. This implies a dose dependent or biphasic analgesic effect of the extract which could be triggered by modulatory release of bradykinin and tachykinin. The tissue injury would also cause release of histamine, serotonin, prostaglandin [27, 28]. Therefore, the potency of the extract is comparable to the standard drug.

The writhing reflex mimics model of visceral pain and an open response to the intense pain induced by irritants [29]. This pain induced by irritants is characterized by retraction of the abdomen and stretching of hind limbs. A mediator such as prostaglandin which contributes to the sensitivity of pain is released when the signal is transmitted to the central nervous system (CNS) [30]. The level of analgesic in acetic acid induced model is indicated by the percentage of reduction in the number of abdominal constrictions [31]. The *E. uniflora* showed a significant decrease in the number of writhing in a dose dependent manner but this time the middle dose was considered the effective dose for the analgesic activity. The analgesic effect of *E. uniflora* seen in this experiment maybe mediated through suppression of prostaglandin pathway [32] which plays a role in the production of pain, inflammation and fever.

White blood cell (WBC) plays a major role in protecting the body against both infectious disease and foreign body invasion and may increase during inflammation due to the release of interleukins. In present study, *E. uniflora* treatment reduced WBC and platelet counts indicate substantial recovery from inflammatory process. This is a common feature of anti inflammatory agent to cause retraction of leucocytes which were early mobilized to the site of injury

where they provide defense to ret to retract following intervention. Likewise, platelet plays vital role of blood clotting during inflammation by releasing interleukin 11 (IL-11) [33]. *E. uniflora* increased RBC, Hb, and PCV may suggest increase production of red blood cells, since the inflammatory process does not lead to loss of blood, the granulocytes tend to be the major group of blood cell recruited in the process. The increase is a tissue response to functional demand as in the case of anemia which is a normal pathological condition notable in inflammation due to deprived oxygen supply to the damaged tissues [34]. In addition, several studies have indicated that inflammation and NSAIDs (anti-inflammatory agents) often increases ESR [33, 35-38].

The epidermis and the dermis of the skin normally exist in steady state equilibrium to form a protective barrier of internal organs against entry of infections or other noxious agents from the environment. Damage to the skin layers initiates complex biochemical responses that lead to tissue repair or normal healing. this process is characterized by dynamic and interactive events described in three phases, inflammation, proliferation and remodeling.

In histopathological study, to investigate the anti-inflammatory effect of the ethanol extract of *E. uniflora*, Group1 (negative control) which received normal saline under a light microscope showed a normal skin tissue while the group2 (positive control) that received formalin (an inflammatory agent) showed skin lesion with elongation of the epidermal ridges and severe aggregation of inflammatory cell. This finding correlates with the research work done by [13, 39, 40]. This observed effect proves the presence of inflammation to the skin tissue. Group3 (50mg/kg of extract) showed mild healing with moderate aggregation of inflammatory cell and moderate elongation of epidermal ridges. Micrograph of group4 (100mg/kg of extract) showed mild healing with moderate aggregation of inflammatory cell and ulceration of the dermal layer of the skin. Group5 & group 6 showed moderate healing with no aggregation of inflammatory cells nor elongation of epidermal ridges.

Extract dose of 100mg, 200mg & standard drug showed ulceration of dermal layer of the skin. Skin ulceration is a tissue loss involving the deep layer of the dermis and hypodermis with low tendency to spontaneous healing, which can be caused by chemotherapy agents, trauma, and tumors. Therefore 100mg/kg (middle dose) and 200mg/kg (high dose) of extract can lead to skin ulceration. From the analysis of the results above, it can be deduced that the high dose of the extract (200mg/kg) showed almost the same potency as that of the standard drug.

## 5. Conclusion

In conclusion, the present experimental findings of hematological, histopathological, paw volume paw thickness, paw weight and body weight studies suggests that *Eugenia uniflora* L is a promising anti-inflammatory and analgesic agent in the treatment of inflammation and tissue injury. it

effect could be have been mediated by the presences of flavonoid.

## Conflicts of Interest

All the authors do not have any possible conflicts of interest.

## Acknowledgements

Cordial thanks to staff of Histology and Biochemistry laboratories for providing the technical and experimental supports.

## References

- [1] Davies NM (1998). Clinical pharmacokinetics of ibuprofen, the first 30 years. Clin Pharmacokinet. 34: 101–154.
- [2] Francine N V, Eder JL, Lucielli S, Gelson P, Raquel GJ, Diego A, Wladimir P S, Amanda de S, M, Patricia da S N (2012). Essential oil of the leaves of *Eugenia uniflora* L.: Antioxidant and antimicrobial properties. Food and Chemical Toxicology. 50 (8): 2668-2674.
- [3] Almeida CE, Margo GO. Karnikowski, RD, Bernado B (1995). Analysis of antidiarrhoeic effect of plant used in popular medicine. Revista de Saude Lica. 29: 428-33.
- [4] Consolini AE, Sarubbio MG (2002). Pharmacological effect of *Eugenia uniflora* (Myrtaceae) aqueous crude extract on rat's heart. J. Ethnopharmacol. 81 (1): 57-63.
- [5] Consolini AE, Baldini OA, Anat AG (1999) Pharmacological basis for the empirical use of *Eugenia uniflora* L. (Myrtaceae) as anti hypertensive. J Ethnopharmacol. 66: 33-39.
- [6] Daniel G, Krishnakumari S (2015). Screening of *Eugenia uniflora* L. Leaves in various solvent for qualitative phytochemical constituents. International Journal of Pharm and Bio Sciences. 6 (1): 1008-1015.
- [7] Lestari SR, Muhaimin R (2019). The effect of single-bulb garlic oil extract toward the hematology and histopathology of the liver and kidney in mice. Brazilian Journal of Pharmaceutical Sciences. 55: e18027 55: 1-8.
- [8] Ferrero M, Nielson OH, Anderson PS, Girardin SE (2007). Chronic inflammation: importance of NOD2 and NALP3 in interleukin-1 $\beta$  generation. Clini. Exp. Immunol. 142: 2-10.
- [9] UrsulaW (2008). Inflammation. NatureResearch. 454: 427-35.
- [10] Piira OP, Miетinen JA, Hautala AJ, Huikuri HV, Tulppo MP (2013). Physiological responses to emotional excitement in healthy subjects and patients with coronaryarterydisеase. Auton Neurosci. 177 (2): 280-285.
- [11] Pandey CK, Agarwala, Baronia A, Singh N (2000). Toxicity of ingested formalin and its management. Hum Exp Toxicol. 19 (6): 360-6.
- [12] Yoon-Hee, C, Woo-hyuncheon H, Sae K (2011). Effect of DHU001, a polyherbal formular on formalin-induced paw chronic inflammation of mice. Toxicological Research. 27 (2): 95-102.

- [13] Kim HD, Cho KH, Lee BW, Kwan YS, Choi SH, Lee HS, Ku SK (2010). Effect of magnetic infra-red laser on formalin induced chronic paw inflammation in mice. *Toxicol Res.* 22: 395-404.
- [14] Onasanwo SA, Saba AB, Oridupa OA, Oyagbemi AA, Owoyele BV (2011). Anti-nociceptive and anti-inflammatory properties of the ethanolic extract of *Lagenaria breviflora* whole fruit in rat and mice. *Nigerian Journal of Physiological Sciences.* 26 (1): 71-6.
- [15] Ardeshir A, Samaneh O, Hamid Y, Neda SK (2015). Effect of royal jelly on formalin induced inflammation in rat hind paw. *J. Nat Pharm Prod.* 10 (1): e22466. 22471.
- [16] Madhur P. Motwani, Justin Newson, Simon Kwong, Angela Richard-Loendt, Romain cola, Desmond Dalli, Derek W. Gilroy (2017). Prolonged immune alteration following resolution of acute inflammation in humans. *Journal Pone.* 31: 141-142.
- [17] Leng SX, Elias JA (1997). Interleukin-11 *International Journal of biochemistry and cell biology.* 29: 1059-62.
- [18] Nam JK, Ji YP, Hee CH, Seong HG (2001). Analgesic and anti-inflammatory effects of ibuprofen, indomethacin and ns-398 on an acute model of arthritis in rats. *Korean journal of anesthesiology.* 40 (6) 802-814.
- [19] Rabia B, Nousheen AS (2010). An overview of clinical pharmacology of Ibuprofen. *Oman Med J.* 25 (3): 155–1661.
- [20] Griffis, JR, McDonald, TG, Smith, VE (2009). *Eugenia uniflora* a nutritious, easy to grow fruit for tropics. *Acta Hort.* 806: 277-284.
- [21] Jun Z, Aosimanjiang M, Chenyang Li, Qian Li, Fang Xu, Tao L (2018). Evaluation of Analgesic and Anti-Inflammatory Activities of Total Flavonoids from *Juniperus sabina*. *Hindawi.* 3: 9-12.
- [22] Meena S, Kaniraja S, Mary Sharmila C, Visweswaran S, Banumathi (2018). Evaluation of Anti Inflammatory Activity of Vajravalli Chooranam by Formalin Induced Paw Odema Method in Albino Rats. *International Journal for Pharmaceutical Research Scholars.* 7: 1-3.
- [23] Kasim MJ, Zheen AA, Intesar TN, Saad H (2009). Dose-dependent anti-inflammatory effect of silymarin in experimental animal model of chronic inflammation. *African Journal of Pharmacy and Pharmacology.* 3 (5): 242-247 .
- [24] Wahbi AA, Hassan E, Hamdy D, Khamis E, Barary M (2005). Spectrophotometric methods for the determination of Ibuprofen in tablets. *Pakistan Journal of Pharmaceutical Sciences.* 18 (4): 1-6.
- [25] Onasanwo SA, Elegbe RA (2006). Antinociceptive and Anti-inflammatory Properties of the leaf Extract of *Hedranthera barteri* in Rats and Mice. *African J Biomedical Research.* 2: 109-118.
- [26] Shibate M, Ohkubo T, Takashi H, Inoki R. Modified formalin test. *Pain.* 1989; 38: 345–52.
- [27] Correa CR, Calixto JB (1993). Evidence for participation of B1 and B2 kinin receptors in formalin-induced nociceptive response in the mouse. *Br J. Pharmacol.* 110: 193-198
- [28] Coderre TJ, Melzack R (1992). The contribution of excitatory amino acids to central sensitization and persistent nociception after formalin-induced tissue injury. *J Neurosci.* 12: 3665–70.
- [29] Damas J, Liegeois JF (1999). The inflammatory reaction induced by formalin in the rat paw. *Naunyn Schneidebergs Arch Pharmacol.* 359 (3): 200-7.
- [30] Raquibul SM, Hossain, MM, Aktar R, Jamila, M, Mazumder MEH, Alam MA (2010). Analgesic Activity of the Different Fractions of the Aerial Parts of *Communica Benghalensis* Linn. *International Journal of Pharmacology.* 6 (1): 63-67.
- [31] Shivaji P G (2012). Acetic acid induced painful endogenous infliction in writhing test on mice. *Journal of Pharmacology and Pharmacotherapeutics.* 3 (4): 348.
- [32] Machioro M, Blank MFA, Moura RHV, Antioniolli AR (2005). Antinociceptive Activity of the Aqueous Extract of *Erythrina velutina* leaves. *Fitoterapia.* 76: 637-42.
- [33] Ferdous M, Rouf R, Shilpi JA, Uddin SJ (2008). Anti-nociceptive activity of the ethanolic extract of *Ficus racemosa* (Lin). *Oriental Pharm Exp Med.* 8: 93-96.
- [34] Sriram S, Meenaa V, Kavitha J, Brindha P, Sasikumar, C (2016). Anti-inflammatory screening of ethanolic leaf extract of *Vernonia arborea* Buch.–Ham. In formalin induced albino wistar rats. *Indian Journal of Pharmaceutical Education and Research.* 50: 638-648.
- [35] Sumathi S, Anuradha R (2018). Anti-inflammatory activity of Dimethyl cardamonin on formalin induced paw edema in albino rats. *Int J Biol Med Res.* 9 (2). 6338-6344.
- [36] Vijayabharathi R, Vidhya N, Sivasithamparam ND (2018). Anti-inflammatory activity of *Alpinia officinarum* hance on rat colon inflammation and tissue damage in DSS induced acute and chronic colitis models. *Food Science and Human Wellness.* 7: 273-281.
- [37] Ismail OI, Sunday OO, Ibrahim AO, Chikaodili II, Temidayo DP (2015). Antinociceptive and anti-arthritic properties of hydroethanolic leaf extract of *Clausena anisata* (Willd.) Hook fex Benth (Rutaceae) in Rodents: possible mechanism of actions MNiger. *J. Physiol. Sci.* 30: 39-49.
- [38] Agnel AJ, Shobana G (2012). Anti-inflammatory activity of *Talinum fruticosum* L. on formalin induced paw edema in albino rats. *Journal of Applied Pharmaceutical Science.* 2 (1): 123-127.
- [39] Hyeong-Dong K, Kwang-Ho C, Byung-Wook L, Young-Sam K, Hyeung-Sik L, Seong-Hun C, Sae-kwang K (2010). Effects of Magnetic Infrared Laser Irradiation on Formalin-Induced Chronic Paw Inflammation of Mice. *J. Phys. Ther. Sci.* 22: 395- 404.
- [40] Ali AH, Behnam G, Mohammad AB (2013). Potentiation of Indomethacin-Induced anti-Inflammatory Response by Montelukast in Formalin-Induced Inflammation in Rats. *Acta Medica Iranica.* 51 (10): 675-680.