

Magnetic Resonance Imaging Staging of Tongue Cancer: Correlation of Radiographic Measurements to Pathology

Antigone Delantoni

Faculty of Dentistry, Dept of Dentoalveolar Surgery, Implant Surgery and Radiology, Aristotle University of Thessaloniki, Thessaloniki, Greece

Email address:

andelant@dent.auth.com

To cite this article:

Antigone Delantoni. Magnetic Resonance Imaging Staging of Tongue Cancer: Correlation of Radiographic Measurements to Pathology. *Journal of Cancer Treatment and Research*. Vol. 3, No. 6, 2015, pp. 66-75. doi: 10.11648/j.jctr.20150306.11

Abstract: Tongue cancer is in the majority of cases treated surgically. A good radiological report is required for the effective surgical treatment as well as for the best outcome and survival rate of the patients. The aim of the study was to evaluate the use of presurgical MRI in the classification and staging of tongue cancer. 45 presurgical MRI exams of patients with tongue cancer were viewed from the Dept. of Oral and Maxillofacial clinic files. The basic tumor's dimensions were measured by two oral radiologists and were then compared with the histological findings of the tumor which were used as the gold standard. Besides the three dimensions of the tumor that were measured the overall volume of the tumor was measured and compared to the volume of the histopathology report. Results: The images were in the majority T2-weighted images. The correlation between the tumor's dimensions was excellent in the cases of the length and width of the lesion ($r > 0.9$) but was not as efficient in the depth of the tumor. The volume estimate and measurement of the tumor was well correlated to the histopathological findings. Conclusions: The present study showed that MRI images are adequate to establish the dimensions of tumors and the depth of tumor invasion.

Keywords: Tongue Cancer, Radiology, MRI

1. Introduction

Malignancies of the oral cavity and the oropharynx represent about 2-5% of all malignancies. The vast majority of these tumors are squamous cell carcinomas (about 90%) [1]. Tongue cancer is the most frequently occurring of all oral carcinomas. Due to the proximity of the oral cavity to a variety of lymph nodes it is highly significant to set a proper presurgical evaluation of all tumor characteristics.

The major role of presurgical diagnostic imaging in the oral cavity is to establish the direction and extension of tumor invasion [2]. The depth of tumor invasion is known to be a prognostic factor to establish the probability of metastasis in the adjacent areas of the neck [3-6,19]. Accurate assessment of the tumor dimensions is therefore important for planning the patient's surgery particularly since surgery is considered the first choice of treatment for carcinoma of the tongue [7-8].

In carcinomas of the tongue MRI has been proven superior to CT in depicting the tumor and its surrounding structure [9]. It is the technique performed for the initial assessment of carcinomas of the tongue (10) and it sets the criteria for the

type of surgery to be performed.

The purpose of this retrospective study is to evaluate presurgical MRI findings and compare them to histopathology to determine the accuracy of the diagnostic method which sets the standards for the operation procedure and is therefore of high significance.

2. Materials and Methods

From January 2000 until June 2009 97 cases of tongue cancer had been treated surgically at the Oral Surgery clinic of Papanikolaou University Hospital of Thessaloniki, Greece. From those 97 patients 36 had CT examination prior to surgery, 2 did not want to be operated on, 9 turned out to be histopathologically benign lesions and 5 were not squamous cell carcinomas but other type of histological lesions. Only 45 fulfilled the inclusion criteria of having presurgical MRI examinations without having any other type of presurgical therapy scheme applied to them. These 45 patients were included in the study. All the patients had biopsy proven squamous cell carcinoma of the tongue.

Initially a TNM staging was determined from the MRI

radiographs that were in the patients files according to the International Union against Cancer criteria [11]. Of the 45 patients 29 were diagnosed as T1 and only 16 as T2. None were T3 or T4. Regarding the N factor, there were 24 patients with N0, 13 with N1, 4 with N2b and 4 with N2c. Regarding the M factor according to the initial presurgical MRI examination there were no patients with distant metastases. The classification of the patients according to the TNM criteria is seen in Table 1.

Table 1. MRI staging of the 45 patients with squamous cell carcinoma of the tongue.

	T1	T2
N0	24	0
N1	5	8
N2	0	8 (4 N2b/ 4 N2c)
Total	29	16

The presurgical MRI for 37 of the 45 patients was performed with a 1,5-T unit prior to the initial surgery of the patient. The other 8 MRI examinations were performed with different units and were in the patients records upon the initial examination since a large number of patients were referred to the clinic and were not initially examined there. Being a retrospective analysis there was no differentiation between the various MRI sequences. All MRI images were included in the study as they were in the patients' files. From the number of images included note should be made on the sequence type. All 45 patients had T1 weighted images in their files (anatomical images) and those images were included in the study. The images were compared to the pathology report that was provided after surgery. The majority of patients had partial glossectomy of

hemiglossectomy performed (42) while only 3 patients had total glossectomy performed. The specimens obtained from surgery were then studies using H and E stain and were examined microscopically.

The results of the pathology were then compared to the presurgical MRI of the patient whose findings were determined by two of the researchers.

3. Results

The statistical analysis included student's t Test for paired data and the results obtained from the paired t tests were confirmed with the non parametric Wilcoxon Rank Sign Test for all the data (dimensions if tumor and overall volume measurements).

The tumors' dimensions were measured from the presurgical radiographs of the patients' files and were compared to the histopathologic measurement as were provided by the pathologist.

Regarding the measurement of the length of the tumor the correlations graphs in figure 1A and the t probability value of $0.2858 \gg 0.05$ indicates that the paired differences between the values of the Measured Length and the Histopathological Length are not significant at the 0.05 level. The correlation probability of $< .0001$ shows that the correlation coefficient is significantly greater than zero. As it is shown by the correlation coefficient ($R = 0.9946$) and the above diagram there is a strong linear correlation between the Measured Length and the Histopathological Length. This is also well demonstrated in the box plot graphs between the two methods studied (figure 1B)

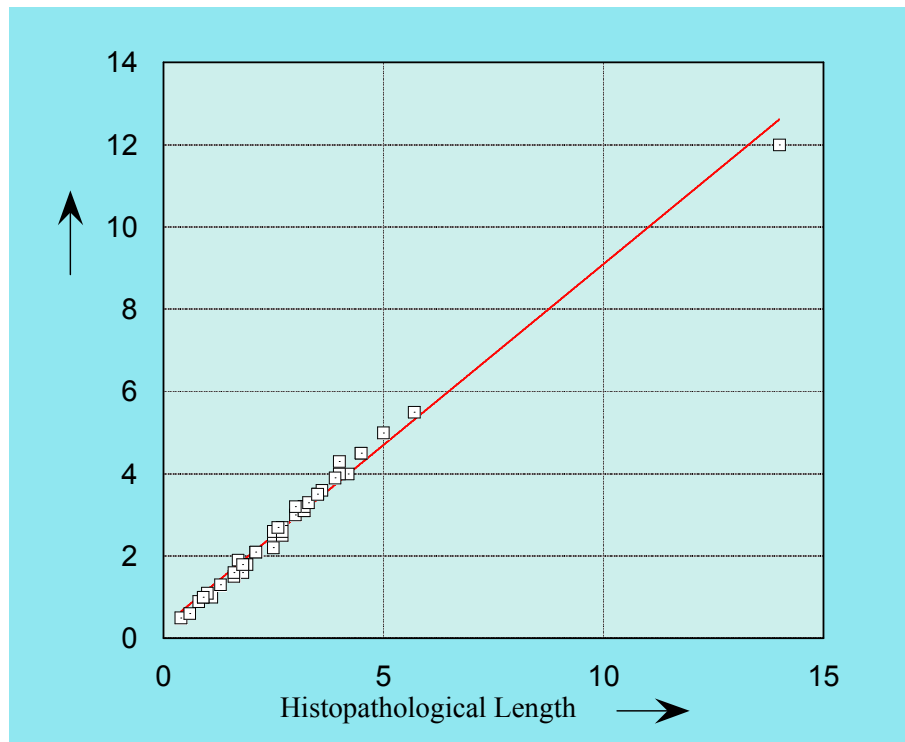


Figure 1. A. Linear correlation between measured and histopathological length.

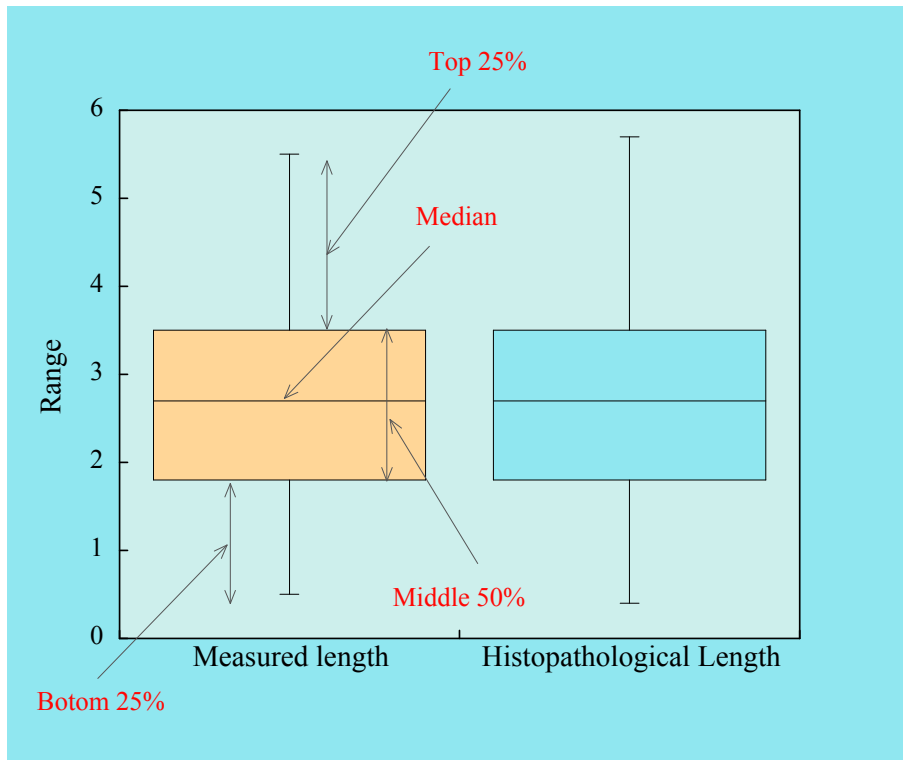


Figure 1. B. Distribution data (boxplots) of the Length scores obtained by the two Methods.

Regarding the measurement of the width of the tumor the correlations between histopathology and MRI measurements can be seen in figure 2A. The t probability value of 0.6504 \gg 0.05 indicates that the paired differences between the values of the Measured and the Histopathological Width are not significant at the 0.05 level. The correlation probability value shows that the correlation coefficient is

significantly greater than zero. As it is shown by the correlation coefficient ($R = 0.9849$) and the above diagram, there is strong linear correlation between the Measured and the Histopathological Width, which is also well depicted in figure 2B, the box plots of the two methods applied. The correlation is very strong; however the length of the tumor correlation was slightly stronger.

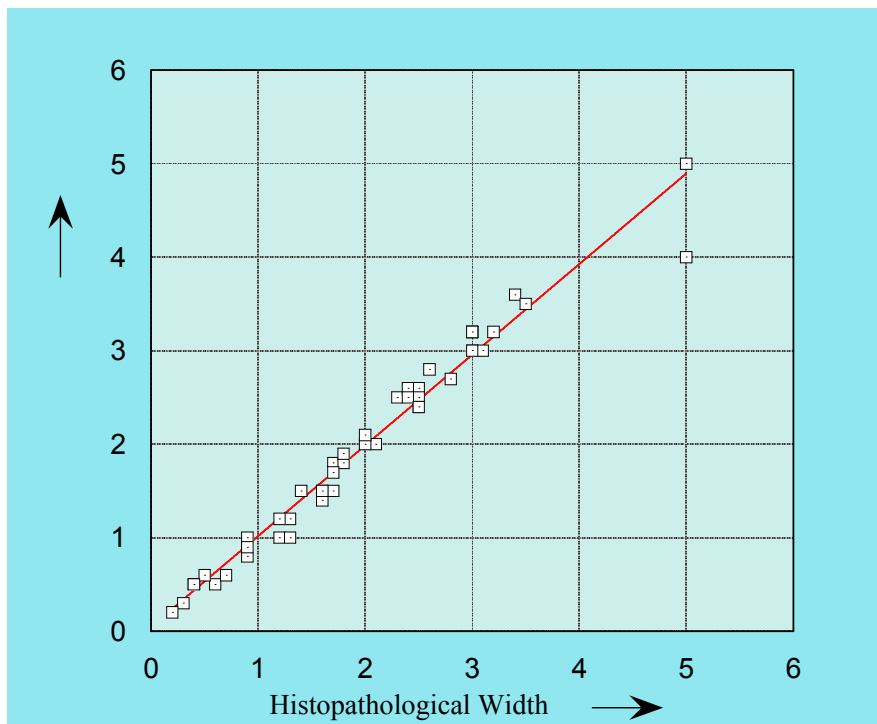


Figure 2. A. Linear correlation between measured and histopathological width.

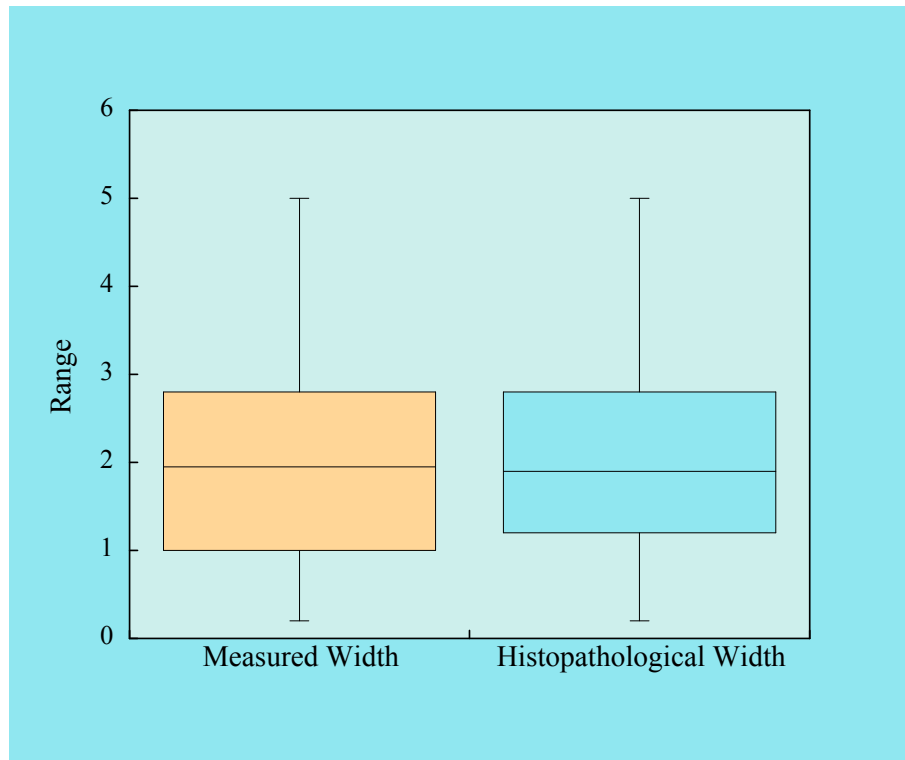


Figure 2. B. Distribution data (boxplots) of the Width scores obtained by the two Methods.

Regarding the final dimension of the tumor known as depth of the tumor (extend of the tumor in tissue depth, point from deepest tumor invasion to the presumed original surface level ignoring exophytic growth) the results obtained are shown in figure 3A and indicate that at the significance level 0.05 (5%) the paired differences between the values of the Measured and the Histopathological Depth are not significant. However at the 0.07 level (7%) these differences are significant. Also there is a strong linear correlation between the Measured and the Histopathological Depth as is shown by the correlation value of 0.97079. Overall the correlation between the two measured depths of tumors (MRI and Histopathological) was not as strong as the other two dimensions and this variation will be analyzed in the discussion section. This is also seen when comparing the box plots between the tumors depth two techniques applied (figure 3B) and the other figures of the other two dimensions (1B and 2B)

Finally the overall volume of the tumor was measured and correlated between MRI images and Histopathology. Regarding the tumor volume, the histopathological volume was estimated from the three dimensions included in the

pathologists report (since it was all available) and in MRI it was measured from a number of slices depending on the size of the tumor, and that because it was a retrospective study and there was no fixed standard tumor thickness. The measured volumes correlations are shown in figures 4 and 5a,b. In figure 4A as in previously described dimensions, at the significance level 0.05 (5%) the paired differences between the values of the Measured Volume and the Histopathological Volume are not significant (t Probability 0.7216). Also there is a very strong linear correlation between the Measured Volume and the Histopathological Volume (Correlation 0.99782) which is well shown in figure 4B (box plot). In figure 5 there is a three dimensional graphing of the tumors volume; in fig a with the MRI measurements and in fig b with the histopathologic results. Basically the figure describes the variation of tumors' Width as a function of their Length with the bubbles volume proportional to the tumors' Depth, thus giving us a 3D image of the tumors dimensions. The results from the paired t tests were confirmed with the non parametric Wilcoxon Rank Sign Test (table 2) for all the data (dimensions if tumor and overall volume measurements).

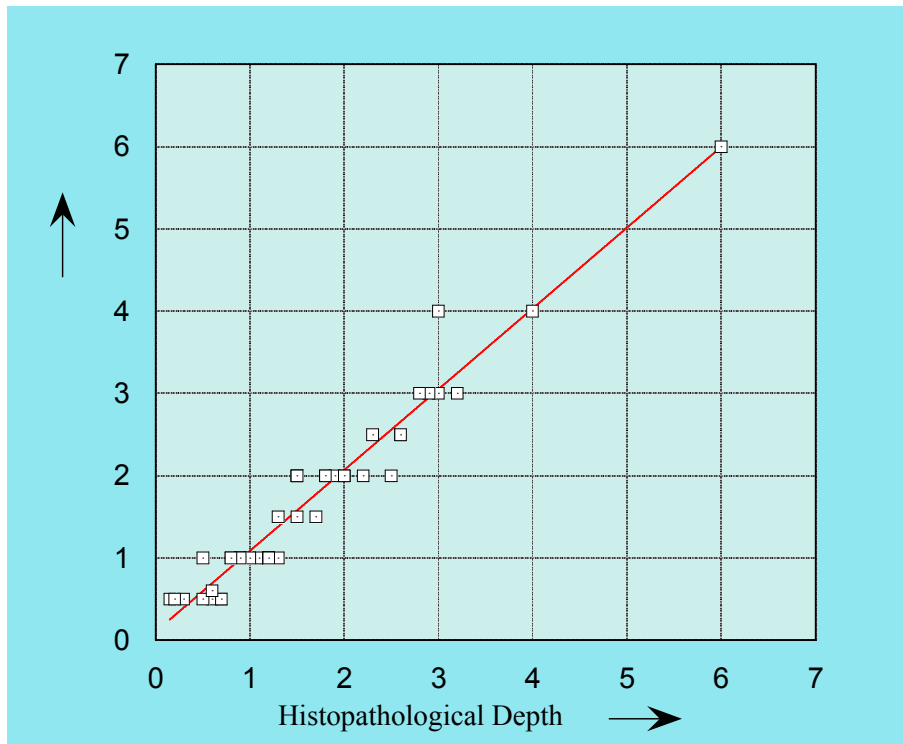


Figure 3. A. Linear correlation between measured and histopathologic depth of tumor.

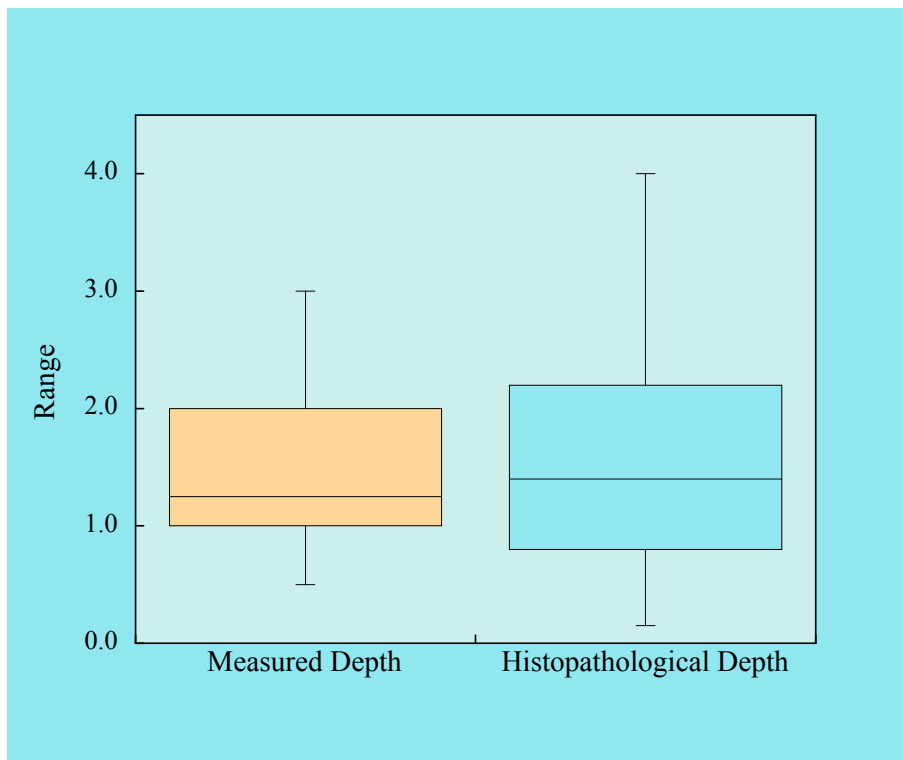


Figure 3. B. Distribution data (boxplots) of the Depth scores obtained by the two Methods.

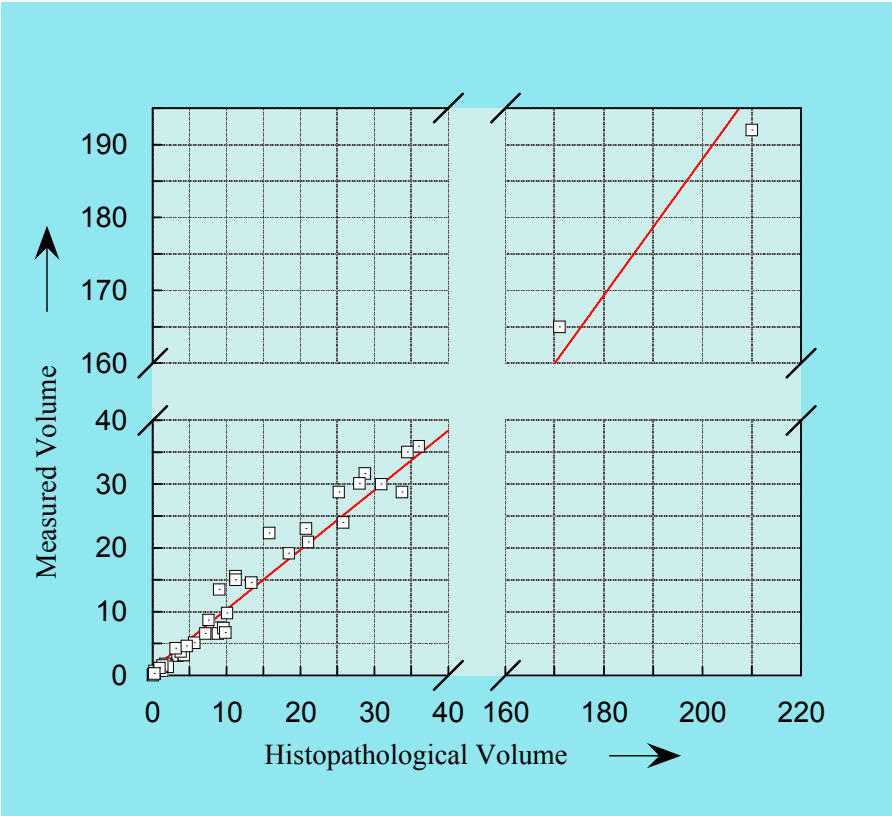


Figure 4. A. Linear correlation between tumors overall volume measured and histopathologic volume.

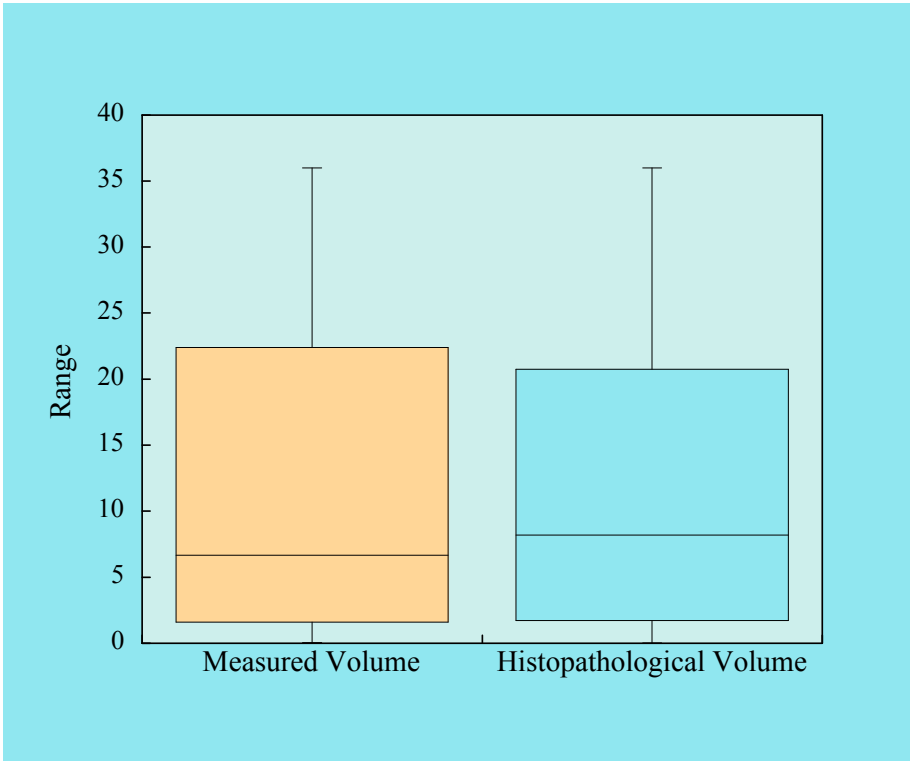


Figure 4. B. Distribution data (boxplots) of the Volume scores obtained by the two Methods.

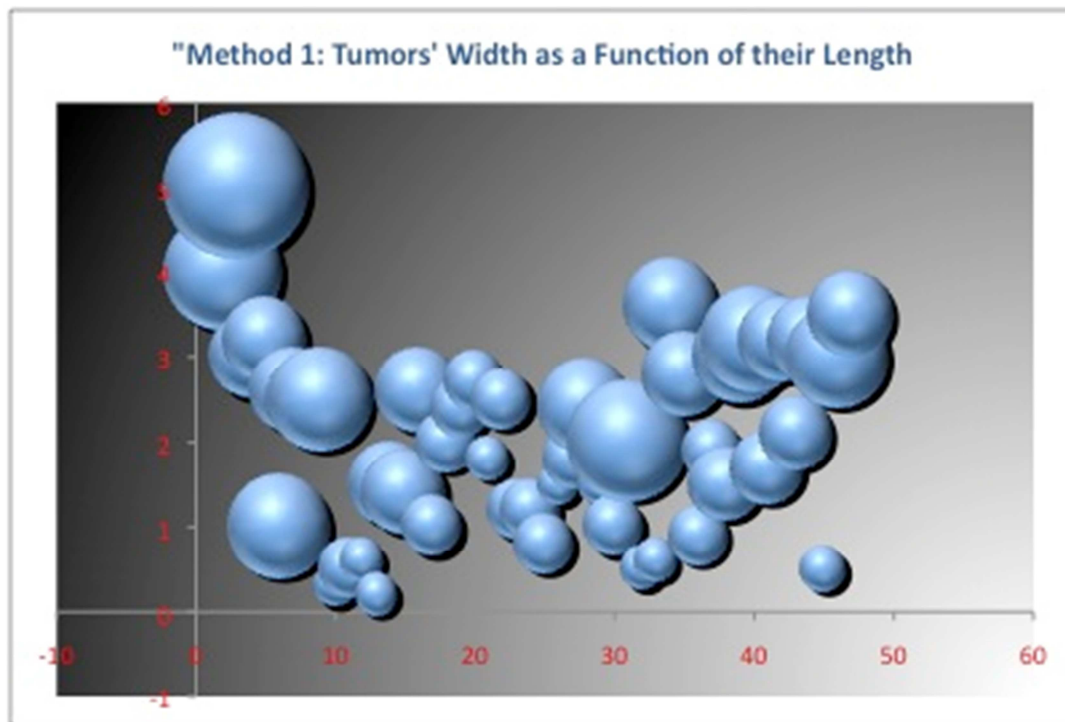


Figure 5. A. Measured dimensions of Tumors. Variation of tumors' Width as a function of their Length. The bubbles' volume is proportional to the tumors' Depth.

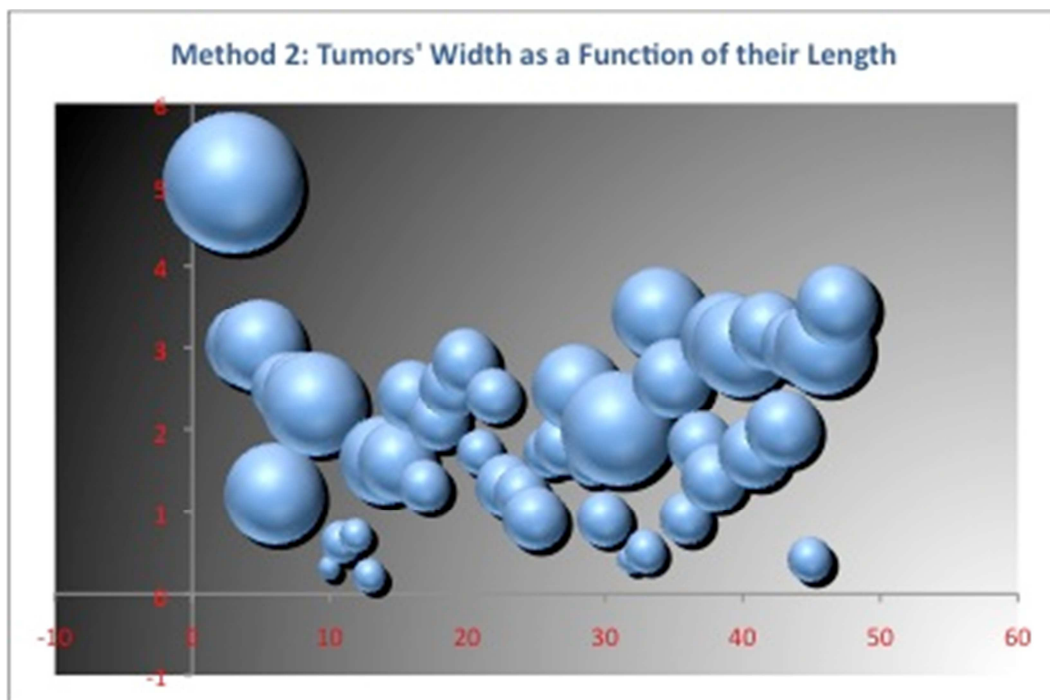


Figure 5. B. Dimensions of Tumors determined from the histopathological samples. Variation of tumors' width as a function of their Length. The bubbles' volume is proportional to the tumors' depth.

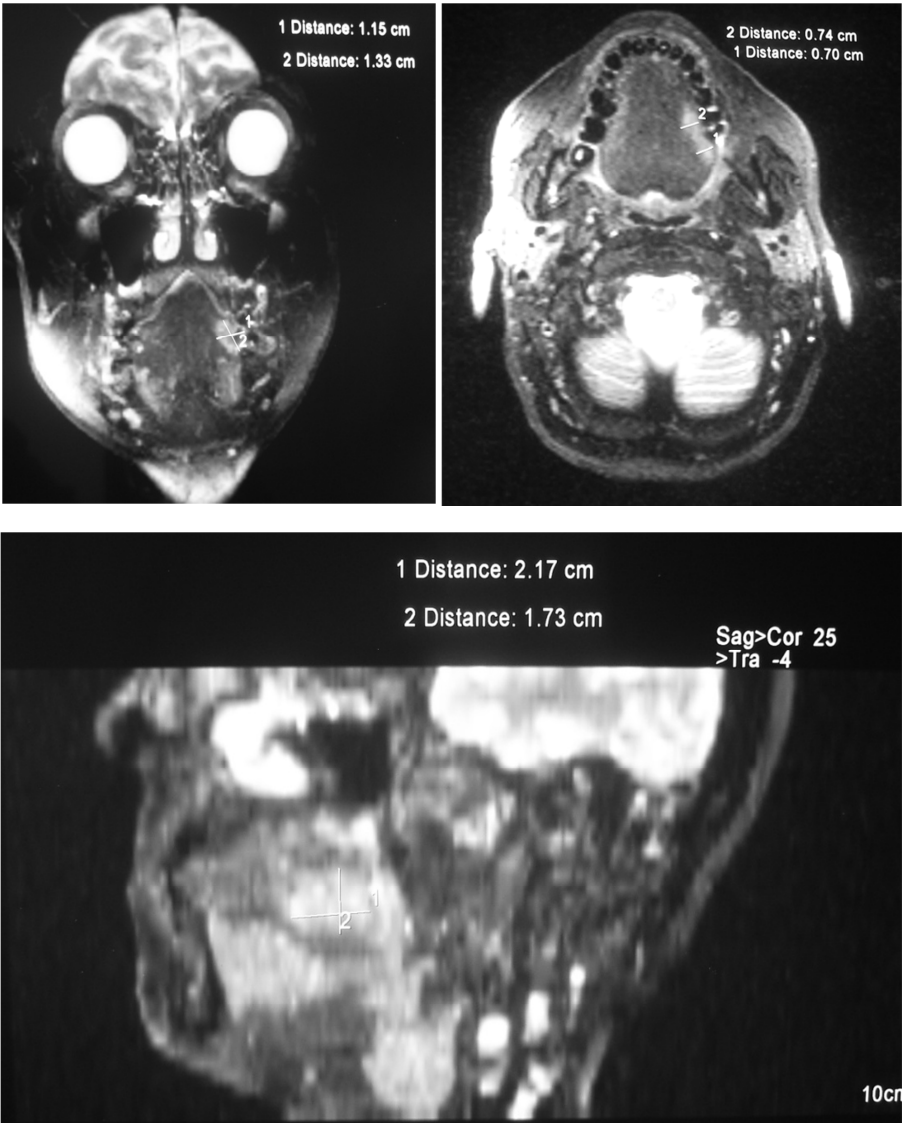


Figure 6. An example of the measured distances in various MRI sections (coronal, horizontal and sagital). Note the difference in image quality between the reconstructed sagital image and the other two, which accounts for the difficulty in MRI measurement of tumor’s depth.

Table 2. Wilcoxon Rank Sign Test for paired data.

	Length	width	Depth	Volume
P value	0,3108	0,8219	0.1096),8709

Since there were only 27 cases amongst the patients’ files that had both T1 and T2 images while all cases had T1 images (anatomical images) and being a retrospective study there was no comparison made between the two imaging modalities.

4. Discussion

MRI is the method of choice regarding soft tissue imaging and therefore tumor measurements. The advantages of MRI are based on its excellent soft tissue contrast which permits easy differentiation of tumorous lesions from the surrounding structures [1]. In MRI dense bone or dental fillings like gold and amalgam cause no artifacts, allowing the depiction of

small tumors in the oral cavity. Imaging in all anatomical planes is also possible without having to move the patient allowing for the evaluation of all tumors dimensions as well as the spread of the tumors to the adjacent structures which is highly important for establishing the prognosis of the operation and the five year life expectancy of the patient.

The normal structure of the tongue is clearly visible in all MRI sequences [11]. This is why no calculations were made according to MRI sequence in the present study. Also the fact that the images were not all taken by the same examiner, or even using the same MRI machine, but were images obtained from patients records made it very difficult for such a comparison.

There have been studies measuring the tumors dimensions

in cases of tongue cancer before surgery [2-4, 8] but to our knowledge there have been no studies correlation the volume of tumor from MRI images to the pathology.

In the present study the measurements performed demonstrated the high accuracy of MRI in presurgical evaluation of tumors of the tongue. The tumors length and width were easier to measure, since they are easily obtained in horizontal sections while the tumors depth were not as always easy to measure since in many cases the images supplied in the patients records were not in digital format, thus not allowing for the reconstruction of the images to parasagittal sections which give a better imaging of tumor depth. In the cases where sagittal images were available, the depth measurement was established by digitizing the images and measuring the third dimension (figure 6). In the cases where sagittal images were not available the tumors depth was estimated from the number of sections the tumor was visualized and the distance between the sections available.

The correlations obtained from the tumors dimensions' measurements, was high compared to histopathology. This is partly due to the accuracy of the technique in tumor imaging and partly due to the accuracy of the measurements performed which was made easy by the current technology (digitization of images with high accuracy and measurements of tumors with high accuracy).

MRI has been shown to be the imaging method of choice in tumor diagnosis. It has been reported that the use of Gd-DTPA and/or fat suppression techniques can improve tumor detectability [12-17]. When it comes to small size tumors MRI has been proven the best technique available. The requirements for accurate measurement of the thickness of carcinomas of the tongue are the ability first, to delineate the lesion in detail and second, to measure the thickness to a precision of 0.1 mm. Conventional MRI does not comply with the requirements [18] though it is the best technique available.

Our study demonstrated the excellent correlation of MRI measurements compared to pathology (gold standard).

The goal of presurgical imaging (particularly with MRI which has a high soft tissue contrast is to establish

- the location
- the size
- the extend
- tumor margins
- tumor spread across the midline
- tumor thickness
- spread in adjacent muscles of the tongue

This is achieved with current MRI imaging and provides adequate information for the surgeon as is proven by our study. MRI should be the method of choice in tumor imaging in cases of tongue carcinomas. This is suggested from our study and is with agreement of numerous studies that have been made in the past for MRI evaluation of tongue cancer [1, 9-11].

The sequence of MRI used for the measurements of tumor dimensions is of high significance since there have been studies that show the differences between the sequences used.

Lam et al (20) mention that the radiologically determined thickness measured on both T1- and T2-weighted images had a strong positive correlation with the histologically determined thickness with T1 images having a higher correlation than T2 images. In their study thickness is what Jung et al [19] and the authors of the present study measure as tumor depth.

The results found in the present study are well related to similar results by a number of authors where there is agreement that there is very good correlation between T1 and T2 weighted images and histopathological measurements with T2 images presenting slightly larger in size when compared to T1 images since the borders might include peritoneal inflammation and edema as high signal intensity [19, 20]. Though no analysis was made according to imaging modalities and a comparison amongst them, the total number of images included in the study shows a very high correlation between imaging technique and histopathology. The images that were used for the study were T1 images since they were available in all the patients' files while T2 images were limited to a smaller number of cases and were therefore not included

5. Conclusions

The tumors dimensions and volume are accurately measured with MRI and provide all the necessary information the surgeon needs to proceed with surgery. Other authors agree to that such as Chew et al [21]. Therefore we can conclude that MRI is efficient as a method for estimating the accurate tumors dimensions prior to surgery in patients with tongue cancer.

Acknowledgements

The authors would like to thank the Greek State Scholarship Foundation that funded the above research.

References

- [1] Lenz M., Greess H., Baum U., Dobritz M., Kersting-Sommerhoff B. Oropharynx, oral cavity, floor of the mouth: CT and MRI. *European Journal of Radiology* 2000; 33: 203-215.
- [2] Lufkin RB, Wortham DG, Dietrich RB, Hoover LA, Larsson SG, Kangaroo H, et al. Tongue and oropharynx: findings on MR imaging. *Radiology* 1986; 161: 69 ± 75.
- [3] Nathanson A., Aegren K., Bioerklund A., Lind MG., Andreason L., Anniko M., et al. Evaluation of some prognostic factors in small squamous cell carcinoma of the mobile tongue: a multicenter study in Sweden. *Head Neck* 1989; 11: 387-392.
- [4] Fukano H, Matsuura H, Hasegawa Y, Nakamura S. Depth of invasion as a predictive factor for cervical lymph node metastasis in tongue carcinoma. *Head Neck* 1997; 19: 205-210.

- [5] Byers RM, El-Naggar AK, Lee Y, Rao B, Fornage B, Terry NHA, et al. Can we detect or predict the presence of occult nodal metastases in patients with squamous cell carcinoma of the oral tongue? *Head Neck* 1998; 20: 138-144.
- [6] Asakage T, Yokose T, Mukai K, Tsugane S, Tsubono Y, Asai M, et al. Tumor thickness predicts cervical metastasis in patients with stage I/II carcinoma of the tongue. *Cancer* 1998; 82: 1443-1448.
- [7] Spiro RH, Spiro JD, Strong EW. Surgical approach to squamous carcinoma confined to the tongue and the floor of the mouth. *Head Neck Surg* 1986 ;9: 27-31
- [8] Hicks WL Jr, North JH Jr, Loree TR, et al. Surgery as a single modality therapy for squamous cell carcinoma of the oral tongue. *Am J Otolaryngol* 1998 ;19: 24-28
- [9] Sigal R, Zagdanski AM, Schwaab G, et al. CT and MR imaging of squamous cell carcinoma of the tongue and floor of the mouth. *RadioGraphics* 1996 ;16: 787-810
- [10] Tomura N., Watanabe O., Kato K., Takahashi S., Watarai J., Sageshima M., Yokomizo M. Irradiated Carcinoma of the Tongue: Correlation of MR Imaging Findings with Pathology
- [11] Sobin LH, Wittekind C. (International Union Against Cancer [UICC]), eds. TNM classification of malignant tumours , 5th ed. Baltimore: Wiley- Liss, 1997: 20-24
- [12] Vogl T, Bruening R, Grevers G, Mees K, Bauer M, Lissner J. MR imaging of the oropharynx and tongue: comparison of plain and Gd-DTPA studies. *J Comput Assist Tomogr* 1988; 12: 427-433.
- [13] Crecco M, Vidiri A, Palma O, Floris R, Squillaci E, Mattioli M, et al. T stages of tumors of the tongue and floor of the mouth: correlation between MR with gadopentetate dimeglumine and pathologic data. *Am J Neuroradiol* 1994; 15: 1695-1702.
- [14] Yasumoto M, Shibuya H, Takeda M, Korenaga T. Squamous cell carcinoma of the oral cavity: MR findings and value of T1- versus T2-weighted fast spin-echo images. *AJR Am J Roentgenol* 1995; 164: 981-987.
- [15] RossMR, Schomer DF, Chappell P, Enzmann DR. MR imaging of head and neck tumors: comparison of T1-weighted contrast- enhanced fat-suppressed images with conventional T2-weighted and fast spin-echo T2-weighted images. *AJR Am J Roentgenol* 1994; 163: 173 -178.
- [16] Tein RD, Hesselink JR, Chu PK, Szumowski J. Improved detection and delineation of head and neck lesions with fat suppression spin-echo MR imaging. *Am J Neuroradiol* 1991; 12: 19-24.
- [17] Barakos JA, Dillon WP, Chew WM. Orbit, skull base, and pharynx: contrast-enhanced fat suppression MR imaging. *Radiology* 1991; 179: 191-198.
- [18] Shintani S, Nakayama B, Matsuura H, Hasegawa Y. Intraoral ultrasonography is useful to evaluate tumor thickness in tongue carcinoma. *Am J Surg* 1997; 173: 345-347.
- [19] J. Jung, N. H. Cho, J. Kim, E. C. Choi, S. Y. Lee, H. K. Byeon, Y. M. Park, W. S. Yang, S.-H. Kim. Significant invasion depth of early oral tongue cancer originated from the lateral border to predict regional metastases and prognosis. *Int. J. Oral Maxillofac. Surg.* 2009; 38: 653-660
- [20] Lam P, Au-Yeung KM, Cheng PW, Wei WI, Yuen AP, Trendell-Smith N, Li JH, Li R. Correlating MRI and histologic tumor thickness in the assessment of oral tongue cancer. *AJR Am J Roentgenol.* 2004 Mar;182(3):803-8.
- [21] Chew MH1, Khoo JB, Chong VF, Tai BC, Soo KC, Lim DT. Significance of tumour volume measurements in tongue cancer: a novel role in staging. *ANZ J Surg.* 2007 Aug;77(8):632-7.