

Case Report

Male's Primary Breast Lymphoma: Rare Entity of Breast Malignancy, Wad Madani Teaching Hospital, Gezira State, Sudan, August 2023

Omer Taha Ahmed Elmukashfi^{1,*} , Taha Ahmed Elmukashfi Elsheikh², Ahmad Alamin Alshaikh³, Afnan Abdelrahman Elsiddig Dafalla⁴, Wala Osman Eltieb Omer¹, Asma Mohammed Warrag Omer⁵, Osman Elfatih Elheber Omer¹, Eman Ali Ahmed Mohamed³, Osman Merghani Osman Mahmoud⁶

¹General Surgery Council, Sudan Medical Specialization Board, Khartoum, Sudan

²Department of Community Medicine, Faculty of Medicine, University of Khartoum, Khartoum, Sudan

³Department of General Surgery, Faculty of Medicine, University of Gezira, Wad Madani, Sudan

⁴Department of Training, Federal Ministry of Health, Khartoum, Sudan

⁵National Cancer Institute (NCI), University of Gezira, Wad Madani, Sudan

⁶Department of General Surgery, Fajer Medical College, Khartoum, Sudan

Abstract

Background: Primary breast lymphoma is a malignant lymphoma primarily involving breast in absence of previously detected lymphoma localizations. **Method:** A male of forty years old admitted to Department of Surgery; Wad Madani Teaching Hospital; Gezira State; Sudan; complaining of left breast lump for three months. Condition observed as a painful swelling in left breast, increasing gradually in size, associated with continuous high-grade fever, no rigors and relieved by analgesia, no nipple discharges. Had significant weight loss, anorexia, fatigability, back pain, dry cough with no hemoptysis, no history of headache, and no past or family history of similar condition. Examination: patient looks ill, pale, and not jaundiced. Breast examination: Left breast was larger than right one. Left breast: no nipple destruction, nipple was directed downward medially, no skin changes or dimpling, and no ulceration. There was a mass in left upper outer quadrant, measuring 6*7 cm, smooth surface, hard in consistency with well-defined edges, and attached to muscles but not to skin. No palpable axillary lymph nodes. Right breast was normal. Chest and abdominal examination were unremarkable. Investigations: Fine needle aspiration cytology showed poorly differentiated carcinoma. Incisional biopsy revealed: high grade Non-Hodgkins Lymphomas (Diffuse Large B Cell Lymphoma). He was referred to oncological department for neoadjuvant chemoradiotherapy. **Conclusion and Recommendation:** Primarily breast lymphoma is extremely rare among male, showing features mimicking breast carcinoma. Incisional biopsy was recommended for investigation of breast lump especially among males.

*Corresponding author: Omertaha94@gmail.com (Omer Taha Ahmed Elmukashfi)

Received: 27 December 2023; **Accepted:** 6 January 2024; **Published:** 27 February 2024



Copyright: © The Author(s), 2023. Published by Science Publishing Group. This is an **Open Access** article, distributed under the terms of the Creative Commons Attribution 4.0 License (<http://creativecommons.org/licenses/by/4.0/>), which permits unrestricted use, distribution and reproduction in any medium, provided the original work is properly cited.

Keywords

Primary Breast Lymphoma Among Male, Wad Madani Teaching Hospital, Gezira State, Sudan

1. Introduction

Extra-nodal diseases refer to any lymph node involvement of the lymphatic system in other tissues, such as the central nervous system, lungs, bones, skin and stomach, it can involve the breast mimicking the breast carcinoma [1]. Breast lymphoma (BL) is a rare form of extra-nodal lymphoma (ENL), it accounts for the most common extramammary cancer involving the breast. It is classified into primary breast lymphoma (PBL) and secondary breast lymphoma (SBL) types. Primary breast lymphoma (PBL); is defined as a malignant lymphoma primarily involving the breast in the absence of previously detected lymphoma localizations. SBL is defined by the presence of secondary involvement of breast tissue by a concurrent or previous systemic lymphoma and is more common than PBLs [2-7]. PBL is characterized by primary degeneration of the breast lymphoid tissue with or without damage to the lymph nodes in the drainage area. In 1972, Wiseman and Liao defined PBL on the basis of three precise criteria: (1) Presence of mammary glandular tissue in the middle of the lymphomatous infiltrate or in its direct contact, detected by a good quality sample; (2) The absence of systemic metastases in the extension assessment; (3) The absence of a history of extra mammary lymphoma. [8]. More than 80% of PBL are B-cell lymphomas, mostly CD20+. The most common histopathological types are: diffuse large B-cell lymphoma (DLBCL), which accounts for up to 50% of all PBL, follicular lymphoma (FL) – 15%, MALT lymphoma – 12.2%, Burkitt's lymphoma (BL) and Burkitt-like lymphoma – 10.3%. Other histological types of PBL include marginal zone lymphoma (MZL), small lymphocytic lymphoma (SLL), and anaplastic large cell lymphoma (ALCL), Burkitt's lymphoma is mainly associated with pregnant or lactating women and HIV- seropositive patients [3, 6, 7, 9].

Primary breast lymphoma (PBL) is a rare type of breast lymphoma, account for 0.5% of breast malignancies, around 1% of all non-Hodgkin lymphoma (NHL) and <3% of extra-nodal lymphomas. It is very rare in male while it mainly presents in female patients, accounting for 95%–100%, and commonly occurs from 60 to 65 years; with 50% recurrence rate. Bilateral breast involvement accounts for 11% of all breast lymphomas. Primary breast lymphoma has no clinical and radiological features and present similar to breast carcinoma. It can present with painless lump usually in the upper outer quadrant, and may be associated with local pain and inflammation and sometimes may present with palpable lymph nodes [2-13, 15].

The diagnosis is mainly made by surgical biopsy. Surgery, radiotherapy and chemotherapy are the most commonly used

treatment modalities [2-5, 9, 11, 13]. The outcome of PBL is worse than epithelial breast cancer. The 5-year survival rate and recurrence rate are 40–80% and 15% for the PBL, while for Breast cancer the survival rate and recurrence rate at 10 years are 89% and 12%; respectively [2]. To date, less than 50 cases of male breast lymphoma have been reported in the literature. [14].

2. Case Report

Forty years old male work as farmer with free medical background admitted to the Department of Surgery; Wad Madani Teaching Hospital; Gezira State; Sudan; August 2023, complaining of left breast lump for 3 months. The condition observed three months ago as painful swelling in his left breast which increases gradually in size, associated with continuous high-grade fever with no rigors and relieved by analgesia. He had no nipple discharge neither history of trauma. There is no other swelling through his body. He had significant weight loss, anorexia, and fatigability which interfere with his normal activity. He had back pain and dry cough with no hemoptysis, no history of headache, blurred of vision, no history of yellowish discoloration of sclera. He has no past history of similar condition, no history of hospitalization, no family history of similar condition, no history of breast, GIT malignancies. On examination: patient looks ill, pale, not jaundiced, PR: 88 b/m, RR: 24 c/m, BP: 120/90 mm/hg, T: 38.2 c. Breast Examination: the left breast was larger than the right one. Regarding to the left breast; no nipple destruction, the nipple was directed downward medially, no skin changes or dimpling, no ulceration. There was a mass in the left upper outer quadrant, about 6*7 cm smooth surface, hard in consistency with well-defined edges, attached to muscles not to skin. There were no palpable axillary lymph nodes. Regarding right breast; it was normal. Chest and Abdominal examination were unremarkable. Investigations: CBC: WBCs: 14.8*10⁹ /l, HB: 7.6 g/dl, Plt: 35 *10⁹/l, RFT+ Electrolytes: Blood Urea: 41 mg/dl, Serum Creatinine: 3.2 mg/dl, Serum Na: 133 mg/dl, Serum K: 2.6 meq/l, FNAC: malignant cytology lymphoma or poorly differentiated carcinoma. Patient underwent incisional biopsy which revealed: high grade Non-Hodgkins Lymphomas (Diffuse Large B Cell Lymphoma), [Figure 1](#). Then he was referred to oncological department for neoadjuvant chemoradiotherapy.

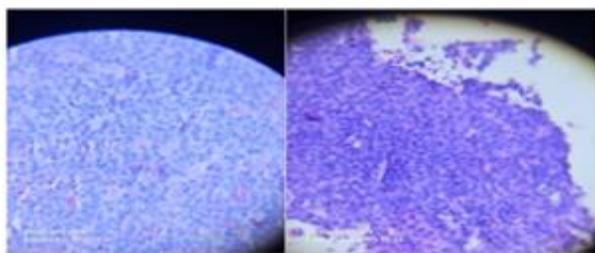


Figure 1. Primary Breast Lymphoma (DLBCL), sections show diffuse growth of monotonous atypical lymphocytes having medium to large size nuclei, prominent nucleoli, scanty cytoplasm with irregular nuclear membrane, high mitotic index.

3. Discussion

This was an extremely rare case of male's primary breast lymphoma which was inconsistent with many international studies [3, 4, 7]. Our case present with breast lump in the left upper outer quadrant associated with pain; this was similar to other case reports [3-5]. The presentation of our case was mimicking breast carcinoma which was similar to many worldwide case reports [1, 2, 4, 5, 9, 11]. The histological type of our case was diffuse large B cell lymphoma like many studies [3, 6, 7, 9]. Our case was diagnosed through FNAC and confirmed by incisional biopsy, then referred for neoadjuvant chemoradiotherapy, this was consistent with the literatures [2-5, 9, 11, 13].

4. Conclusion and Recommendation

Rarely, primarily breast lymphoma can occur among male, showing features mimicking breast carcinoma. Incisional biopsy was recommended for investigating any suspicious breast lump in females and especially males.

Conflicts of Interest

The authors declare no conflict of interest.

References

- [1] Heinzen R N, et al, Primary Breast Lymphoma Presenting as Locally Advanced Breast Cancer: A Case Report, *Mastology*, 2017, 27(2), pp: (152-155).
- [2] Orlandi A, et al, Diagnosis and management of breast lymphoma: a single-institution retrospective analysis, *Transl Cancer Res*, 2018, 7(3), pp: (S272-S280).
- [3] Joks M, Myśliwiec K, Lewandowski K, Primary breast lymphoma – a review of the literature and report of three cases, *Arch Med Sci* 2011, 7(1), PP: (27-33).
- [4] Sonkaria M, et al, Primary breast lymphoma: A case series and review, *Indian J Case Reports*, 2020, 6(6), pp: (288-291).
- [5] Guo M, Liu J, Gilmore R, Tian G G, Primary breast diffuse large B cell lymphoma, *BMJ Case Rep* 2022, 15: e250478. <http://doi.org/10.1136/bcr-2022-250478>
- [6] Mohamed K. E. H, Ali R. A. E, Primary breast lymphoma: a case report and review of the literature, *Clinics and Practice* 2017, 7(939), PP: (99-100).
- [7] Cheah C Y, Campbell B A, Seymour J F, et al, Primary breast lymphoma, *Cancer Treat Rev* 2014, <http://dx.doi.org/10.1016/j.ctrv.2014.05.010>
- [8] Taheri H, Hmila A, Saadi H, Mimouni A, Primary breast lymphoma: a case report, *Int J Reprod Contracept Obstet Gynecol*. 2020, 9(5), pp: (2187-2190).
- [9] Corobea A B, et al, Diffuse Large B Cell Lymphoma in a Male Breast – A Rare Case Report, *Chirurgia* 2017, 112, pp: (477-481).
- [10] Earnest R E, Downey D M, Fox J P, McKellar D P. Recurrence of Primary Breast Lymphoma in Contralateral Breast: Case Report and Review of the Literature, *Journal of Surgical Education*, 2008, 65(5), PP: (364-366).
- [11] McFarlane M, and Coard K, Primary Breast Lymphoma: Case Report of a Rare Pathological Entity, *European Journal of Medical and Health Sciences*, 2020, 2(3), pp: (1-3).
- [12] Melo T, Abreu E M, Primary Breast Lymphoma – Case Report, *ACTA RADIOLÓGICA PORTUGUESA*, 2022, 34(1), pp: (25-27).
- [13] Karagöz B, et al, Primary Breast Lymphoma Treated with R-CHOP Chemotherapy, *Eur J Gen Med* 2009, 6(3), pp: (187-188).
- [14] Elgaafary S, et al, Double-hit lymphoma of the male breast: a case report, *Journal of Medical Case Reports*, 2020, 14(245), pp: (1-4).
- [15] Yim B, et al, Primary Breast Lymphoma in an Immunocompromised Male Patient: A Case Report, *J Korean Soc Radiol*, 2015, 73(4), pp: (264-268).