





















Review Article

# Periventricular and Intraventricular Tumors in a Low-Income Country: Hard Learning Curve and Outcome of a Young Neurosurgeon from Burkina Faso

**Ibrahim Dao<sup>1, 2, 3, \*</sup>** , **Aminata Ki èntor é<sup>4</sup>** , **Ousmane Ouattara<sup>1</sup>** , **Fr é l é r i c B a k o<sup>4</sup>** , **Jacques Traor é<sup>4</sup>** , **Joseph Biogo<sup>4</sup>** , **Serge Pac ô m e Yameogo<sup>4</sup>** , **Abdoulaye Sanou<sup>4</sup>** , **Eustache Kienou<sup>4</sup>** , **Louis Junior Comboigo<sup>4</sup>** , **Ars è n e Tossou<sup>4</sup>** , **Abdoulaye Thiombiano<sup>4</sup>** , **Lassan é Taoko<sup>4</sup>** , **Henry Lankoand é<sup>4</sup>** , **Elie Nassoum<sup>4</sup>** , **Narcisse Ou é draogo<sup>1</sup>** , **Sosth è n e Fawaz Ad é n i r a n<sup>4</sup>** , **Astride Somda<sup>4</sup>** , **Delwend é Sylvain Zabsonr é<sup>4</sup>** , **Abel Kabr é<sup>4</sup>** 

<sup>1</sup>Department of Orthopaedic Surgery, Souro Sanou University Hospital, Bobo Dioulasso, Burkina Faso

<sup>2</sup>Military Hospital Colonel Major Tanguet Ouattara, Bobo Dioulasso, Burkina Faso

<sup>3</sup>Higher Institute of Health Sciences, Nazi Boni University, Bobo Dioulasso, Burkina Faso

<sup>4</sup>Department of Neurosurgery, Yalgado Ouedraogo University Hospital, Joseph KI-Zerbo University, Ouagadougou, Burkina Faso

## Abstract

**Background:** Periventricular and Intraventricular processes are life-threatening conditions because of their propensity to obstruct Cerebrospinal fluid pathways and to compress highly functional and vital structures. There are deep-seated lesions requiring rigorous microsurgical technic for their resection. **Methods:** We retrospectively analyzed the profile and outcome of Periventricular and intraventricular processes operated by the same author since his return in his country in 2015, after graduated abroad in WFNS Rabat training center program 2023. **Result:** We defined 15 patients operated over 8 years. There were 4 processes in lateral ventricle (26.6%), 1 in third ventricle (6.6%), 2 thalamus processes (13.3%), 4 in fourth ventricle (26.6%) and finally 4 in cerebellar hemisphere and violating the fourth ventricle (26.6%). Various surgical approaches were used, such as contralateral interhemispheric transcallosal, classical interhemispheric transcallosal, Subfrontal transbasal translamina terminalis, Frontal Transcortical, Temporal trans T2, ventriculoperitoneal shunting, endoscopy, cerebellar transcortical approach and Telovelar approach. Surgical procedure duration was more than 10 hours in 12 cases (80%) and one third of the patients have been operated in 2018. When neurosurgical operative microscope was not available, ophthalmologic microscope or binocular with headlight were used to achieve the resection. Pathological examination revealed High-grade glioma, subependymal giant cell astrocytoma (SEGA), central neurocytoma, Subependymoma, Hemangioblastoma, pilocytic astrocytoma, Medulloblastoma, gemiocyctic astrocytoma, atypical papilloma of choroid plexus, craniopharygioma and cyst of septum pellucidum. We reported good postoperative outcome in 10 cases (66.6%), moderate postoperative deficit in 1 case and 4 cases of postoperative death (26.6%) among which 3 cases of postoperative meningitis. **Conclusion:** Periventricular and intraventricular processes can be safely approach in low-income country with acceptable result. However young African Neurosurgeon should be

\*Corresponding author: [dao.ibrahim@gmail.com](mailto:dao.ibrahim@gmail.com) (Ibrahim Dao)

**Received:** 10 March 2024; **Accepted:** 26 March 2024; **Published:** 17 April 2024



Copyright: © The Author(s), 2024. Published by Science Publishing Group. This is an **Open Access** article, distributed under the terms of the Creative Commons Attribution 4.0 License (<http://creativecommons.org/licenses/by/4.0/>), which permits unrestricted use, distribution and reproduction in any medium, provided the original work is properly cited.

trained to be comfortable with multiple surgical approaches and also with binocular as well as with microscope. WFNS training program is a strong basement for the take-off of young African neurosurgeon. Backing home should be the rule after training, to develop neurosurgery.

## Keywords

Periventricular, Intraventricular, Tumor, Process, WFNS Rabat Training Center Program

## 1. Introduction

Intraventricular tumors present a unique challenge to neurosurgeon due to their deep location and relationship with vital neural and vascular structures mainly the thalamus, the hypothalamus and their relationship with the internal capsule, the suprasellar region and the great cerebral vein of Galen complex [1]. Moreover, We should also emphasize the floor of the fourth ventricle and Its relationship with the brainstem. This means that intraventricular tumors may extend to these surrounding structures and vice versa. This led us to the word periventricular tumors. Thus, periventricular and intraventricular processes are life-threatening conditions because of their propensity to obstruct Cerebrospinal fluid pathways and to compress highly functional and vital structures [5, 6]. Surgical resection alone or as the first step of multidisciplinary treatment remains a mainstay and should aim a total or maximal removal, while minimizing retraction or damage on normal brain tissue [5, 7].

The management of these intraventricular and periventricular tumors, requires accurate preoperative investigation, rigorous microsurgical technic and appropriate intraoperative and post operative monitoring. Typically, the decision of the surgical approach relies on several factors such as tumor size, location in the ventricular system, presence of hydrocephalus, experience and preference of the surgeon [5, 8]. This study aims to share our experience in the management of periventricular and intraventricular processes in a low-income country with moderate platform. Moreover, We emphasized de clinicopathological feature and outcomes of these processes in our environment.

## 2. Materiel and Methods

We retrospectively analyzed the profile and outcome of Periventricular and intraventricular processes operated by the same author since his return in his country in 2015, after graduated abroad in WFNS Rabat training center program till 2023, in an environment of moderate neurosurgical platform. In our condition, our greatest weapon is an old outdated

neurosurgical microscope, a rigid endoscope and basic MRI images (T1, T2 weighted images, FLAIR and angio MRI). When neurosurgical operative microscope was not available, ophthalmologic microscope or binocular (magnification 3.5) with headlight were used to achieve the resection. Sometimes, even the Mayfield head holder is not available.

## 3. Results

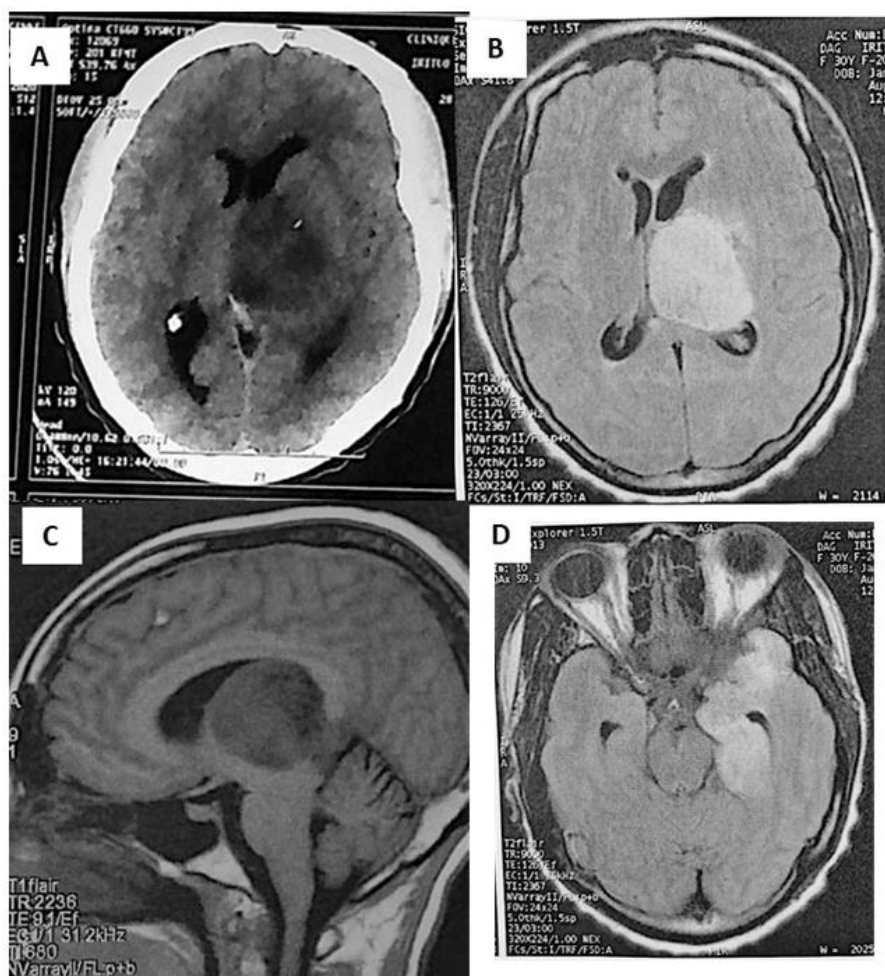
We defined 15 patients operated over 8 years. There were 8 males and the mean age was 19.27 years (from 4 years to 39 years). The paediatric population (less than 15-year-old) represented 7/15 case (46.6%) (Table 1).

There were 3 processes in lateral ventricle (20%), 1 in third ventricle (6.6%), 2 thalamus processes (13.3%), 4 in fourth ventricle (26.6%) and finally 4 in cerebellar hemisphere and violating the fourth ventricle (26.6%) (Figure 9). Various surgical approaches were used, such as contralateral interhemispheric transcallosal, classical interhemispheric transcallosal, Subfrontal transbasal translamina terminalis, Frontal Transcortical, Temporal trans T2, ventriculoperitoneal shunting, endoscopy, cerebellar transcortical approach and Telovelar approach: (table 1).

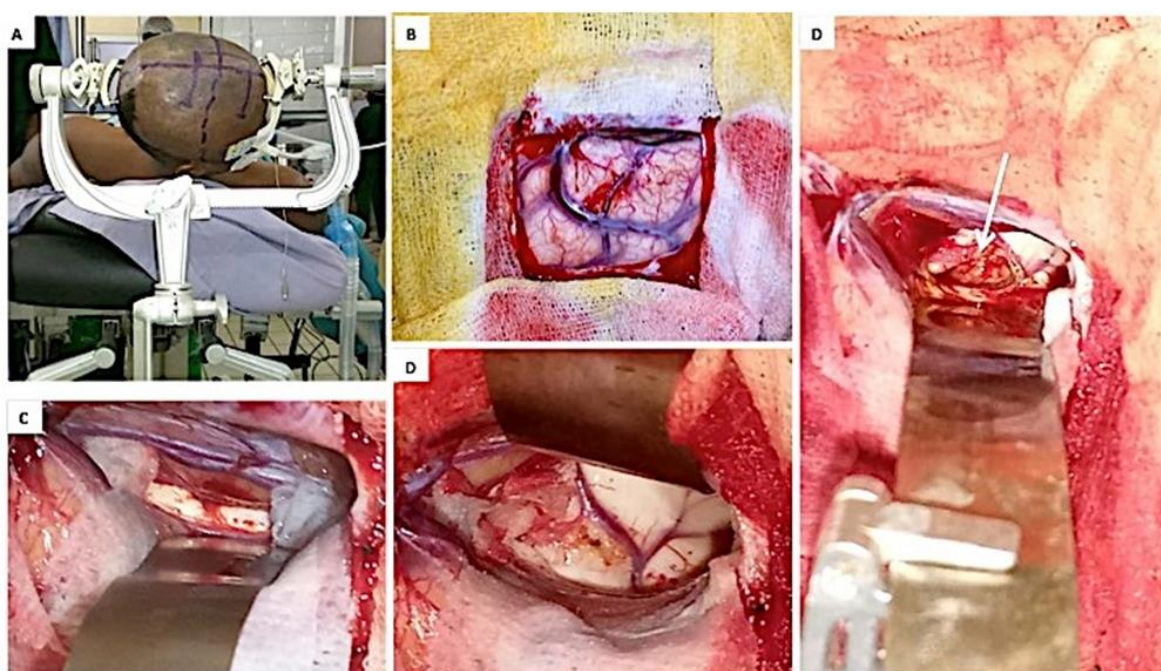
Surgical procedure duration was more than 10 hours in 12 cases (80%) and one third of the patients have been operated in 2018 (Figure 10).

Pathological examination revealed fibrillary astrocytoma (figures 1, 2 and 3), SEGA (Subependymal giant cell astrocytoma), central neurocytoma, Subependymoma, Hemangioblastoma, pilocytic astrocytoma, Medulloblastoma, geminocytic astrocytoma, craniopharyngioma (figures 4, 5 and 6), atypical papilloma of choroid plexus (figure 7), and cyst of septum pellucidum (Table 1).

We reported good postoperative outcome in 10 cases (66.6%); moderate postoperative deficit in 1 case and 4 cases of postoperative death (26.6%) among which 3 cases of postoperative meningitis.

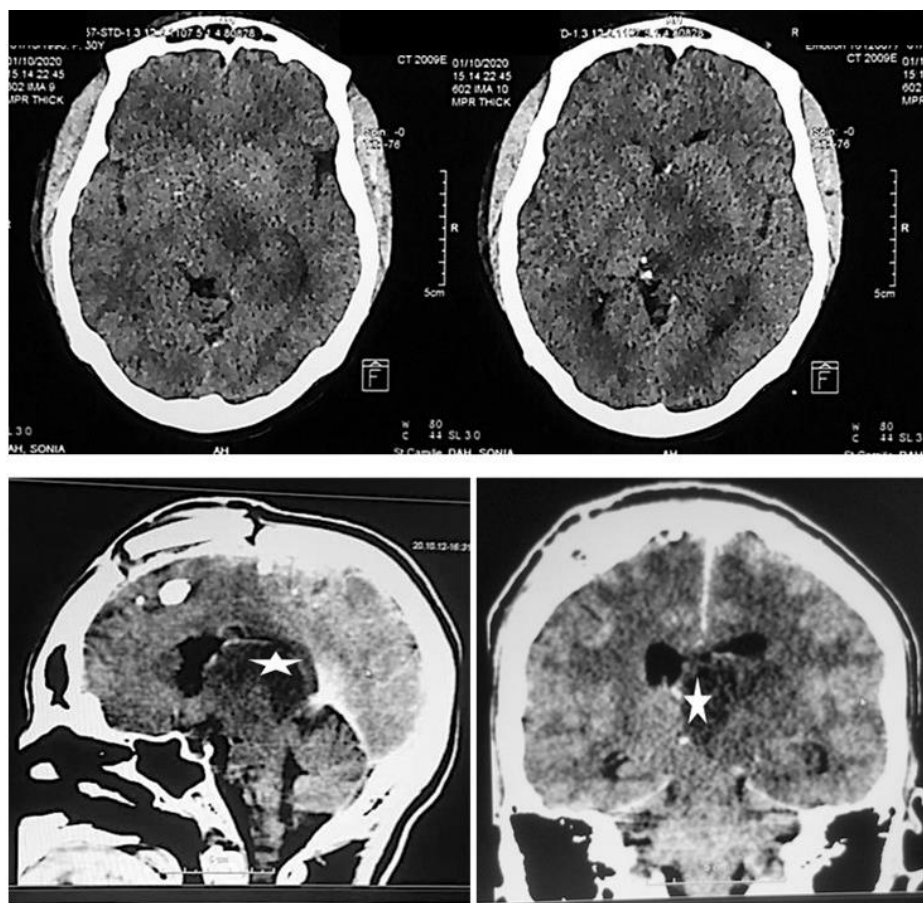


**Figure 1.** (case 10 in the table): Preoperative images: left thalamic glioma.

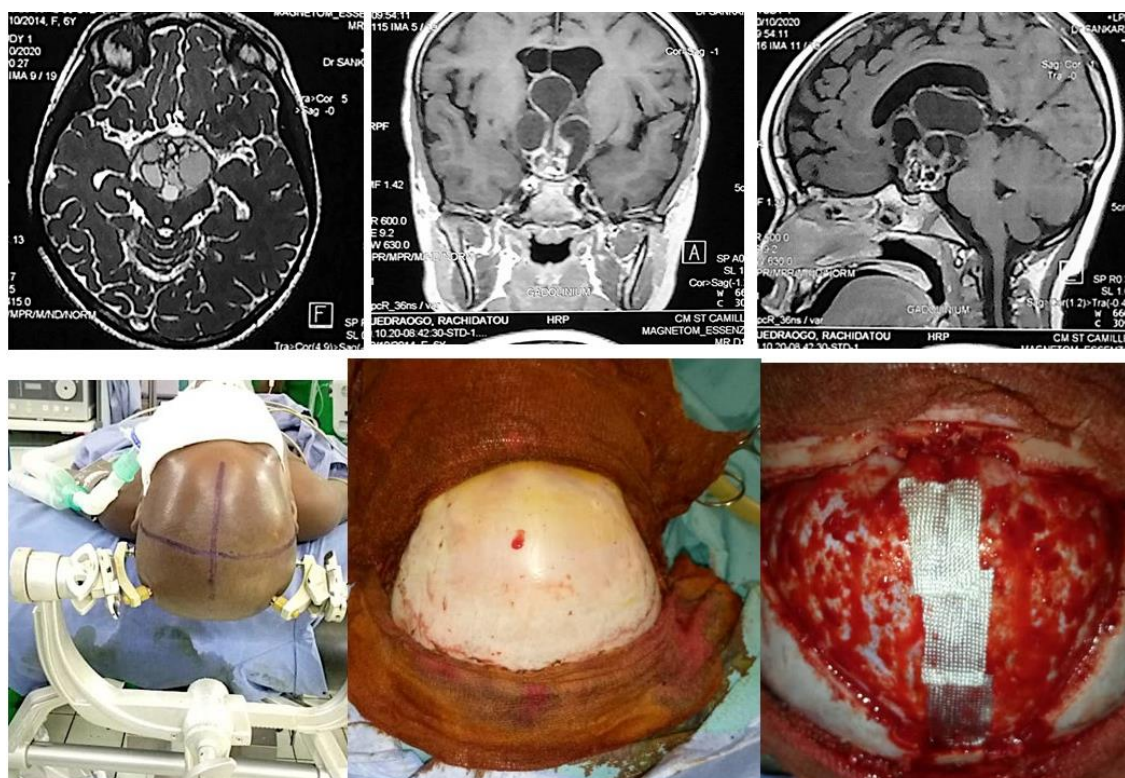


**Figure 2.** (Case 10 in the table): Intraoperative images of left thalamic process: Interhemispheric contralateral approach: position (A), Opening of dura matter (B), interhemispheric approach with exposition of the corpus callosum (C), Callosotomy then exposition of the left thalamus and thalamostriate vein (D: white arrow).

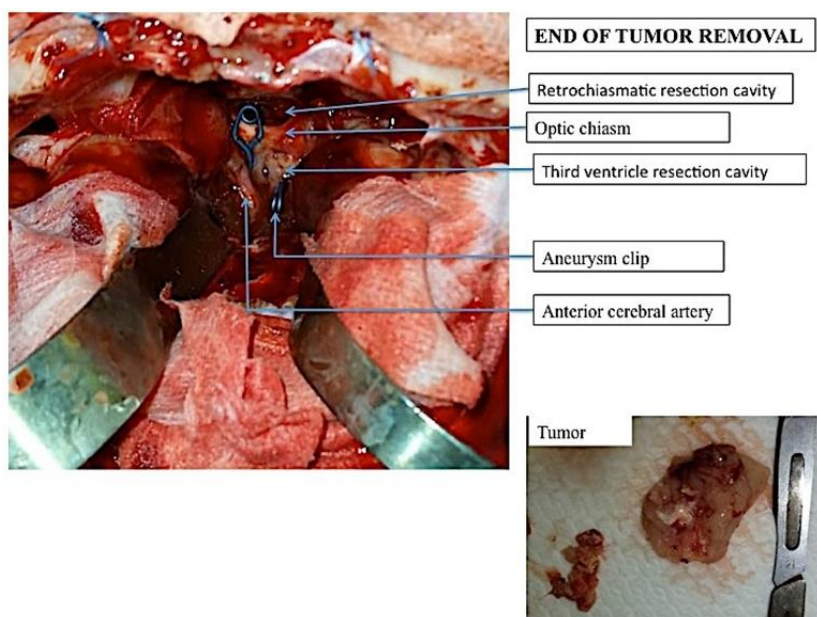




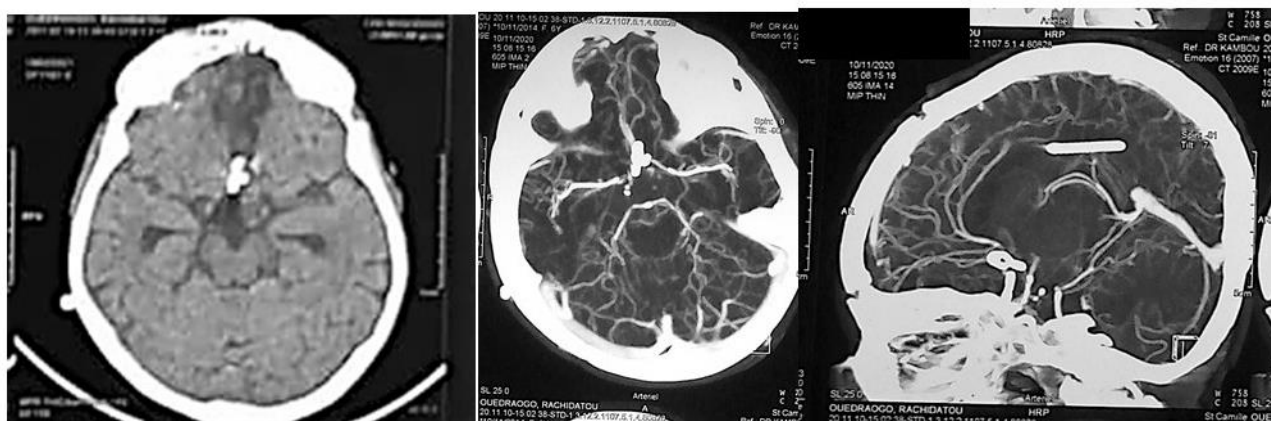
**Figure 3.** (case 10 in the table): Postoperative images: left thalamic glioma (Noticed the resection cavity: white star).



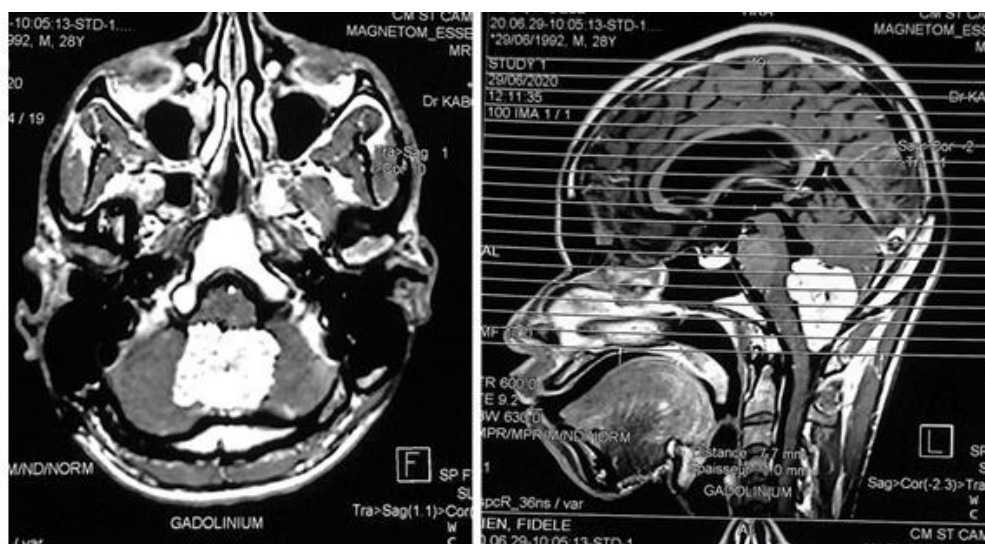
**Figure 4.** (Case 12 in the table): Suprasellar craniopharyngioma extended to V3. Subfrontal transbasal translamina terminalis approach (Middle line images).



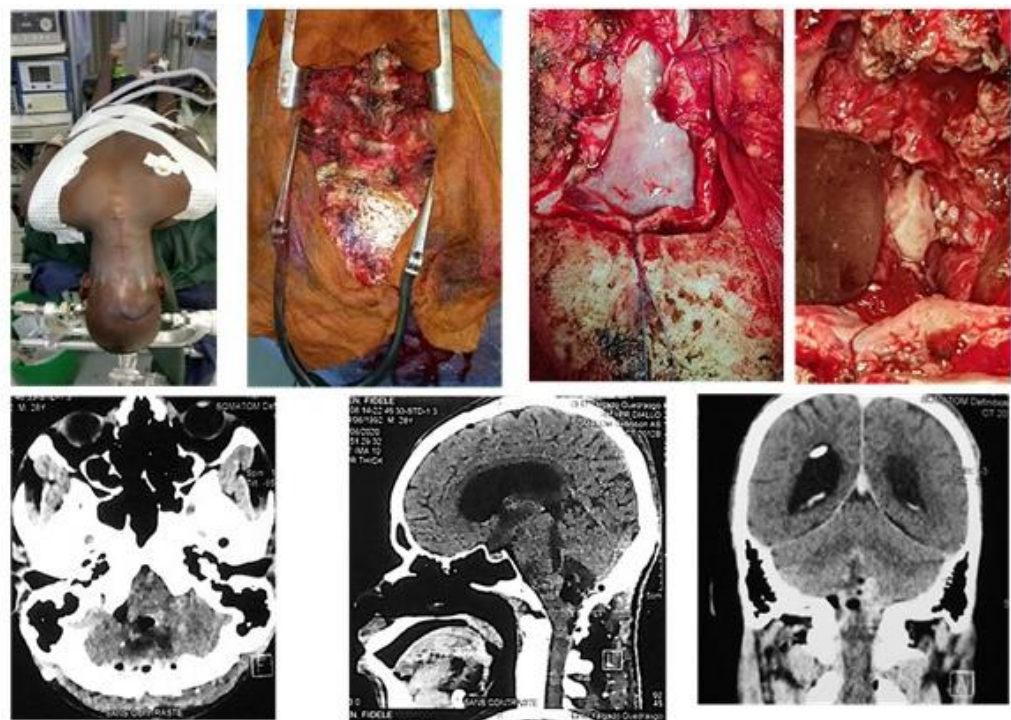
**Figure 5.** (Case 12 in the table): Suprasellar craniopharyngioma extended to V3: intraoperative view after complete removal: incidental rupture of anterior communicating artery (Clipped).



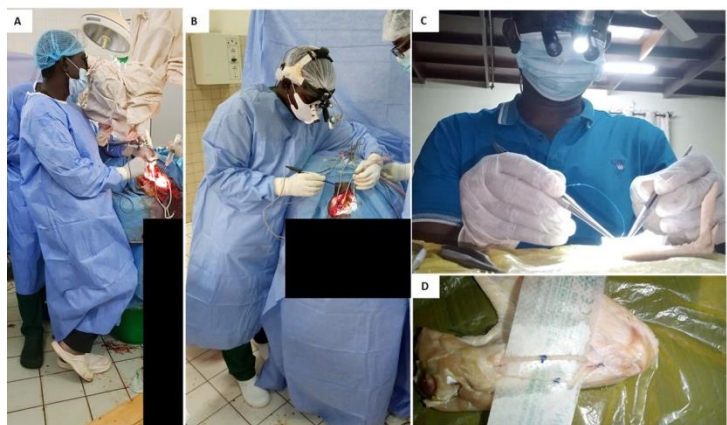**Figure 6.** (Case 12 in the table): Suprasellar craniopharyngioma extended to V3 (Upper line images) Post operative control: Total removal and patency of Willis circle.







**Figure 7.** (Case 7 in the table): Atypic papilloma of choroid plexus of V4: Complete removal through telovelar approach: Note the floor of V4 at the end of the surgery.



**Figure 8.** Our practice: Surgery with neurosurgical microscope (A); Posterior fossa approach for a resection of an hemangioblastoma with binocular when microscope was unavailable (B); Training with chicken wing and binocular with headlight (C).

**Table 1.** Summary of our operated cases of intraventricular and periventricular tumors. (ICH: increased intracranial pressure; VPS: ventriculoperitoneal shunt; V2: Lateral ventricle; V3: third ventricle; V4: Fourth ventricle.

	Age: Year	Year of surgery	Symptome	Tumor Location	Approach	Preoperative shunting
1	12	2015	ICH + cerebellar syndrome	V4 (and floor of V4	Telovelar	No
2	4	2017	ICH + cerebellar syndrome	(cerebellar) V4	Trans cerebellar	VPS
3	17	2017	ICH + cerebellar syndrome	(cerebellar V4)	Trans cerebellar	VPS
4	29	2018	ICH	Right V2 (extended to left thalamus	Left transfrontal	No
5	4	2018	ICH + cerebellar syndrome	(Cerebellar) V4	Trans cerebellar	VPS

	Age: Year	Year of surgery	Symptom	Tumor Location	Approach	Preoperative shunting
6	5	2018	ICH + cerebellar syndrome	V4 (and floor of V4)	Telovelar	Ventriculo cisternostomy
7	27	2018	ICH + cerebellar syndrome	V4	Telovelar	VPS
8	14	2018	ICH + hemiparesis (2/5)	Thalamus	Endoscopic removal of the nodule	No
9	6	2019	ICH	Left Monro (V2)	left inter hemispheric	VPS
10	30	2020	Headache	Thalamus	Controlateral inter hemispheric	No
11	23	2020	ICH	Left V2 (atrium)	Transtemporal (Trans T2)	No
12	6	2020	ICH	suprasellar extended to V3	Subfrontal transbasal translamina terminalis	VPS
13	38	2021	ICH + cerebellar syndrome	cerebellar extended to V4	Trans cerebellar	VPS
14	39	2022	ICH + Coma	V2 (septum pellicidum)	Cysto peritoneal shunting	Not applicable
15	35	2023	ICH	V4	Telovelar	No

*Table 1. Continued.*

	surgical duration	tumor removal	Postoperative outcome	Pathological examination	Recurrence	Alive at One year follow up
1	11	Subtotal	Improved then meningitis and death at 2 month	Gemicytic astrocytoma	Not applicable	No
2	11	Total	Meningitis and death	Pilocytic astrocytoma	Not applicable	No
3	15	Total	Improved	Pilocytic astrocytoma	No	Yes
4	14	subtotal	Right hemiparesis	Central neurocytoma	Yes (3 more surgery)	Yes
5	11	Total	Improved	hemangioblastoma	No	Yes
6	13	Subtotal	Postoperative mortality (respiratory distress)	Medulloblastoma (grade IV WHO)	Not applicable	No
7	15	Total	Improved	Atypic papilloma of choroid plexus	No	Yes
8	5	Total	Improved	Pilocytic astrocytoma	No	Yes
9	10	subtotal	Improved	SEGA (subependymal giant cell astrocytoma)	No	Yes
10	12	Subtotal	Improved	Fibrillary astrocytoma	Progression to High grade glioma (adjuvant treat- ment Stupp protocol)	Yes (death at post operative 14th month)
11	8	subtotal	improved	sub ependymoma	Yes (total removal after the recurrence)	Yes
12	16	Total	improved	Craniopharyngioma	No	Yes
13	11	Total	improved	Hemangioblastoma	No	yes
14	1	Shunting	Improved	Possible arachnoid cyst on CT Scan	No	Yes
15	13	Subtotal	Improved then ventriculitis and death	Epidermoid cyst	Not applicable	No

Supplementary data (Figure 9 and 10)

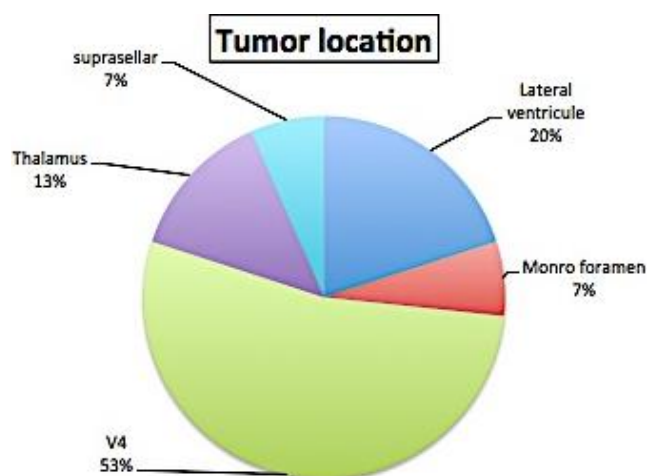


Figure 9. Tumor location.

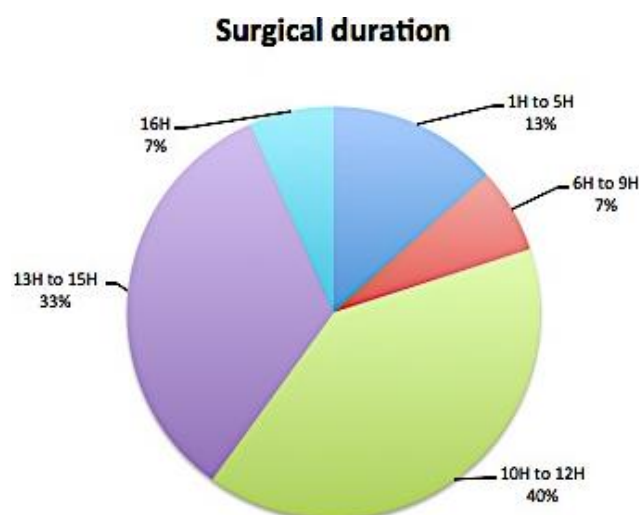


Figure 10. Surgical duration.

## 4. Discussion

Ventricular tumors are rather uncommon, accounting for less than 1% of intracranial lesions and 10% of all central nervous system neoplasm. Only 10% are exclusively within the ventricular system [3]. In our study, 1/3 of these 15 tumors were exclusively intraventricular and this was accounting for 2,9% of all intracranial processes operated during this period. This may raise the fact that this complex surgery was not routinely performed due to a small number of neurosurgeons at this period (5 neurosurgeons for 20 million population) giving the priority to others field of neurosurgical practice such us Trauma, spine etc.... [4].

Approximately half of the all-adult intraventricular mass lesions are located in the lateral ventricle, whereas the percentage is much lower in children [2]. This was noticed in our case where 4/9 (44.4%) tumor in adult were located in the lateral ventricle.

Commonly, these intraventricular tumors are asymptomatic

and found incidentally in develop countries [3]. In our case, all the patients experienced on admission increased intracranial pressure associated sometimes to other neurological symptoms such as gait disturbance. This was related to delay consultation regarding the small number of neurosurgeons and the paucity and expensiveness of accurate neuroimaging diagnostic platform.

Surgical resection of intraventricular is demanding and may lead to significant complications and postoperative morbidity [5, 9]. The aim of intraventricular tumor surgery are to alleviate symptoms, reduce mass effect, and have a histologic characterization [10]. If a solid intraventricular lesion causes sudden neurological deterioration due to obstructive hydrocephalus, cerebrospinal fluid (CSF) shunting should take the priority (Ventriculoperitoneal shunt, endoscopic ventriculocisternostomy) [11]. The aim of our surgical management was total removal since most intraventricular and periventricular tumors are benign and slow growing [1, 5]. This pathological benign feature led some authors to emphasized that in asymptomatic patient, conservative management can be adopted, albeit, when growth of the tumor is revealed in neuroimaging follow-up, resection should be considered even on an asymptomatic patient [12, 13]. In our study, all tumors but one case of medulloblastoma were benign after the first pathological examination. Another case of thalamic fibrillary astrocytoma showed malignant progression after first resection and required an adjuvant chemotherapy and radiation therapy (Stupp protocol). However, some authors advocate subtotal resection if the lesion involves deep structures such as ventricle walls, fornixes, thalamus, or basal ganglia, and obviously the floor of fourth ventricle [3]. In our case, a total removal was achieved in 7/15 (46,6%), among which 4 cases was located in posterior cerebellar fossa. A complete removal was achieved in a second step surgery in a patient suffering from subependymoma of lateral ventricle leading to a total excision rate of 53,3%. This result is found in literature were a total removal range from (38 to 87%) [2]. However, a case of central neurocytoma required 3 surgeries with subtotal removal, leading to a progression-free survival period of 2 years within six years and the patient is still alive with mild hemiparesis and aphasia which improved gradually. This cope with literature reporting a 5-year-progression-free survival of 55,3% in central neurocytoma after subtotal resection and reported an overall perioperative complications rate of 66%, mainly postoperative paresis and or aphasia (39%), memory difficulties (29%) and temporary hydrocephalus (26%) [5, 14]. In developed countries, the surgical management of these tumors is marked by sophisticated devices and platform which are considered as a fiction in low incomes countries. A study about thalamic glioblastoma surgery led by Lim et al, used an armamentarium constituted by neuronavigation, magnetic resonance imaging (MRI), diffuse tensor tractography imaging, tailed bullets, intraoperative computed tomography, neurophysi-



ologic monitoring (transcranial motor evoked potential, direct subcortical stimulation), fluorescence dye (5-ALA: 5-aminolevulinic acid) [2]. This condition enhances the accuracy of the surgical procedure and make it achievable in a relative short span of time. Surgical duration in our study varied from One hour to 5 hours in minimal invasive procedure such as ventriculoperitoneal shunting and endoscopic procedure respectively. This duration was greater than 10 hours in 12 cases and was extended until 16 hours in some cases (Figure 10). This long surgical time was due to the lack of proper devices and facilities at all steps of the management of these tumors: Neuronavigation, functional MRI, tractography for surgical planning; good quality microscope for appropriate visualization; High speed drill for bone flap; CUSA for better resection; neurophysiological monitoring for safe tumoral resection; biological glue for hemostasis. Thus, neurosurgeon should watch his step and remain stuck on his anatomy of this pernickety areas in moderate platform field. Post operative mortality is reported in literature between 0 to 36% and is higher in transcortical approaches than in transcallosal approach [2]. Our series, registered 4/15 case of postoperative mortality (26%) with 3 cases of post operative infection (Meningitis, ventriculitis.). The genuine post operative mortality apart from infection was related to a case of fourth ventricle medulloblastoma extended into its floor (1/15= 6.6%). At One year follow up, all the 11 patients who had survived over the post operative period were alive. The postoperative morbidity was represented by a case of postoperative hemiparesis with partial improvement and a condition of the post operative seizure in the same patient (1/11= 9.09%), whereas these complications are raging from 8 to 30% for the neurological deficit and 7% for the seizure [2]. Thus, our post operative outcomes may be favourably compared to literature values. To improve our result in time, lab training is the mainstay. This is not available in our environment, so, We were training on chicken wings with binocular to take neurosurgery to the next level in our country (Figure 8). This allowed us to recently succeeded in the clipping of intracranial aneurysms with good postoperative outcome. This latter surgery was performed by team coming from abroad in a recent past.

## 5. Conclusion

Periventricular and intraventricular processes can be safely approach in low-income country with acceptable result. However young African Neurosurgeon should be trained to be comfortable with multiple surgical approaches and also with binocular as well as with microscope. Post operative infection is a devastating factor requires a prompt and effective prevention and management. Anatomy mastering and lab training are the cornerstone to improve dramatically the learning curve of these surgery and training with chicken wing can be a good alternative. Improving our facilities Will surely improve our results for the well-being of our populations. WFNS

training program is a strong basement for the take-off of young African neurosurgeon. Backing home should be the rule after training, to develop neurosurgery in sub-Saharan Africa.

## Abbreviations

SEGA: Subependymal Giant Cell Astrocytoma  
WFNS: World Federation of Neurosurgical Societies  
MRI: Magnetic Resonance Images  
ICH: Increased Intracranial Pressure  
VPS: Ventriculoperitoneal Shunt  
V2: Lateral Ventricle  
V3: Third Ventricle  
V4: Fourth Ventricle

## Author Contributions

**Ibrahim Dao:** Conceptualization, Writing-original draft  
**Aminata Ki àntor é** Data Curation  
**Ousmane Ouattara:** Investigation  
**Fr é d é r i c B a k o:** Investigation  
**Jacques Traor é** Data Curation  
**Joseph Biogo:** Validation  
**Serge Pac ô m e Y a m é g o:** Visualisation  
**Abdoulaye Sanou:** Visualisation  
**Eustache Ki é n o u:** Data Curation  
**Louis Junior Comboigo:** Visualization  
**Ars è n e T o s s o u:** Visualization  
**Abdoulaye Thiombiano:** Visualization  
**Lassan é T a o k o:** Visualisation  
**Henry Lankoand é** Visualization  
**Elie Nassoum:** Investigation  
**Narcisse Ou é d r a o g o:** Investigation  
**Sosth è n e F a w a z A d é n i r a n:** Visualisation  
**Astride Somda:** Investigation  
**Delwend é S y l v a i n Z a b s o n n é** Software  
**Abel Kabr é** Supervision, Validation

## Data Availability Statement

The data is available from the corresponding author upon reasonable request.

## Conflicts of Interest

The authors declare no conflicts of interest.

## References

- [1] Elwatidy S. M, Al Towin A. A, Malick S. H. tumors of lateral and third ventricle: surgical management and outcome analysis in 42 cases. *Neurosciences*. 2017; 22 (4): 274-281.

- [2] Lim J, Park Y, Ahn JW, Hwang SJ, Kwon H, Sung S K, Cho K. Maximal surgical resection and adjuvant surgical technique to Prolong the survival of adult patients with thalamic glioblastoma. *PLoS One*. 2021; 16 (2): E0244325  
<https://doi.org/10.1371/journal.pone.0244325.eCollection2021>
- [3] Principles of intraventricular surgery. Neurosurgical atlas. [internet]:  
<https://www.neurosurgicalatlas.com/volumes/brain-tumors/intraventricular-tumors/principles-of-intraventricular-surgery>
- [4] Karekezi C, El Khamlichi A, El Ouahabi A, El Abbadi N, Ahokpossi SA, Ahanogbe KMH, Berete I, Bouya SM, Coulibaly O, Dao I, Djoubairou BO, Doleagbenou AAK, Egu KP, Mbaki HBE, Kinata-Bambino SB, Habibou LM, Mousse AN, Ngamasata T, Ntalaja J et al (2020) The impact of African-trained neurosurgeons on sub-Saharan Africa. *Neurosurg Focus*. 48(3): E4.
- [5] Megerssa TB, Mahesparan R. Surgical Outcome of Intraventricular Tumors; A Retrospective Single Center Study in Addis Ababa, Ethiopia. *SVOA Neurology*. 2024; 5: 1: 26-36.
- [6] Filippidis A, Tsonidis CA. Intraventricular brain tumors in children. *Pediatr Neurosurg*. 1989; 5: 230-233. [Google Scholar]
- [7] Ellenbogen RG. Transcortical surgery for lateral ventricular tumors. *FOC*. 2001; 10 (6): 1-13.  
[https://doi.org/10.3171/foc.2001.10.6.3\(6\)](https://doi.org/10.3171/foc.2001.10.6.3(6))
- [8] Kasowski H, Piepmeyer JM. Transcallosal approach for tumors of the lateral and third ventricles. *FOC*. 2001; 10(6): 1- 5.  
<https://doi.org/10.3171/foc.2001.10.6.4>
- [9] Kriankumar C, Deshpande R, K. Chandrasekhar YbV, Rao Is, Panigrahi M, Babu P. Clinical management and prognostic outcome of intracranial ventricular tumors: A study of 134 cases. *Cancer Res Stat Treat*. 2019; 2(1): 10.  
[https://doi.org/10.4103/CRST.CRST\\_19\\_19](https://doi.org/10.4103/CRST.CRST_19_19)
- [10] Vigo, V., Monroy-Sosa, A., Rodriguez-Rubio, R. (2021). Surgical Treatment of Intraventricular Tumors. In *Brain and Skull Base*, (eds) Principles of Neuro-Oncology. Switzerland: Springer Nature, Cham; 2021, 561-581  
[https://doi.org/10.1007/978-3-030-54879-7\\_28](https://doi.org/10.1007/978-3-030-54879-7_28)
- [11] Grundy P, Apostolopoulos V. Intraventricular tumors. In: Kirolos AH RW, Thomson S, Hutchinson PJA, editors. *Neurological surgery*: Oxford University Press; 2019.
- [12] Yasargil MG, Abdulrauf SI. Surgery of intraventricular tumors. *Neurosurgery*. 2008; 62 (6 Suppl 3): 1029-40. discussion 40-1.  
<https://doi.org/10.1227/01.neu.0000333768.12951.9a>
- [13] Zanini MA, Faleiros AT, Almeida CR, Clara CA, Gabarra RC. Trigone ventricular meningiomas: surgical approaches. *Arq Neuropsiquiatr*. 2011; 69 (4): 670-675.  
<https://doi.org/10.1590/s0004-282x20110005000>
- [14] For the French Society of Neurosurgery, Lubrano V, François P, Loundou A, Vasiljevic A, Roche PH. Outcomes after surgery for central neurocytoma: results of a French multicentre retrospective study. *Acta Neurochir*. 2013; 155 (7): 1261-1269.  
<https://doi.org/10.1007/s00701-013-1732-y>

## Biography

**Ibrahim Dao** is an assistant professor in neurosurgery at the Higher Institute of Health Sciences in Bobo Dioulasso (Nazi Boni University) since 2019. He holds also the position of neurosurgeon at the University Hospital Sourou Sanou and at the Military Hospital Colonel Major Tanguet Ouattara.