

Research Article

Strangulated Transmural Hernia of the Uterus After Myomectomy: A Rare Cause of Bowel Obstruction

Camara Mamadouba^{2,*} , Bly Pers édou éRomuald¹ , Ciss éFod é,
Camara Mamadou¹

¹Department of General Surgery, Centre Hospitalier Universitaire Treichville, Abidjan, Côte D'Ivoire

²Farah Polyclinic, Abidjan, Ivory Coast

Abstract

Consultation for mechanical bowel obstruction is one of the most common reasons in emergency and surgical departments. Transmural hernia of the strangulated uterus after myomectomy is a rare etiology of intestinal obstruction. Their diagnosis is increasingly complex and is discovered during an exploratory laparotomy. In this observation, we report the case of this 34-year-old patient with a history of myomectomy, nulliparous admitted for persistent abdominal pain and vomiting. an abdominopelvic ultrasound showed images of uterine myomas in necrobiosis. the patient presented an occlusive syndrome for which an abdominopelvic MRI which confirmed the diagnosis of aseptic necrobiosis. This unusual image mimicking that of a necrobiosis of uterine myoma was the difficulty which allowed this diagnostic error and the delay in the treatment of this patient. As this philosophy emphasizes (never let the sun rise or set in case of mechanical obstruction of the small intestine). Given the persistence of clinical signs, an abdominal CT scan was requested and confirmed the diagnosis of occlusive syndrome. conclusion: Faced with the diagnosis of an acute intestinal obstruction following a myomectomy by a combination of persistent abdominal pain, vomiting, cessation of materials and gas, systematically look for an obstruction of internal hernia by incarceration in a myomectomy cubicle. Exploratory laparotomy makes it possible to find the etiology and treat it.

Keywords

Transmural Hernia, Intestinal Obstruction, Aseptic Necrobiosis

1. Introduction

Internal hernias are protrusions of hollow abdominal viscera into an intraperitoneal opening, but which remain within the abdominal cavity. [1] This is the protrusion of an abdominal organ through a normal or abnormal mesenteric or peritoneal opening. [2] Internal hernias are rare. They are usually diagnosed intraoperatively. Anatomical forms are

numerous, some being very rarely reported. [1, 3-5] These hernias are generally described in a single case report. [4-11] Transmural hernia of the uterus is a rare form of internal hernia. We report a case of transmural hernia of the uterus revealed by occlusion secondary to myomectomy.

*Corresponding author: drmcamara28@gmail.com (Camara Mamadouba)

Received: 9 April 2024; Accepted: 7 May 2024; Published: 30 May 2024



Copyright: © The Author(s), 2024. Published by Science Publishing Group. This is an **Open Access** article, distributed under the terms of the Creative Commons Attribution 4.0 License (<http://creativecommons.org/licenses/by/4.0/>), which permits unrestricted use, distribution and reproduction in any medium, provided the original work is properly cited.

2. Clinical Observation

A 34-year-old female, P0G0 with a one-year history of myomectomy, was admitted for diffuse abdominal pain and vomiting of food, with no evidence of cessation of bowel movements or gas. This symptomatology had been evolving for a week. On examination, blood pressure was 110/83 mmHg, pulse 102 beats per minute, temperature 37 °C. Questioning revealed similar pain, which subsided with analgesics.

Physical examination revealed pelvic tenderness over the suprapubic scar, with no palpable mass, and a distended abdomen. The parietal hernial orifices were free. Abdominal ultrasound showed necrobiosis of the uterine myoma. However, given the persistence of pelvic pain and the onset of fluid and gas cessation, an abdomino-pelvic MRI (figure 1) was performed, revealing a 36mm necrotic myoma in the isthmic region.

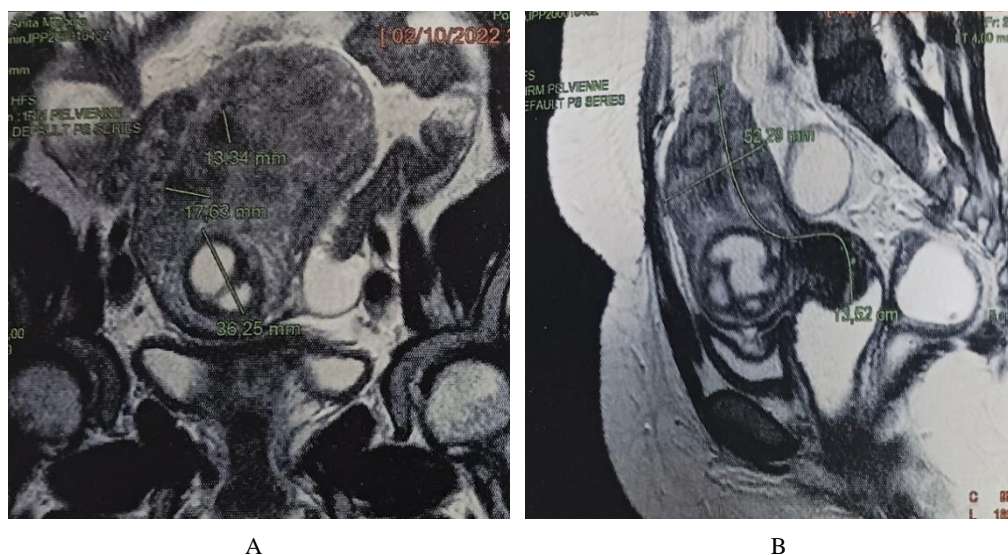


Figure 1. A- Coronal section of pelvic MRI showing a necrotic uterine myoma; B- sagittal section: Respect for the uterine cavity with an image confused with a necrotic myoma.

Given the persistence of pelvic pain and the onset of cessation of bowel movements and gas, we performed a CT scan, which revealed intestinal distension of the bowel with a transition zone (figure 2).

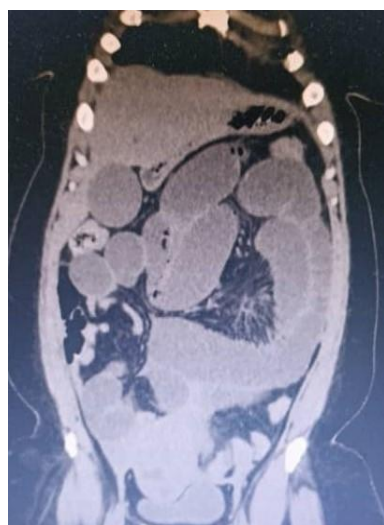


Figure 2. Abdominal-pelvic CT scan, coronal section: distension of the gallbladder with a transition zone at pelvic level.

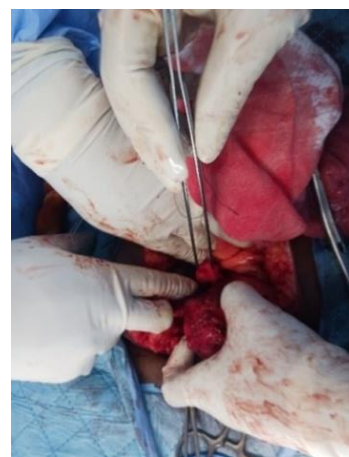

Figure 3. Uterine breach of isthmic seat after disincarceration of the ileal loop.

The diagnosis of acute intestinal obstruction was retained and an emergency laparotomy was indicated. The incision was median. Intraoperatively, we noted an ileal loop incarceration 60cm from the ileo-caecal junction through a 3cm myomectomy defect located posteriorly on the isthmus. The defect was 4cm deep and 3.44cm in diameter. The incarcerated ileum was

necrotic over 5 cm. Treatment consisted of resection of the necrotic ileum with end-to-end anastomosis and closure of the uterine defect with absorbable suture in two planes. Postoperative recovery was straightforward. Discharge was authorized on the seventh postoperative day.

3. Discussion

Acute intestinal obstruction is rarely caused by internal hernias. [2] Internal hernias of the abdomen are explained by the displacement of one or more viscera through an intraperitoneal orifice. This orifice may be normal, such as Winslow's hiatus, or paraneural, represented by the peritoneal fossae. They may be acquired or congenital. [1, 3, 12, 13]

Transmural hernias of the uterus secondary to caesarean section are the most frequently described transmural hernias. [14-16] The major defect in healing after Caesarean section may take the form of a complete absence of the anterior wall of the uterus, with a defect in scarring (isthmoceles) noted. [14] Transmural hernia strangulated in a uterine myoma enucleation site is extremely rare. Clinical diagnosis of internal hernia is difficult, as symptoms are totally aspecific. [2, 3, 13] The diagnosis of internal hernia is less and less exceptionally made by imaging. [2] Because internal abdominal hernias are rare, their diagnosis remains a challenge for both clinician and radiologist. Symptoms of internal abdominal hernias are non-specific, consisting of mild abdominal discomfort alternating with episodes of intense periumbilical pain and nausea. CT scans are thought to facilitate the diagnosis of internal abdominal hernias. [13, 17] However, performing an emergency abdominal CT scan may contribute to preoperative diagnosis and guide the therapeutic approach. Our diagnostic difficulty was related to the rarity of our case, incarceration of a short segment in a myoma enucleation pocket, which led to a delay in the operative indication. Ultrasound revealed uterine myoma necrosis, and MRI images supported the diagnosis of necrobiosis, which explains the delay in management. This image of the transmural hydroaeric level was not diagnosed preoperatively, and the diagnosis of certainty was made intraoperatively. The diagnosis of a small bowel obstruction was suggested by the abdominal CT scan, without specifying a possible cause. However, the examination of choice is abdominal CT in cases of acute intestinal obstruction in the abdomen. It offers the possibility of diagnosing the mechanism of the obstruction and, above all, the etiology, in particular an internal hernia through the falciform ligament. In this way, the surgical procedure to be performed as a matter of urgency can be oriented and the approach adjusted. Once the diagnosis has been made, emergency surgery is required to unblock the bowel loop, with or without intestinal resection, depending on its vitality. [18-21] Distinction from necrobiosis can be tricky. It is rare and exceptionally reported in the radiological literature. However, Hoeffel JC reported a case of CT demonstration of internal herniation of the small intestine. [8] Some hernias develop at the expense of the anterior aspect

after caesarean section. To the best of our knowledge, we have not found an ileal loop strangulation in a myomectomy dressing. [9, 22] CT signs common to all types of internal hernia included signs of small bowel obstruction. [17-25]

Several factors could favor the appearance of this hernia: early release of sutures, dehiscence of the myomectomy scar. Traoré et al. described a case of uterine perforation with occlusion by incarceration of the small loop. The perforation breach was 20 mm in diameter, with intrauterine incarceration of the intestinal loop, giving the image of tubular tissue in the uterine cavity. [23]. In our case, on the other hand, the breach was 3.44 mm wider, without invasion of the uterine mucosa, and the image was suggestive of myoma necrosis. The common mechanism is ileal loop incarceration. Surgical treatment can be performed laparoscopically or by laparotomy with uterine breach closure.

4. Conclusion

Strangulated transmural hernia due to ileal loop incarceration is an extremely rare cause of mechanical obstruction. MRI is diagnostic, but can be misleading. Occlusion is diagnosed by abdominal CT scan. The diagnosis of internal hernias should be made in the presence of any aspecific ileal loop occlusion in a woman with a history of pelvic surgery. Delay in diagnosis can be reduced if these complications are considered at the time of diagnosis, and if imaging studies are illustrative.

Abbreviations

CHU Centre Hospitalier Universitaire

Acknowledgments

We would like to thank the management of Farah Polyclinic and all the authors who contributed to this article.

Author Contributions

Camara Mamadouba: Conceptualization, Writing
Bly Pers édou éRomuald: Data Retention, Resources
Ciss éFod é writing - Original draft
Camara Mamadou: Writing, Revision

Funding

Personal.

Conflicts of Interest

The authors declare no conflicts of interest.

References

- [1] Mathias J, Phi I, Bruot O, Ganne PA, Laurent V, Regent D. Internal hernias. EMC - Radiology and Medical Imaging - Abdominal - Digestive. Jan 2008; 3(4): 1-8.
- [2] Meyers, MA. Dynamic radiology of the abdomen: normal and pathological anatomy, 4th ed. New York, NY: Springer Verlag, 1994 Google Scholar.
- [3] Fadil A. Acute intestinal obstruction by incarceration of the small intestine in the broad ligament: a case report. 8 Jul 2021 [cited 28 Mar 2023].
- [4] F. N. Koksoy, G. R. Soybir, T. M. Bulut, O. Yalcin, Y. Aker, H. Kose, Internal supravescical hernia: report of a case, Am. Surg. 61(11) (1995) 1023-1024.
- [5] I. Sozen, J. Nobel, Inguinal mass due to an external supravescical hernia and acute abdomen due to an internal supravescical hernia: a case report and review of the literature, Hernia 8(4) (2004) 389-392.
- [6] M. Cisse, I. Konate, O. Ka, M. Dieng, A. Dia, C. T. Toure, Internal supravescical hernia as a rare cause of intestinal obstruction: a case report, J. Med. Case Rep. 3(2009).
- [7] T. Watanabe, M. Kamiga, I. Hirai, M. Mizutani, A. Fuse, W. Kimura, A case of supravescical hernia, Nihon Geka Gakkai Zasshi 65(3) (2004) 801-805.
- [8] Hoeffel JC, Zimmerger J, Pocard B, Hoeffel C. Demonstration by computed tomography of a case of internal small bowel herniation. BJR. nov 1992; 65(779): 1045-6.
- [9] Bedioui H, Daghfous A, Daghfous A, Ksantini R, Nouria K, Chebbi F, et al. Internal falciform ligament hernia revealed by acute intestinal obstruction. La Presse Médicale. Jan 1, 2008; 37(1, Part 1): 44-7.
- [10] T. Sato, K. Miyagawa, N. Sakamoto, A case of internal supravescical hernia, Nihon Rinsho Geka Gakkai Zasshi 68(3) (2007) 706-709.
- [11] K. Asanuma, M. Yoshida, S. Takanashi, M. Kashiya, M. Ishigo-Oka, H. Kawashima, A case of internal supravescical hernia repaired by laparoscopic surgery, Nihon Rinsho Geka Gakkai Zasshi 74(1) (2013) 238-242.
- [12] Zarvan NP, Lee FT Jr, Yandow DR, Unger JS. Abdominal hernias: results of computed tomography. AJR, 1995; 164: 1391-1395.
- [13] Blachar A, Federle MP. Bowel obstruction after liver transplantation: clinical and CT findings in 48 cases with emphasis on internal herniation. Radiology 2001; 218: 384-388.
- [14] Jeremy B, Bonneau C, Guillo E, Paniel BJ, Le Tohic A, Haddad B, et al. Transmural isthmus hernia of the uterus: results of isthmorrhaphy on symptomatology and fertility. Gynecology Obstetrics & Fertility. Oct 1, 2013; 41(10): 588-96.
- [15] Ghahremani GG. Abdominal and pelvic hernias. In: Gore RM, Levine MS, eds. Handbook of Gastrointestinal Radiology, 2nd ed. Philadelphia, Pennsylvania: Saunders, 1994.
- [16] Masuda H, Uchida H, Maruyama T, Sato K, Sato S, Tanaka M. Successful treatment of atypical cesarean scar defect using endoscopic surgery. BMC Pregnancy Childbirth. 2015 Dec 22; 15: 342. <https://doi.org/10.1186/s12884-015-0730-x> PMID: 26696492; PMCID: PMC4687144.
- [17] Blachar A, Federle MP, Dodson SF. Internal hernia: clinical and imaging findings in 17 patients with emphasis on CT criteria. Radiology 2001; 218: 68-74 Google Scholar.
- [18] Hong, Seong Sook M. D.; Kim, Ah Jeune, M. D.; Kim, Pyo Nyun M. D.; Lee, Moon-Gyu MD; Ha, Hyun Kwon MD. Current diagnostic role of CT in the evaluation of internal hernia. Journal of computed tomography 29(5): p 604-609, September 2005. | <https://doi.org/10.1097/01.rct.0000168326.17363.b2>
- [19] R Zissin, M Hertz, G Gayer, H Paran, A Osadchy, Congenital internal hernia as a cause of small bowel obstruction: CT findings in 11 adult patients, British Journal of Radiology, Volume 78, Issue 933, 1 September 2005, Pages 796-802, <https://doi.org/10.1259/bjr/87050272>
- [20] Haku T, Daidouji K, Kawamura H et al: Internal hernia by a defect of the broad ligament of the uterus. Abdom Imagery 2004; 29: 161-163.
- [21] Akyildiz H, Artis T, Sozuer E, Akcan A, Kucuk C, Sensoy E, Karahan I. Internal hernia: complex diagnostic and therapeutic problem. Int J Surg. 2009 Aug; 7(4): 334-7. <https://doi.org/10.1016/j.ijsu.2009.04.013> Epub 2009 May 5. PMID: 19422936.
- [22] Masson E. EM-Consulte. [cited March 28, 2023]. Diagnosis and management of uterine perforation by intrauterine device: from 11 cases. Available at: <https://www.em-consulte.com/article/810124/diagnostic-et-pri-se-en-charge-des-perforations-ute>
- [23] Traoré H. Uterine perforation intestinal occlusion small bowel incarceration l'hôpital Nianankoro FOMBA de Ségou. 2022 [cited 28 March 2023]; Available from: <https://www.bibliosante.ml/handle/123456789/5788>
- [24] Harbin WP. Tomographic diagnosis of internal hernia. Radiology 1982; 143: 736 PubMed Google Scholar.
- [25] Sasaya T, Yamaguchi A, Isogai M, Harada T, Kaneoka Y, Suzuki M. Supravescical hernia: diagnosis by computed tomography. Abdom Imagery 2001; 26: 89-91 Google Scholar.