



## Research Article

# Demographics and Pathomorphology of Ameloblastoma: A 9 Year Retrospective Review at a Tertiary Health Care Centre in North-Central Nigeria

**Philip Ojile Akpa<sup>1,2,\*</sup>** , **Innocent Emmanuel<sup>1,2</sup>**, **Barka Vandi Kwaghe<sup>1</sup>**,  
**Ijeoma Ahunna Okwudire-Ejeh<sup>3</sup>**, **Ayuba Madachi Dauda<sup>1,2</sup>**,  
**Olugbenga Akindele Silas<sup>1,2</sup>** 

<sup>1</sup>Department of Anatomic Pathology and Forensic Medicine, Jos University Teaching Hospital, Jos, Nigeria

<sup>2</sup>Department of Pathology, University of Jos, Jos, Nigeria

<sup>3</sup>Anatomic Pathology and Forensic Medicine Department, Asokoro District Hospital, Abuja, Nigeria

## Abstract

Ameloblastoma is a benign but locally invasive neoplasm that arises from odontogenic epithelium of the dental lamina. It is classified into the conventional, unicystic, extraosseous/peripheral and metastasizing variants. It is the most common odontogenic tumour in Nigeria and other developing countries. It affects individuals of all ages, has a peak of occurrence in the fourth and fifth decades with no sex predilection. The Mandible is the most commonly affected site and the conventional variant is predominant. The aim of this study is to document the demographics and Pathomorphology of ameloblastoma diagnosed at the Jos University Teaching Hospital over the past nine years. There is no previous documentation of the pattern of this tumour in the North-central region of Nigeria making this study relevant. This is a retrospective observational review of all cases of ameloblastoma diagnosed histologically at the Jos University Teaching Hospital between January 1st 2015 to December 31st 2023. Materials utilized consisted of patient clinical case files, electronic histopathology result records, histopathology glass slides and formalin fixed paraffin embedded tissue blocks. The patient age, sex, anatomic location of tumour in the Jaw/face and pathomorphological features were recorded for all cases. The data obtained was analysed using Epi-info 7 (version 3.5.4) and Microsoft-Excel. Results were presented in tables and charts. Fifty one cases of ameloblastoma were diagnosed during the 9 years of review. Their ages ranged between 6 and 65 years with a mean age of  $30.9 \pm 13.8$  years and a peak of occurrence in the third decade. There were 29 males and 22 females with a male to female ratio (M:F) of 1.3:1. Ninety-two percent of cases occurred in the mandible and 8% in the maxilla. The conventional variant accounted for 72.5% of cases and the unicystic variant 27.5%. The follicular type accounted for 64.8% of cases of conventional ameloblastoma. Ameloblastoma occurred more commonly in males with a peak in the third decade. A vast majority of cases involved the mandible and the conventional type was predominant. This demographic pattern supports existing evidence that ameloblastoma occurs more commonly in males and in relatively younger patients in Africa.

## Keywords

Ameloblastoma, Jos, North-Central, Nigeria, Conventional, Mandible

\*Corresponding author: [akpaphilip@yahoo.com](mailto:akpaphilip@yahoo.com) (Philip Ojile Akpa)

**Received:** 19 March 2024; **Accepted:** 1 April 2024; **Published:** 17 April 2024



Copyright: © The Author(s), 2024. Published by Science Publishing Group. This is an **Open Access** article, distributed under the terms of the Creative Commons Attribution 4.0 License (<http://creativecommons.org/licenses/by/4.0/>), which permits unrestricted use, distribution and reproduction in any medium, provided the original work is properly cited.

## 1. Introduction

Ameloblastoma is a benign but locally invasive neoplasm that arises from odontogenic epithelium of the dental lamina [1, 2]. The 2017 World Health Organisation (WHO) Classification of head and neck tumours classifies benign ameloblastoma into the conventional, unicystic, extraosseous/peripheral and metastasizing variants [1]. It is an infiltrative aggressive tumour with a high tendency to recur and metastasize in rare instances [1, 2]. Its aggressive behavior and ability to undergo malignant transformation makes it the most clinically significant odontogenic tumour [3].

Ameloblastoma is a relatively rare tumour with an estimated annual incidence of 0.5 cases per million of population, it is the most common odontogenic tumour worldwide excluding odontomas [1]. It accounts for about 12% of all odontogenic tumours and 1% of all tumours diagnosed in the oral region [4]. In Nigeria and other developing countries ameloblastoma is outrightly the most common odontogenic tumour [2, 5-9]. Studies reveal a higher frequency of diagnosis of ameloblastoma is African-Americans as compared to Caucasian Americans suggesting a genetic predisposition in Africans [7].

Ameloblastoma affects individual of all ages. The Conventional variant occurs in individuals from the first to the tenth decade of life with a peak in the fourth and fifth decades, while the Unicystic variant occurs from the first to eight decades with its own peak of diagnosis in the second decade [1]. Diagnosis of ameloblastoma occurs about a decade earlier in blacks in comparison to individuals of European descent with a mean age at diagnosis of 30.4 years and 42.3 years respectively [10]. The mean age at diagnosis in the largest multicenter research on ameloblastoma in Nigeria was  $32.5 \pm 14.5$  years [2].

There is no gender bias in ameloblastoma diagnosis [11]. This usually holds true in the conventional variant while the unicystic variant may have a slight male bias [1]. A male predominance of diagnosis has been frequently reported in Nigeria [12-16]. Agbaje et al reported a slight male predominance in a study which pooled data from 10 tertiary hospitals in 5 out of the 6 geopolitical regions of Nigeria [2]. Some Nigerian authors have postulated that a male bias especially in the northern part of the country reflects reduced access of females to health care rather than a true male predominance [15].

The mandible is the commonest site of diagnosis of ameloblastoma (80% of cases), the maxilla is the next most common site while the sinonasal tract is also rarely affected [1]. In Nigeria, authors have reported an overwhelming predilection for occurrence in the mandible, the maxilla has much fewer cases and peripheral ameloblastoma being very rare [2, 13-17].

Ameloblastoma usually starts as a painless expansile mass with more advanced cases manifesting as mal-occlusion of the jaw, loosening of teeth, difficulty in chewing, limitation in opening of the mouth, facial deformity and airway obstruction

[1, 16, 18, 19]. Radiographically, a honey-comb like radiolucency which is a corticated multilocular appearance is commonly seen in conventional ameloblastoma, while the unicystic variant presents as a unilocular radiolucency connected with an unerupted tooth [1].

Most cases of ameloblastoma are of the conventional variant. Grossly conventional ameloblastoma could be solid or variably cystic while the unicystic variant occurs as a single cystic cavity [1]. The conventional type of ameloblastoma are more aggressive and has an almost 90% recurrence rate with conservative surgery while the unicystic type is less aggressive with a lower recurrence rate [18, 20].

The follicular histological type of ameloblastoma is the most common of the conventional variant with the plexiform type coming second. Other histopathological types of conventional ameloblastoma include the acanthomatous, granular, basaloid and desmoplastic [1]. An admixture of histopathological types can also be found in one surgical sample. Such as an admixture of the follicular type with the acanthomatous or plexiform type [1, 14, 17]. The unicystic type could be a luminal, intraluminal or mural type depending on the pattern of proliferation and distribution of ameloblastic epithelium within the lesion [1].

## 2. Materials and Methods

This study is a retrospective observational study that reviewed all cases of ameloblastoma diagnosed histologically at the Jos University Teaching Hospital (JUTH) between January 1<sup>st</sup> 2015 to December 31<sup>st</sup> 2023. JUTH is a tertiary healthcare facility located in Jos, Plateau state, in the North-central part of Nigeria. It receives Maxillofacial/Dental referrals from all over the state of Plateau and Neighboring North-Central states. Materials utilized for this research consisted of patient clinical case files, electronic histopathology result records, histopathology glass slides and formalin fixed paraffin embedded tissue blocks. The patient age, sex, anatomic location of tumour in the Jaw/face and pathomorphological features were recorded for all cases using the aforementioned materials. Archived glass slides and freshly made slides from tissue blocks in cases of missing or poor-quality slides were used for evaluation of histopathology diagnosis. The glass slides of all cases of ameloblastoma were reviewed by the authors of this research to confirm the diagnosis. The data obtained was analysed using Epi-info 7 (version 3.5.4) and Microsoft-Excel. Results were presented in tables and charts.

## 3. Results

The clinical records, laboratory records and histopathology glass slides of fifty two (52) cases of ameloblastoma were

reviewed, fifty one met the inclusion criteria and one case was excluded for incomplete data. An average of 5.7 cases of ameloblastoma were diagnosed per year over the 9 years of review. Their ages ranged between 6 and 65 years with an average age of  $30.9 \pm 13.8$ . Fifteen percent (15%) of cases were diagnosed in individuals less than 18 years (table 1). There were 29 males and 22 females with a male to female ratio

(M:F) of 1.3:1 (table 2). Ninety-two percent (92%) of cases occurred in the mandible and 8% in the maxilla (table 3). The conventional variant accounted for 72.5% of cases and the unicystic variant 27.5% (figure 1). The follicular type accounted for 64.8% of cases of conventional ameloblastoma (figure 2). Photomicrographs of histopathological types of ameloblastoma are shown below (figure 3).

**Table 1.** Age distribution of the morphological variants of ameloblastoma.

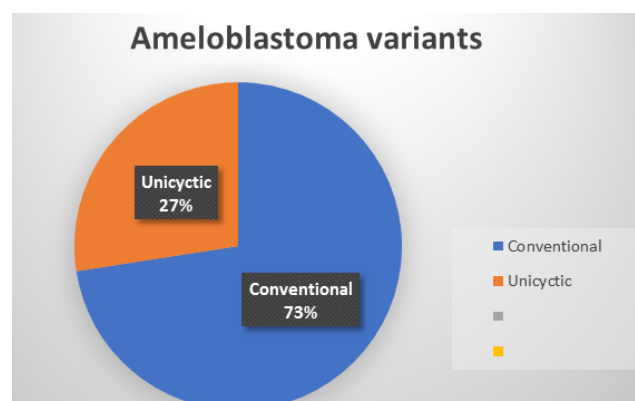
	0-10	11-20	21-30	31-40	41-50	51-60	61-70	Total
Unicystic	0	3	4	4	2	1	0	14
Follicular	1	5	9	4	3	0	2	24
Plexiform	0	1	0	0	0	2	0	3
Acanthomatous	0	0	1	0	0	0	0	1
Follicular-Acanthomatous	0	2	3	1	0	1	0	7
Follicular-plexiform	0	0	0	2	0	0	0	2
Total	1	12	17	11	6	4	2	51

**Table 2.** Sex distribution of the Morphological variants ameloblastoma.

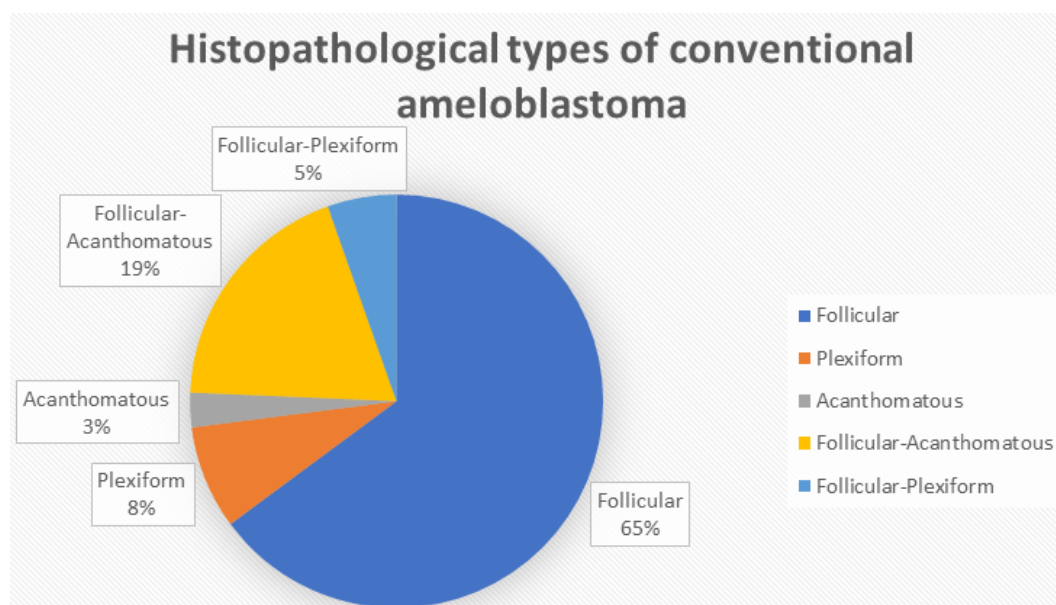
	Male	Female	Total
Unicystic	8	6	14
Follicular	15	9	24
Plexiform	1	2	3
Acanthomatous	0	1	1
Follicular-Acanthomatous	4	3	7
Follicular-plexiform	1	1	2
Total	29	22	51

**Table 3.** Anatomical distribution of the morphological variants ameloblastoma.

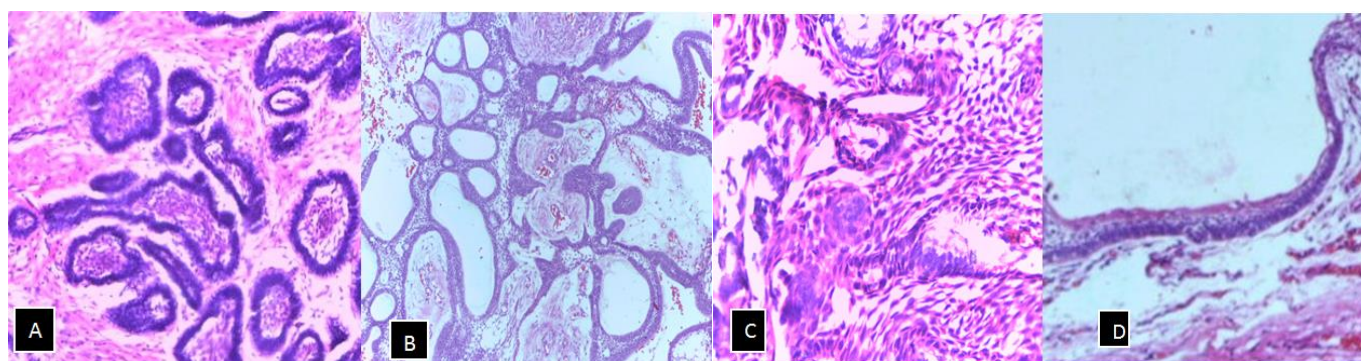
	Mandible	Maxilla	Total
Unicystic	12	2	14
Follicular	23	1	24
Plexiform	2	1	3
Acanthomatous	1	0	1
Follicular-Acanthomatous	7	0	7
Follicular-plexiform	2	0	2
Total	47	4	51



**Figure 1.** Chart showing the morphological variants of ameloblastoma.



**Figure 2.** Chart showing the histopathological types of conventional ameloblastoma.



**Figure 3.** Photomicrographs  $\times 100$  magnification (Hematoxylin and Eosin stain) A. Follicular ameloblastoma with islands of odontogenic epithelium surrounded by fibrous stroma. B. Plexiform ameloblastoma showing cords of anastomosing odontogenic epithelial cells. C. Acanthomatous ameloblastoma showing squamous metaplasia and variable keratinization in stellate reticulum-like cells. D. Unicystic ameloblastoma showing a cyst lined by ameloblastic epithelium.

## 4. Discussion

Patient ages ranged between 6 and 65 years with an average age of  $30.9 \pm 13.8$  and a peak of occurrence in the third decade. This correlates with the findings of other Nigerian authors who also documented a peak in the third decade [12-14, 17]. The mean ages at diagnosis were 31.67 and 31.43 years in Lagos, South-Western Nigeria and Sokoto, North-Western Nigeria respectively [13, 14]. Worldwide the peak of occurrence is in the fourth and fifth decades which indicates a younger age at diagnosis in individuals of African descent [10]. The mean ages documented in India (32.1 years) [21] and China (32.7 years) [22] are similar to figures seen in Nigeria while the mean ages reported in Australia (43 years) [23] and the United States of America (53 years) [24] are significantly higher than our observations. Fifteen percent of cases in our study occurred in the pediatric age group.

This figure approximates the 14.6% documented by Olaitan et al in Kaduna, North-Western Nigeria [25] but is lower than the 21.9% reported by Arotiba et al in a multi-center study involving four tertiary hospitals spanning two geopolitical regions of Nigeria [16]. Studies have revealed that as much as 25% of cases of ameloblastoma diagnosis among Africans occur in children as compared to 10-15% in Non-Africans [3]. Older reports from the western world suggested that ameloblastoma occurred rarely in children [26]. Only one case in our study was diagnosed in the first decade (a 6-year-old male), which correlates with the youngest age of diagnosis of ameloblastoma in the multi-center study by Arotiba et al [16]. Our findings support established literature that ameloblastoma is very rare in children in the first decade [18, 27]. The mean ages of ameloblastoma diagnosis appear to be directly related to the life expectancy of the population, with higher mean ages



reported for countries with higher life expectancies. The unicystic variant of ameloblastoma is documented to occur at a younger average age than the conventional variant [1]. There was no significant difference in the mean ages for the conventional ( $31.2 \pm 14$  years) and unicystic ( $30.4 \pm 12$  years) variants of ameloblastoma in our study. This may be due to the small number of cases in our study.

Our study revealed a male predominance with a male to female ratio of (M:F=1.3:1). This male predominance was essentially the same for both the Conventional (M:F=1.3:1) and unicystic variants (M:F=1.3:1). Most other Nigerian studies report varying magnitudes of a male predominance [12-16]. A male predominance of a lesser magnitude than ours was reported by Soyele et al (1.02:1) in a multicenter study [15] and Ladeinde et al (1.1:1) in Lagos South-Western Nigeria [13] while higher male to female ratios than ours was reported by Olaitan et al (1.6:1) in Kaduna North-Western Nigeria [28] and Omitola et al (2:1) in Gombe North-Eastern Nigeria [29]. The findings in these Nigerian studies is at variance with the global picture which shows an equal gender distribution [1]. A male predominance was however also reported by Tatapudi et al and Oomens et al in India and the Netherlands respectively [30, 31].

A majority of ameloblastoma cases (92%) in our study occurred in the mandible with only 8% involving the maxilla. This correlates exactly with a study by Ladeinde et al in Lagos whereby 92.8% of cases occurred in the mandible but is higher than the 83.6% documented by Ibikunle et al in Sokoto [13, 14]. A multicenter study by Soyele et al which pooled data from 5 tertiary health centers in Southern Nigeria documented 93.6% of cases in the mandible [15]. World-wide a majority of cases occur in the mandible with an average of 80% of ameloblastoma cases affecting this site [1]. The predominance of mandibular cases is as a result of a higher number of dental lamina rest cells in the mandible as compared to the maxilla [29].

The conventional and Unicystic variants of ameloblastoma accounted for 72.5% and 27.5% of cases respectively in our study. Our findings appear similar to that of a multicenter study involving five tertiary healthcare facilities across Nigeria in which 80% and 20% were of conventional and unicystic variants respectively [15]. The percentage distribution of the variants however varies significantly across Nigeria. Fifty-eight percent (58.4%) and 41.6% were of the conventional and Unicystic variant in a report by Castano et al in Lagos Nigeria [12]. While a study by Ibikunle et al in Sokoto reported over Ninety percent of cases as the conventional variant, with only 7.5% being Unicystic [14]. Collation of data by the world health organization revealed a predominance of the conventional type with the unicystic variant accounting for between 5-22%, the peripheral variant accounting for between 1-10% and the metastasizing type occurring rarely [1]. The follicular type (64.8%) was the most common of the conventional ameloblastoma variant in our study, this aligns with the reports of other Nigerian authors such as Ibikunle et al, Omitola et al and

Ladeinde et al who all documented a predominance of the follicular variant [13, 14, 29]. As much as 24.3% of cases were of the mixed histological type in our study with a mixed follicular-acanthomatous pattern being predominant. The percentages of mixed ameloblastoma documented by authors in other parts of Nigeria are lower. Adebisi et al and Ibikunle et al reported 9% and 16.5% of their cases as mixed histology ameloblastoma in Ife, South-Western Nigeria and Sokoto, North-Western Nigeria respectively [14, 17].

## 5. Conclusion

Ameloblastoma showed a male bias with a peak of occurrence in the third decade which is one decade younger than the global average. The mandible was overwhelmingly affected and majority of cases were of the conventional variant. The demographics and pathomorphological pattern of ameloblastoma in our study aligns with the reports from other regions of Nigeria and strengthens the evidence that ameloblastoma in individuals of African descent have a male predominance and occur at a relatively younger age.

## Abbreviations

WHO: World Health Organisation

JUTH: Jos University Teaching Hospital

## Author Contributions

**Philip Ojile Akpa:** Conceptualization, Resources, Data curation, Software, Formal Analysis, Supervision, Validation, Investigation, Writing - original draft, Methodology, Visualization, Project administration, Writing - review & editing

**Innocent Emmanuel:** Conceptualization, Resources, Data curation, Software, Formal Analysis, Supervision, Validation, Investigation, Writing - original draft, Methodology, Visualization, Project administration, Writing - review & editing

**Barka Vandi Kwaghe:** Conceptualization, Resources, Data curation, Software, Formal Analysis, Supervision, Validation, Investigation, Writing - original draft, Methodology, Visualization, Project administration, Writing - review & editing

**Ijeoma Ahunna Okwudire-Ejeh:** Conceptualization, Resources, Data curation, Formal Analysis, Supervision, Validation, Investigation, Writing - original draft, Methodology, Visualization, Writing - review & editing

**Ayuba Madachi Dauda:** Data curation, Formal Analysis, Supervision, Investigation, Writing - original draft, Methodology, Visualization, Project administration, Writing - review & editing

**Olugbenga Akindele Silas:** Data curation, Formal Analysis, Supervision, Validation, Investigation, Writing - origi-

nal draft, Methodology, Visualization, Project administration, Writing - review & editing

## Conflicts of Interest

The authors declare no conflicts of interest.

## References

- [1] Vered M, Muller S, Heikinheimo K. Benign epithelial odontogenic tumours. In: El-Nagger AK, Chan JKC, Grandis JR, Takata T, Slootweg PG, eds. WHO Classification of head and neck tumours. Lyon: IARC; 2017. p. 215-19.
- [2] Agbaje OJ, Adisa AO, Petrova MI et al. Biological profile of ameloblastoma and its location in the jaw in 1246 Nigerians. *Oral Surg Oral Med Oral Pathol Oral Radiol Endod.* 2018; 126(5): 424-31. <https://doi.org/10.1016/j.oooo.2018.06.014>
- [3] Effiom OA, Ogundana OM, Akinshipo AO, Akintoye SO. Ameloblastoma: current etiopathological concepts and management. *Oral Dis.* 2018; 24(3): 307-16. <https://doi.org/10.1111/odi.12646>
- [4] Masthan KM, Anitha N, Krupaa J, Manikkam S. Ameloblastoma. *J Pharm Bioallied Sci.* 2015; 7(Suppl 1): S167-70. <https://doi.org/10.4103/0975-7406.155891>
- [5] Oginni FO, Stoelinga PJ, Ajike SA et al. A prospective epidemiological study on odontogenic tumours in a black African population, with emphasis on the relative frequency of ameloblastoma. *Int J Oral Maxillofac Surg.* 2015; 44(9): 1099-105. <https://doi.org/10.1016/j.ijom.2015.03.018>
- [6] Lasisi TJ, Adisa AO, Olusanya AA. Appraisal of jaw swellings in a Nigerian tertiary healthcare facility. *J Clin Exp Dentist.* 2013; 5(1): e42-e47. <https://doi.org/10.4317/jced.51011>
- [7] Iyogun CA, Omitola OG, Ukegheson GE. Odontogenic tumors in Port Harcourt: south-south geopolitical zone of Nigeria. *J Oral Maxillofac Pathol.* 2016; 20(2): 190-3. <https://doi.org/10.4103/0973-029X.185934>
- [8] Bassey GO, Osunde OD, Anyanechi CE. Maxillofacial tumors and tumor-like lesions in a Nigerian teaching hospital: an eleven year retrospective analysis. *Afr Health Sci.* 2014; 14(1): 56-63. <https://doi.org/10.4314/ahs.v14i1.9>
- [9] Iyogun C, Sule AA, Omitola OG. Relative prevalence of odontogenic cysts and tumours in Kano, Northern Nigeria. *J Dent Oral Health.* 2017; 3(4): 071. <https://scientonline.org/open-access/relative-prevalence-of-odontogenic-cysts-and-tumours-in-kano-northern-nigeria.pdf>
- [10] Lawal AO, Adisa AO, Olusanya AA. Odontogenic tumours: a review of 266 cases. *J Clin Exp Dentist.* 2013; 5(1): e13-e17. <https://doi.org/10.4317/jced.50949>
- [11] Mansour M, El-Mofty SK. Tumours and cysts of the Jaws. In: Pfeifer JD, Humphrey PA, Ritter JH, Dehner LP, editors. The Washington manual of surgical pathology. Philadelphia: Wolters Kluwer, 2020; p. 170-206.
- [12] Castano BO, Oluwakuyide RT, Ayodele AO et al. Pattern of histologic variants of ameloblastoma in a secondary healthcare facility in Lagos state: a 5-year retrospective study. *Niger Dent J.* 2023; 31(1): 19-26. <https://doi.org/10.61172/ndj.v31i1.105>
- [13] Ladeinde AL, Ogunlewe MO, Bamgbose BO, Adeyemo WL, Ajayi OF, Arotiba GT et al. Ameloblastoma: analysis of 207 cases in a Nigerian Teaching Hospital. *Quintessence Int.* 2006; 37(7): 69-74. <https://pubmed.ncbi.nlm.nih.gov/16429706/>
- [14] Ibikunle AA, Taiwo AO, Braimah RO, Adeyemi M, Abdullahi K, Sahabi SM. Ameloblastoma: Clinicopathologic and therapeutic analysis of 67 cases seen at Usmanu Danfodiyo University Teaching Hospital Sokoto, Nigeria. *IJHAS.* 2018; 7(4): 240-45. [https://doi.org/10.4103/ijhas.IJHAS\\_39\\_18](https://doi.org/10.4103/ijhas.IJHAS_39_18)
- [15] Soyele OO, Akinshipo AO, Effiom OA et al. A multi-centre evaluation of 566 cases of ameloblastoma in Nigeria by the African Oral Pathology Research Consortium. *Oral Cancer.* 2019; 3: 9-15. <https://doi.org/10.1007/s41548-019-00018-6>
- [16] Arotiba GT, Ladeinde AL, Ajike SO, Ugboko VI, Ajayi OF. Ameloblastoma in Nigerian Children and Adolescents: A Review of 79 Cases. *J Oral Maxillofac Surg.* 2005; 63(6): 747-51. <https://doi.org/10.1016/j.joms.2004.04.037>
- [17] Adebisi KE, Ugboko VI, Omoniyi-Esan GO, Ndukwe KC, Oginni FO. Clinicopathological analysis of histological variants of ameloblastoma in a suburban Nigerian population. *HEAD FACE MED.* 2006; 2: 1-8. <https://doi.org/10.1186/1746-160X-2-42>
- [18] Okechi UC, Akpeh JO, Chukwunke FN et al. Ameloblastoma of the jaws in children: an evaluation of cases seen in a tertiary hospital in South-Eastern Nigeria. *Ghana Med J* 2020; 54(1): 36-41 <http://dx.doi.org/10.4314/gmj.v54i1.6>
- [19] Fomete B, Adebayo ET, Ogbeifun JO. Ameloblastoma: Our clinical experience with 68 cases. *J Orofac Sci.* 2014; 6(1): 7-24. <https://doi.org/10.4103/0975-8844.132570>
- [20] Younis M, Baig N, Haq AU et al. Unicystic ameloblastoma: A distinct clinicopathologic entity. *Pakistan Oral and Dent J* 2009; 29(1): 9-12. <http://142.54.178.187:9060/xmlui/handle/123456789/18128>
- [21] Patsa S, Jadav RB, Halder GC, Ray JG, Datta S, Deb T. Demographic and histopathological variation of ameloblastoma: a hospital-based study. *J Oral Maxillofac Pathol* 2016; 20(2): 230-33. <https://doi.org/10.4103/0973-029X.185937>
- [22] Jing W, Xuan M, Lin Y et al. Odontogenic tumours: a retrospective study of 1642 cases in a Chinese population. *Int J Oral Maxillofac Surg.* 2007; 36(1): 20-5. <https://doi.org/10.1016/j.ijom.2006.10.011>
- [23] Singh T, Wiesenfeld D, Clement J, Chandu A, Nastri. Ameloblastoma: demographic data and treatment outcomes from Melbourne, Australia. *Austral Dent J.* 2015; 60(1): 24-9. <https://doi.org/10.1111/adj.12244>
- [24] Milman T, Ying GS, Pan W, LiVolsi V (2016) Ameloblastoma: 25 year experience at a single institution. *Head Neck Pathol* 10: 513-20. <https://doi.org/10.1007/s12105-016-0734-5>

- [25] Olaitan AA, Adekeye EO: Clinical features and management of ameloblastoma of the mandible in children and adolescents. *Br J Oral Maxillofac Surg.* 1996; 34(3): 248-51. [https://doi.org/10.1016/s0266-4356\(96\)90279-x](https://doi.org/10.1016/s0266-4356(96)90279-x)
- [26] Blackwood HJJ. Odontogenic tumours in the child. *Br Dent J* 1965; 119(10): 431-38.
- [27] Ord RA, Blanchaert RH. Jr, Nikitakis NG and Sauk JJ. Ameloblastoma in children. *J Oral Maxillofac. Surg.* 2002; 60(7): 762-70. <https://doi.org/10.1053/joms.2002.33242>
- [28] Olaitan AA, Adeola DS, Adekeye EO. Ameloblastoma: clinical features and management of 315 cases from Kaduna, Nigeria. *J Cranio-maxillofac Surg.* 1993; 21(8): 351-5. [https://doi.org/10.1016/s1010-5182\(05\)80497-4](https://doi.org/10.1016/s1010-5182(05)80497-4)
- [29] Omitola O, Fakuade BO, Aliyu IL. Ameloblastoma: a clinicopathologic review of cases seen in a tertiary health centre in Gombe, North Eastern Nigeria. *Afr J of Oral Maxillofac Path Med.* 2017; 3: 19–23.
- [30] Tatapudi R, Samad SA, Reddy RS, Boddu NK. Prevalence of ameloblastoma: A three-year retrospective study. *J Indian Acad Oral Med Radiol.* 2014; 26(2): 145-51. <https://doi.org/10.4103/0972-1363.143687>
- [31] Oomens MA, van der Waal I. Epidemiology of ameloblastomas of the jaws; a report from the Netherlands. *Med Oral Patol Oral Cir Bucal.* 2014; 19(6): e581-3. <https://doi.org/10.4317/medoral.20316>