

Case Report

Spinal Epidural Abscess Diagnosed at Lumbar Puncture Tap and Revealed by Paraparesis

Sylvain Raoul Simeni Njonnou^{1,*}, Lolita Noundjeu Kamdem², Aimée Tiodoung Timnou¹, Caroline Ngoufack², Sandrine Lynda Sa'a Lontsi², Marie-Josiane Ntsama Essomba¹, Odette Kengni Kebiwo¹, Ahmadou Musa Jingi¹, Alice Ninon Tsitsol Meke¹, Madeleine Singwe-Ngandeu^{1,2,3}

¹Department of Internal Medicine and Specialties, Faculty of Medicine and Biomedical Sciences, University of Yaounde I, Yaounde, Cameroon

²Yaounde Central Hospital, Yaounde, Cameroon

³Yaounde General Hospital, Yaounde, Cameroon

Email address:

raoulsims@yahoo.fr (S. R. Simeni Njonnou)

*Corresponding author

To cite this article:

Sylvain Raoul Simeni Njonnou, Lolita Noundjeu Kamdem, Aimée Tiodoung Timnou, Caroline Ngoufack, Sandrine Lynda Sa'a Lontsi, Marie-Josiane Ntsama Essomba, Odette Kengni Kebiwo, Ahmadou Musa Jingi, Alice Ninon Tsitsol Meke, Madeleine Singwe-Ngandeu. Spinal Epidural Abscess Diagnosed at Lumbar Puncture Tap and Revealed by Paraparesis. *International Journal of Infectious Diseases and Therapy*. Vol. 4, No. 2, 2019, pp. 29-32. doi: 10.11648/j.ijidt.20190402.13

Received: June 14, 2019; Accepted: July 10, 2019; Published: July 24, 2019

Abstract: Spinal epidural abscess (SEA) is a deadly disease if not promptly treated with antibiotics, either in association with neurosurgery or not. Motor impairment remains the most complication, but death can occur particularly in a resource-limited setting. We report a case of spinal epidural abscess in a 56-year-old female in an urban setting in Cameroon complicated motor impairment. She presented with a 1-week history of back pain and pollakiuria. The diagnosis was done by a lumbar puncture tap. Despite an improvement in the availability of diagnostic and therapeutic modalities for neurologic emergencies, affordability is still a challenge. An increase in our technical platform and accessibility of anyone to care remain a big challenge in sub-Saharan Africa.

Keywords: Spinal Epidural Abscess, Paraparesis, Sub-Saharan Africa

1. Introduction

Spinal epidural abscess (SEA) is a severe infection of the central nervous system usually associated with a severe prognosis. The presentation could be acute or sub-acute depending on the aetiology and can associate motor or sensitive deficit [1-3]. Severe back pain can be the only clinical finding and a delayed diagnosis can result [4, 5]. The main risk factors identified are diabetes, intravenous drug abuse, invasive procedures, and pre-existing spinal column anomalies [6-8]. In some cases, such as ours, risk factors can be multiple.

2. Observation

A 56-year-old woman was referred to the rheumatology

department with a one-week history of severe back pain with a mixed feature, (predominantly inflammatory schedule) for a week, associated with pollakiuria.

The physical examination at admission to the Rheumatology department found an obese (BMI 38.7 Kg/m²) sub pyretic patient (37.5°C) with a lumbar spinal syndrome. The rest of the exam was unremarkable. The evolution was marked 48 hours later by urinary retention, pelvic pain, and fever with asymmetric paraparesis predominant on the right limb with bilateral Babinski's sign, without sensory level.

The workup has found a C-Reactive protein (CRP) at 316 mg/L and an Erythrocyte sedimentation rate (ESR) at 70 mm/H. Full blood count (FBC), blood urea nitrogen (BUN), serum creatinine, serum uric acid, fasting blood sugar and transaminases were normal. Infectious serology including HIV, Hepatitis B and C, Herpes, Mycoplasma and Brucella were

negative. Antinuclear factor, ANCA and Rheumatoid factor were negative. Glycated Haemoglobin was 6.6%. The blood cultures were negative. Urine culture isolated *Enterococcus faecalis* sensitive to ampicillin. The chest X-ray was normal. Lumbar column CT scan showed degenerative modifications from L2 to L5 (Figure 1). Medullary MRI was not available at the beginning.

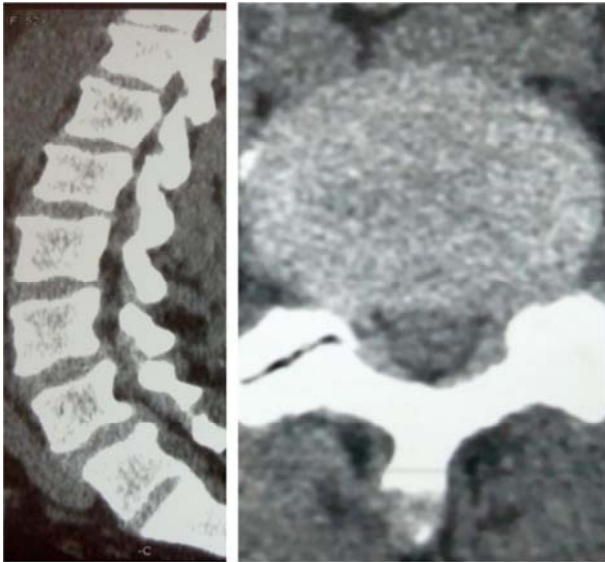


Figure 1. Lumbar CT scan: spinal canal narrowing due to circumferential disc bulging of L3-L4 and L4-L5 with effacement of epidural fat and bilateral interarticular facet joint osteoarthritis.




Figure 2. CSF: left purulent phase and right clear.

The case was discussed with neurologist and neurosurgeons, and a lumbar puncture tap was performed. It revealed a two phases cerebrospinal fluid (CSF): the first purulent and second clear (rock water) (Figure 2). Purulent phase analysis revealed an inflammatory liquid (42500 leukocytes with 98% neutrophils and 17 g/l of protein), low glucose (0.001 g/l), culture was negative but a soluble antigen with *Haemophilus*

influenzae B was found. Analysis of the clear phase found an inflammatory liquid (51 leukocytes predominantly lymphocyte with 1.49 g/l of protein), with low glucose (0.41 g/l). The culture was also sterile. *Mycobacterium tuberculosis* detection by auramine stain, culture and PCR was negative in both fluids. Ampicillin 12 g daily and Ceftriaxone 4g daily Iv, were started, associated with physiotherapy and analgesics. Lifestyle modifications were recommended according to diabetes diagnosis.

Medullary MRI, performed one week after admission, has shown a dorsolumbar epiduritis with abscess opposite L3 and a posterior abnormality of the closure of the vertebral body of D11 allowing communication of D10-D11 and D11-D12 discs. (Figure 3).

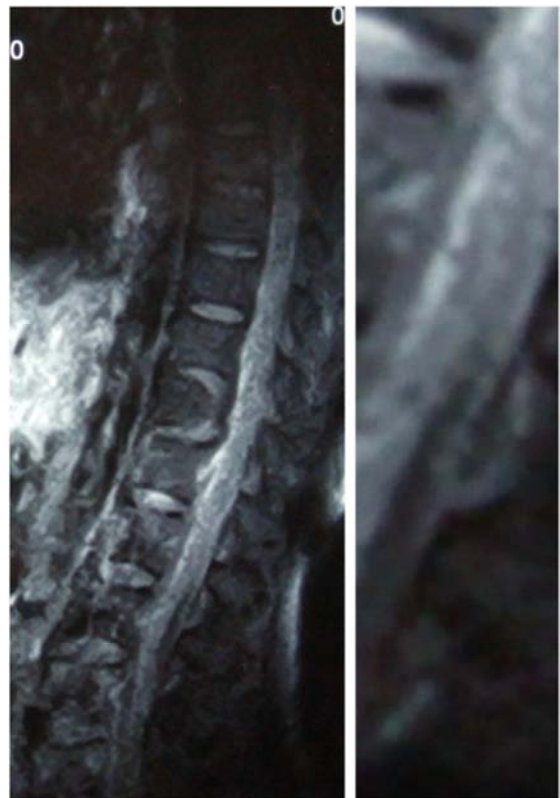

Figure 3. Dorsolumbar epiduritis with abscess opposite L3 and a posterior abnormality of the closure of the vertebral body of D11 allowing communication of D10-D11 and D11-D12 discs. The enlargement shows an abscess at L3.

Evolution was marked by apyrexia 72 h after the antibiotic beginning, reduction of low back pain and the progressive improvement of muscular strength. The control CSF, performed 2 weeks after antibiotics beginning, was clear with normal cellularity (2 elements), glucose at 0.58 g/l and protein at 0.97 g/l. (Figure 4). The control urine culture after 2 weeks of antibiotics was negative. We noted a progressive decrease of inflammation markers syndrome (monitored weekly, CRP after 6 weeks of treatment at 13 mg/l). Ampicillin was stopped after 2 weeks and Ceftriaxone after 6 weeks. Due to persistent low-grade CRP, ceftriaxone was relayed by Cefixime 200 mg twice daily during 2 weeks.

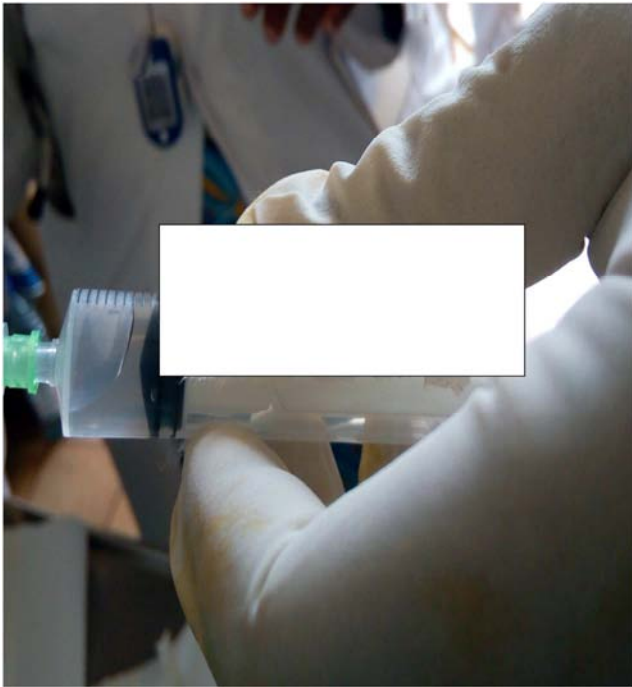

Figure 4. Control CSF.

3. Discussion

Spinal epidural abscess (SEA) is an infection of the central nervous system. Delayed diagnosis is common with an initial accurate diagnosis rate of 11% [9]. Many studies reported a male predominance. SEA can occur at any age, but this condition is more common in male after 50 years. With an increasing incidence of 2/10000 hospitalizations, the main risk factors are diabetes, intravenous drug abuse, chronic alcoholism, skin infections, spine disorders, chronic kidney disease, chronic inflammatory diseases, pregnancy and post-partum or invasive procedures on the spine [6, 7, 10].

Other rare conditions such as pre-existing spinal column anomalies have been described [8, 11]. Bacterial dissemination may be by blood or contiguity [3]. The particularity of our case is the combination of several risk factors. The clinical course of the epidural abscess has been described by Heusner in 4 stages of increasing severity [11]:

Stage 1: Intense pain with local contracture and fever;

Stage 2: Spinal irritation with the positivity of Lasègue's sign, or/and Kernig's sign or/and Brudzinski's sign;

Stage 3: neurological defect (motor, sensory and/or sphincter);

Stage 4: severe motor impairment progressing to paraparesis.

Low back pain is the most common symptom at the initial stage (71%), followed by fever (66%). At the initial stage of neurological deficit, muscle weakness and incontinence predominate, whereas in the advanced stage of neurological defect paraparesis is the most common. Signs of spinal irritation are present in only 20% of patients (including radicular signs) [7]. Our patient presented all the different clinical stages described above. This delay of diagnosis is

attributable to the weakness of our technical platform.

Biological abnormalities found are mainly a biological inflammatory syndrome with an average of 15700 leucocytes. Low or normal levels of leukocytes have been found in immunocompromised patients. ESR is accelerated in 94% of cases. Staphylococcus is the most common germ found in epidural pus (82%) followed by Streptococcaceae followed by Enterococci [2, 12]. Haemophilus was isolated in only one patient [7]. In the J. Min-Wook series in Korea, epidural pus culture was negative in 33% and Blood culture positive in only 32% of patients [6]. The analysis of cerebrospinal fluid found an inflammatory fluid in most cases. Although CSF analysis is recommended in case of high suspicion by some authors, it has become controversial due to the risk of infectious spread in the intrathecal compartment [1, 7, 13, 14].

Imaging is the gold standard for diagnosing epidural abscess. It has evolved from conventional radiography to currently computed tomography (CT) scan and Magnetic Resonance Imaging (MRI). The sensitivity of MRI is 91% while that of CT is 92%. The advantage of MRI comes from its precision on soft tissues, the absence of irradiation and the precisions on differential diagnoses [7]. The diagnosis in our case was evoked at the lumbar puncture and confirmed by the MRI.

Management of the epidural spinal abscess could be either medical only or combined with surgery. Combined management is the most common applied (89%) [7]. The recommended probabilistic antibiotic therapy must meet Leys criteria [15]. These criteria combine:

- a. efficacy against *S. aureus*,
- b. low toxicity allowing a prolonged treatment of several weeks,
- c. the ability to penetrate the bone tissue (in case of associated spondylodiscitis).

The recommended probabilistic antibiotic therapy should be combined with a third-generation cephalosporin and a major antistaphylococcal antibiotic [16]. This antibiotic treatment should be continued for 4-6 weeks. Surgical management may consist of a laminectomy or hemilaminectomy, anterior decompression, percutaneous drainage, laminotomy, spondylodesis. Laminectomy is the most common surgical technique performed (59.7%) [7, 12]. Factors for choosing nonsurgical procedures included: advanced age (>65 or 80), diabetes, cancer, IV drug use, High CRP (>115), MRI documented cord compression and significant neurological deficit [12].

Evolution is as years go by towards an increase of the complete recovery and regression of the mortality. Comprehensive recovery appears to be better in case of spontaneous epidural abscess compared to those occurring after anesthetic procedures in the epidural space due to delayed diagnosis [7]. Factors associated with poor prognosis are:

1. neurological status before surgery (patients in stage 1 or 2 are unlikely to have neurological sequelae, while stage 3 patients may have a total or partial recovery, those in stage 4 have been paralyzed for more than 24-36 hours

may show partial recovery) [17]

2. elevation of ESR beyond 111.5 mm is associated with poor functional recovery [6].

4. Conclusion

Spinal epidural abscess is a rare but severe condition. It often complicates local infection. Diagnosis may be delayed in low-income setting due to difficulties to perform diagnosis tests. Great attention should be given to febrile lombalgia. It should be considered in front of a patient presenting fever or radicular pain and SEA risk factors. The contributing risk factors are dominated by diabetes and invasive procedures. MRI is the standard gold exam. Unfortunately, availability and accessibility of diagnostic tools for SEA are poor in low-income countries. Early medical and surgical management has improved vital and functional prognosis.

Competing Interests

The authors declare no competing interest.

Authors' Contribution

SRSN drafted the initial version of the manuscript. LNK, ATT, CN, SS, MJNE, OKK and MN, critically reviewed the manuscript. All authors read and approved the final manuscript.

Acknowledgements

We thank the paramedical staff of the Rheumatology unit of the Yaounde Central Hospital who helped us to manage this case.

References

- [1] Davis DP, Wold RM, Patel RJ, Tran AJ, Tokhi RN, Chan TC, et al. The clinical presentation and impact of diagnostic delays on emergency department patients with spinal epidural abscess. *J Emerg Med.* 2004; 26 (3): 285-91.
- [2] Vakili M, Crum-Cianflone NF. Spinal Epidural Abscess: A Series of 101 Cases. *Am J Med.* 2017; 130 (12): 1458-63.
- [3] Mackenzie AR, Laing RB, Smith CC, Kaar GF, Smith FW. Spinal epidural abscess: the importance of early diagnosis and treatment. *J Neurol Neurosurg Psychiatry.* 1998; 65 (2): 209-12.
- [4] Deyo RA, Weinstein JN. Low Back Pain. *N Engl J Med.* 2001; 344 (5): 363-70.
- [5] Alerhand S, Wood S, Long B, Koyfman A. The time-sensitive challenge of diagnosing spinal epidural abscess in the emergency department. *Intern Emerg Med.* 2017; 12 (8): 1179-83.
- [6] Ju M-W, Choi S-W, Kwon H-J, Kim S-H, Koh H-S, Youm J-Y, et al. Treatment of Spinal Epidural Abscess and Predisposing Factors of Motor Weakness: Experience with 48 Patients. *Korean J Spine.* 2015; 12 (3): 124.
- [7] Reihnsaus E, Waldbaur H, Seeling W. Spinal epidural abscess: a meta-analysis of 915 patients. *Neurosurg Rev.* 2000; 23 (4): 175-204; discussion 205.
- [8] Sendi P, Bregenzer T, Zimmerli W. Spinal epidural abscess in clinical practice. *QJM Int J Med.* 2008; 101 (1): 1-12.
- [9] Tang H-J, Lin H-J, Liu Y-C, Li C-M. Spinal epidural abscess--experience with 46 patients and evaluation of prognostic factors. *J Infect.* 2002; 45 (2): 76-81.
- [10] Hill JS, Hughes EW, Robertson PA. A Staphylococcus aureus paraspinal abscess associated with epidural analgesia in labour: Case reports. *Anaesthesia.* 2001; 56 (9): 873-8.
- [11] Heusner AP. Nontuberculous Spinal Epidural Infections. *N Engl J Med.* 1948; 239 (23): 845-54.
- [12] Epstein NE. Timing and prognosis of surgery for spinal epidural abscess: A review. *Surg Neurol Int.* 2015; 6 (Suppl 19): S475-86.
- [13] Darouiche RO. Spinal Epidural Abscess. *N Engl J Med.* 2006; 355 (19): 2012-20.
- [14] Curry WT, Hoh BL, Amin-Hanjani S, Eskandar EN. Spinal epidural abscess: clinical presentation, management, and outcome. *Surg Neurol.* 2005; 63 (4): 364-71.
- [15] Leys D, Lesoin F, Viaud C, Pasquier F, Rousseaux M, Jomin M, et al. Decreased morbidity from acute bacterial spinal epidural abscesses using computed tomography and nonsurgical treatment in selected patients. *Ann Neurol.* 1985; 17 (4): 350-5.
- [16] Mampalam TJ, Rosegay H, Andrews BT, Rosenblum ML, Pitts LH. Non operative treatment of spinal epidural infections. *J Neurosurg.* 1989; 71 (2): 208-10.
- [17] Kim SD, Melikian R, Ju KL, Zurakowski D, Wood KB, Bono CM, et al. Independent predictors of failure of nonoperative management of spinal epidural abscesses. *Spine J.* 2014; 14 (8): 1673-9.