

# Comparative Study Between Role of Computed Tomography and Magnetic Resonance Imaging in Scaphoid Fracture Diagnosis

Basma Abdelmonem Desouky, Radwa Hamed Wahdan<sup>\*</sup>, Tarek Fawzy Abd Ella<sup>\*</sup>

Radiodiagnosis Department, Faculty of Medicine, Menoufia University, Menoufia, Egypt

## Email address:

radwa.h.wahdan@gmail.com (R. H. Wahdan), tarek354609@gmail.com (T. F. A. Ella)

<sup>\*</sup>Corresponding author

## To cite this article:

Basma Abdelmonem Desouky, Radwa Hamed Wahdan, Tarek Fawzy Abd Ella. Comparative Study Between Role of Computed Tomography and Magnetic Resonance Imaging in Scaphoid Fracture Diagnosis. *International Journal of High Energy Physics*.

Vol. 8, No. 2, 2021, pp. 19-25. doi: 10.11648/j.ijhep.20210802.11

**Received:** September 23, 2021; **Accepted:** October 11, 2021; **Published:** January 8, 2022

---

**Abstract:** Background: Fractures of the scaphoid are the second most common fractures of the upper limb after distal radius fractures. Rapid and accurate diagnosis is needed, because delayed initiation of therapy increases the risk of complications such as non-union and avascular necrosis. Objectives: To compare between the diagnostic accuracies of Computed Tomography and Magnetic Resonance Imaging in detecting scaphoid fractures and its complications. Methods: This study was carried out on 30 patients presented to private Hand clinic from October 2018 to December 2019, with clinical symptoms of tenderness in the anatomic snuffbox after wrist trauma and suspected to have scaphoid fracture in the plane X-ray. They were invited to enroll in a comparison of CT and MRI with regard to their diagnostic utility. Results: The mean age for study participants was 31.8 years (SD = 12.6 years). Nineteen patients (66.7%) had horizontal fractures, 10 had oblique structures (33.3). The MDCT showed that 29 patients had cortical fractures, MRI showed that 27 had cortical fractures, 2 patients had mixed fractures and one patient had a trabecular fracture. Conclusion: Multidetector CT had the superiority over MRI in detection of cortical involvement in scaphoid fractures but MDCT was inferior to MRI in detection of trabecular scaphoid fractures. MRI was superior to MDCT in early detection of stage I Scaphoid non-union advanced collapse. MRI was superior to CT in early detection of avascular necrosis of proximal segment of scaphoid bone.

**Keywords:** Avascular Necrosis, Computed Tomography, Fracture, Magnetic Resonance Imaging, Scaphoid

---

## 1. Introduction

The scaphoid bone is one of the carpal bones of the wrist. It is situated between the hand and forearm on the thumb side of the wrist (also called the lateral or radial side). It forms the radial border of the carpal tunnel. The scaphoid bone is the largest bone of the proximal row of wrist bones, its long axis being from above downward, lateralward, and forward. It is situated between the proximal and distal rows of carpal bones and articulates with the radius, lunate, trapezoid, trapezium and capitate. [1]

Fractures of the scaphoid are the most common of the carpal bone injuries, because of its connections with the two rows of carpal bones. [1] The scaphoid can be slow to heal because of the limited circulation to the bone. Fractures of

the scaphoid must be recognized and treated quickly, as prompt treatment by immobilization or surgical fixation increases the likelihood of the bone healing in anatomic alignment, thus avoiding mal-union or non-union. Delays may compromise healing. Failure of the fracture to heal ("non-union") will lead to post-traumatic osteoarthritis of the carpus. [1] One reason for this is because of the "tenuous" blood supply to the proximal segment. [2]

Conventional radiographic imaging is the first imaging tool of choice in scaphoid fractures. [3] For scaphoid fractures, usually trabecular bridging and sclerosis at the fracture line are used to assess bony union. [4] Radiological diagnosis and evaluation of scaphoid fracture union are difficult, because of the unique shape, size and orientation of the bone. [4] In case of a scaphoid fracture, the appearance of

trabecular overcrossing of the fracture line may be incorrect as a result of overlapping of fracture fragments in the direction of the X-ray beam. [5, 6]

Scaphoid fractures may be missed on initial radiographs. Advanced imaging modalities such as computed tomography (CT) and magnetic resonance imaging (MRI) have improved diagnostic accuracy. [7]

CT scanning is excellent in the initial evaluation of a scaphoid fracture, particularly in a high-performance athlete in whom initial radiographic findings are normal. Also, CT scanning can demonstrate healing, which is sometimes misleading on radiographs, particularly with hardware in place. [8]

A section thickness of 1-2 mm is typical, whether sequence or spiral acquisition is used. One-millimeter scanning allows the production of excellent reformatted images. The oblique sagittal plane through the long axis of the scaphoid may be the preferred plane of orientation. [9]

Instead of CT scanning, MRI can be used as a screening tool for patients with negative radiographic results. Also, magnetic MRIs may define bone contusions rather than fracture as the source of pain. It has been used in the evaluation of complications, particularly osteonecrosis, but care should be emphasized in the diagnosis of avascularity, because some ischemia is expected in the proximal pole after waist and proximal-pole fractures. Typically, MRI is not useful in the evaluation of healing. [10]

Early diagnosis is critical to minimize complications including osteonecrosis. If the initial radiographs after the injury are inconclusive, early magnetic resonance imaging (MRI) provides an immediate diagnosis to allow for proper management. In the cases in which no scaphoid fracture is present, MRI provides alternate diagnoses such as identification of other fractures (e.g., other carpals and distal radius), osseous contusions, and soft tissue injuries (preferably  $\geq 1.5T$ ). [11]

The aim of the study was to compare between the diagnostic accuracies of Computed Tomography and Magnetic Resonance Imaging in detecting scaphoid fractures and its complications.

## 2. Methods

**Study Design, Setting, and Timing:** this study was carried out on 30 patients presented to private Hand clinic from October 2018 to December 2019, with clinical symptoms of tenderness in the anatomic snuffbox after wrist trauma and suspected to have scaphoid fracture in the plane X-ray. They were invited to enroll in a comparison of CT and MRI with regard to their diagnostic utility. The patients have been referred to Private medical diagnostic imaging center.

CT and MRI were separated into two groups and evaluated for the presence of a scaphoid fracture until a consensus opinion was reached. The images were blinded, randomly ordered according to a computer random-number generator, and reviewed in two rounds. In the first round, the CT scans were evaluated; in the second, the MRI were evaluated. The CT results during the MRI evaluation were blinded and MRI

results during the CT evaluation were also blinded.

### 2.1. Study Participants

the sampling technique for study participants was a convenience sampling technique. Study participants were collected from patients admitted to private hand clinic center and then referred to radiodiagnosis while suspected to have scaphoid fracture. Patients confirmed to have scaphoid fracture by multidetector CT (N = 29) and by MRI (N = 30) were included in this study.

### 2.2. Inclusion Criteria

Adult patients presenting with tenderness of the scaphoid in the anatomic snuffbox and scaphoid-specific radiographs with a minimum of three views.

### 2.3. Exclusion Criteria

Age less than eighteen years, Patients with any concurrent distal ulna, radius, or carpal fracture, Patients with previous scaphoid fracture, Rheumatoid arthritis, Cognitive dysfunction limiting clinical evaluation.

### 2.4. Data Collections

history, Clinical Examination, scaphoid specific radiographs. Detailed history with special emphasis on falling onto outstretched hands or sports activities or motor vehicle collisions. Clinical examination including general examination and local hand examination. Minimum of three views posteroanterior view with the wrist in ulnar deviation, lateral view with the wrist in 15° extension, lateral view with the wrist in 30° of pronation, posteroanterior view with the x-ray beam directed from distal to proximal and with the wrist positioned in 40° of angulation.

### 2.5. Imaging Technique

wrist non-enhanced computed tomography. Multidetector, high-resolution CT was performed in all patients using (64-slice CT-scan, Siemens, Munich, Germany) in the following sequence: high-resolution 0.5-mm slices section thickness. The scan covered the wrist from the distal radioulnar joint to the carpometacarpal joints. Patients were positioned in the “superman” position, prone with the affected arm above the body and the palm facing down. Reconstructions are made in planes, defined by the long axis of the scaphoid. Sagittal plane images of the scaphoid were defined as reconstructions that provided a lateral view of the scaphoid bone, as defined by the central longitudinal axis of the scaphoid. Coronal plane images were those that provided a posteroanterior view of the scaphoid in the anatomic plane and in line with the axis of the scaphoid.

Wrist MRI all MRI studies were performed with (open 1.5 Tesla MR scanner, Philips, Amsterdam, Netherlands). The standard scaphoid protocol (Sense wrist coil), with a slice thickness of 3 mm and field of view 12x12 mm, axial, sagittal and coronal planning with 10% gap for axial and

sagittal planning. Included the following series: localizer, Cor STIR, and Cor SE T1. The patient was positioned supine with the forearm and wrist alongside the body. The open MR scanner allowed for central placement of the hand relative to the magnetic field, resulting in improved image quality when compared with off-centered scanning in a conventional tube.

## 2.6. Analysis of CT Findings

presence of a sharp lucent line within the trabecular bone pattern, a break in the continuity of the cortex, a sharp step in the cortex, or a dislocation of bone fragments.

## 2.7. Analysis of MRI Findings

criteria for a bone fracture on MRI included the presence of a cortical fracture line, a trabecular fracture line, or a combination of both. Any extensive focal zone of edema without a clear cortical fracture line, comparable with that seen with a stress fracture, was discussed to decide if the findings represented a fracture or not.

## 3. Statistical Analysis

Data entry, coding, and analysis were conducted using PSW (20), IBM Corp. Released 2011. IBM SPSS Statistics for Windows, Version 20.0. Armonk, NY: IBM Corp.

Data of this study were of both quantitative and qualitative types. Quantitative data were expressed in Mean ( $\bar{x}$ ), and Standard Deviation (SD), while qualitative data were expressed in frequency, and percent (%).

Results of this study was presented through Descriptive statistics of socio-demographic and clinical characteristics of participants and also Comparative analysis between MRI and CT results which stratified onto six main comparisons: Dislocation fragments and pattern, Herbert classification, non - union (Slade and Dodds), humpback deformity, and SNAC Wrist, DISI and VISI configuration findings among participants and AVN grading of Proximal fragment, and SLAC Wrist (Watson staging) findings among participants.

Ethical Approval: the study procedures were reviewed and approved by the Research Ethics Committee (REC), Faculty of medicine, Menoufia University.

## 4. Results

This study included 30 patients with suspected scaphoid fracture, 29 of them were males (96.7%), one female (3.3%). Their ages ranged between 18 years to 66 years with a mean of 31.8 years (SD = 12.55 years), and a median of 38 years. Wrist non-enhanced multi-Detector Computed Tomography (MDCT) and wrist MRI were performed for study participants to compare their diagnostic accuracies in scaphoid fracture diagnosis and its complications. 50% of the patients presented with fracture proximal pole of the scaphoid while 36.7% of the patients had fracture waist and only 13.3 of the patients had fracture distal pole. 66.7% of the patients had a horizontal fracture and 33% of the patients presented with oblique fracture. Only 20% of the patients had structural destruction and 80% hadn't.

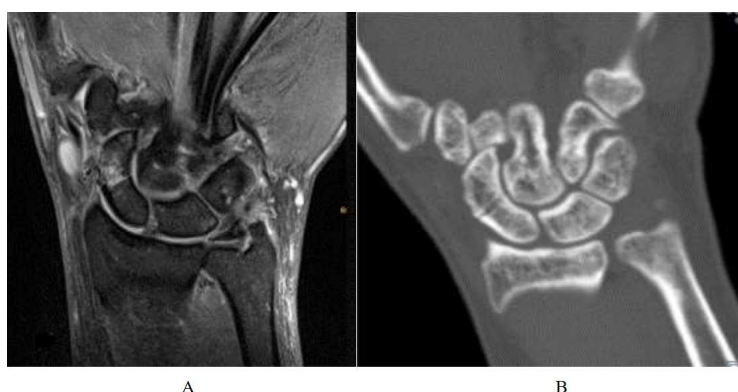This table showed that CT and MRI are equal in detecting fracture displacement with dislocation of fragments while according to pattern of fracture CT was superior in detection of cortical involvement in scaphoid fracture, MRI was superior in detection of trabecular fracture. (Table 1)

This table showed that there was significant difference between findings of CT & MRI as regards number of grade IV Slade and Dodds as it was higher among MRI than CT findings. On the other hand, there was no significant difference between findings of MRI and CT as regards other grades of non-union. (Table 2)

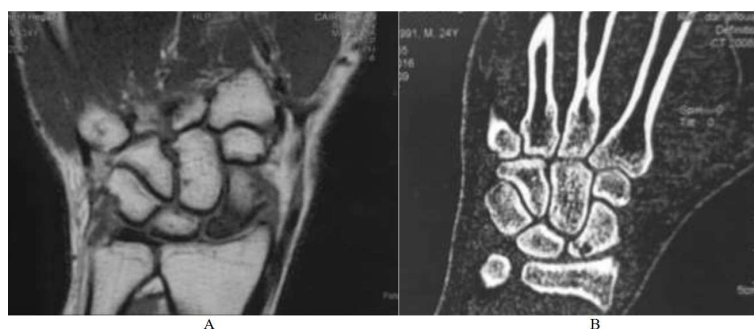Showed that there was no difference between findings of MRI and CT results as regards Humpback deformity. MRI was superior to CT in early detection of stage I Scaphoid non-union advanced collapse (SNAC wrist). (Figure 1)

Showed that there was a highly significant difference between findings of MRI and CT results as regards the diagnosis of avascular necrosis of proximal segment of scaphoid bone especially Grade I which is denoting bone marrow edema as it was higher among MRI than CT findings. On the other hand, there was no difference between findings of MRI and CT results as regards the other grades of AVN. (Figure 2)

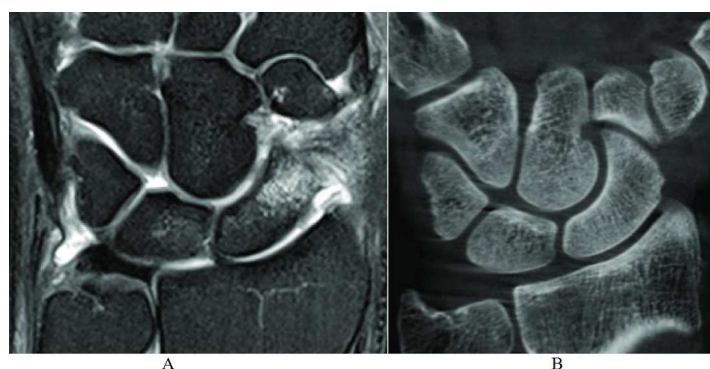
Showed that there was no difference between findings of MRI and CT results as regards the stages of Scapho-Lunate advanced collapse (SLAC wrist). (Figure 3)



**Figure 1.** A case of Fracture waist of scaphoid bone. Male patient 56 years old presented with painful swelling at the radial side of right wrist joint after acute wrist trauma A. Non-enhanced MSCT scan of right wrist joint Transverse non united fracture line at the waist of scaphoid bone (black arrow). B. MRI of right wrist joint The STIR images demonstrate significant bone marrow edema denoting recent fracture (white arrow).



**Figure 2.** A case of Fracture proximal pole of scaphoid bone with AVN grade II. Male patient 25 years old presented with pain and swelling at radial side of right wrist joint A. Non-enhanced MSCT scan of right wrist: Non-united fracture line is seen in proximal pole of scaphoid bone (black arrow). CT evidence of sclerosis of the proximal pole of scaphoid bone... AVN grade II. B. MRI of right wrist joint: Non-united fracture line is seen in proximal pole of scaphoid bone (white arrow) Areas of marrow edema along the fracture line, hypointense lines in the proximal pole of scaphoid bone denoting sclerosis but less are significant than MSCT.



**Figure 3.** A case of Trabecular fracture at distal pole of scaphoid bone with large area of marrow edema. Male patient 39 years old presented with radial side wrist pain A. Non-enhanced MSCT scan of right wrist joint: Normal appearance of scanned bones of wrist. No evidence of osteolytic, sclerotic lesion, cortical disruption or periosteal reaction. Normal CT appearance of the muscle groups with preserved inter muscular fat planes. B. MRI of right wrist joint: Trabecular fracture at distal pole of scaphoid bone. Large area of marrow edema appears hyper intense (white arrow).

**Table 1.** Showed comparative analysis between CT and MRI findings regards the non- union (Slade and Dodds) grading.

Non - union (Slade and Dodds)			Radiological procedure		$\chi^2$ test	P value
			MRI	CT		
Grade I	Present	Number	4	5	0.13	0.711
		%	44.4%	55.6%		
	Absent	Number	26	25	1.27	0.262
		%	51.0%	49.0%		
Grade II	Present	Number	7	11	0.30	0.581
		%	38.9%	61.1%		
	Absent	Number	23	19	6.40	0.011*
		%	54.8%	45.2%		
Grade III	Present	Number	11	9	---	----
		%	55.0%	45.0%		
	Absent	Number	19	21	0.000	1.00
		%	47.5%	52.5%		
Grade IV	Present	Number	8	1	---	----
		%	88.9%	11.1%		
	Absent	Number	22	29	0.000	1.00
		%	43.1%	56.9%		
Grade V	Absent	Number	30	30	---	----
		%	100.0%	100.0%		
Grade VI	Present	Number	1	1	0.000	1.00
		%	50.0%	50.0%		
	Absent	Number	29	29	0.000	1.00
		%	50.0%	50.0%		

MRI: Magnetic resonance imaging

CT: Computed tomography

%; Percent

\*: Significant

$\chi^2$ : Chi-square test.

**Table 2.** Showed comparative analysis between CT and MRI findings regards AVN grading.

Study variable				Radiological procedure		$\chi^2$ test	P value
				MRI	CT		
<i>Avascular Necrosis grading of proximal fragment</i>	Grade I	Present	Number	8	0	9.23	0.002*
			%	100.0%	0.0%		
		Absent	Number	22	30		
			%	42.3%	57.7%		
	Grade II	Present	Number	4	6	0.49	0.482
			%	40.0%	60.0%		
		Absent	Number	26	24		
			%	52.0%	48.0%		
	Grade III	Present	Number	1	0	1.01	0.311
			%	100.0%	0.0%		
		Absent	Number	29	30		
			%	49.2%	50.8%		
	Grade IV	Number	Number	3	1	1.07	0.301
			%	75.0%	25.0%		
		Number	Number	27	29		
			%	48.2%	51.8%		

MRI: Magnetic resonance imaging

CT: Computed tomography

%: Percent

\*: Significant

 $\chi^2$ : Chi-square test.

## 5. Discussion

In current study there were superiority of multidetector CT over MRI in detection of cortical involvement in scaphoid fractures but multidetector CT was inferior to MRI in detection of trabecular scaphoid fractures with high signal intensity denotes bone marrow edema. Our results in agreement with these studies:

The study of Zwart et al. [12] they found that results that CT isn't adequate in the diagnosis of trabecular scaphoid fractures.

The study of Ilica et al. [13] MDCT offers highly accurate results especially concerning cortical involvements. All of the missed fractures on MDCT were purely trabecular with no cortical discontinuity.

The study of Memarsadeghi et al. [14] MDCT is highly accurate in depicting occult cortical fractures but appears inferior to MRI in depicting solely trabecular injury. MRI is inferior to MDCT in depicting cortical involvement.

In our present study there was nearly no difference between MDCT and MRI in detection of fracture displacement and dislocation of fragments.

The study of Wijetunga et al. [15] matches with our study results that CT and MRI have equal sensitivity to displaced and nondisplaced fractures. The study preferred MRI due to its reduced radiation risk.

The study of Bäcker et al. [16] which recommend perform a CT scan to assess for displacement after the diagnosis of scaphoid fracture is already done by MRI.

The study of Clementson et al. [17] recommended CT if displacement or instability is suspected.

The study of Smith et al. [18] which demonstrates that the spatial resolution of CT is superior to MRI and therefore abler to detect displacements. The ACR recommend CT

imaging where displacement of the scaphoid fracture fragments is suspected despite normal radiographs.

In our present study we interpretate the Slade and Dodds grades of non-union as it is one of the commonest and risky complications of scaphoid fractures. The grading will also differ in the plan of treatment if it will be conservative or operative. We found that there was significant difference between findings of CT & MRI as regards number of grade IV Slade and Dodds as it was higher among MRI than CT findings. On the other hand, there was no significant difference between findings of MRI and CT as regards other grades of non-union. Also MRI was superior to CT in early detection of stage I Scaphoid non-union advanced collapse (SNAC wrist).

The study of Clementson et al. [17] demonstrated that magnetic resonance imaging (MRI) is recommended for diagnostics, while computed tomography (CT) has proven more reliable and accurate in the assessment of scaphoid fracture characteristics and union. CT with its higher spatial resolution and possibilities to reconstruct images in the longitudinal axis of the scaphoid, has been demonstrated as a more reliable method to assess bone union.

The study of Smith et al. [18] CT scan has been widely used in scaphoid non-union for assessing the fracture configuration, bony deformity and any concurrent osteoarthritis. This enables accuracy when planning surgical intervention. The images from a longitudinal CT scan provide the best assessment of the location and degree of collapse of the non-union, with the lateral intra-scaphoid angle and the height to length ratio helping identify angulation and collapse of the scaphoid.

The study of Slade et al. [19] showed that Scaphoid nonunions are not easy to categorize. They have been described by their anatomic location or with clinically specific terms such as stable, fibrous, sclerotic, unstable,

humpback, synovial, cystic, pseudarthrosis, or avascular. These descriptions frequently dictate specific treatment strategies. In an effort to match the healing potential of a nonunion to a specific treatment. New classification focuses on the width of the devitalized scaphoid zone and circumstances that complicate the healing process. Slade and Dodds Grading system reflects the natural degradation that occurs at a scaphoid nonunion site with time and the difficulties these changes pose to healing.

In our present study there was no difference between findings of MRI and CT results as regards Humpback deformity.

In contrary to the study of Smith et al. [18] demonstrates that CT scanning of the scaphoid in the longitudinal axis is now the preferred technique as it provides a greater appreciation of the anatomy and deformity including the humpback deformity.

In current study there was a highly significant difference between findings of MRI and CT results as regards the diagnosis of avascular necrosis of proximal segment of scaphoid bone especially Grade I which is denoting bone marrow edema as it was higher among MRI than CT findings. On the other hand, there was no difference between findings of MRI and CT results as regards the other grades of AVN. Our results match with the following studies:

The study of Bhat et al. [20] Initial reports utilizing unenhanced MRI to evaluate the proximal pole of the scaphoid were very favourable in terms of diagnosing AVN when correlated with histopathology.

The study of Xie et al. [21] MRI is the first and earliest imaging modality for detection of bone marrow edema of the proximal segment of scaphoid bone.

The study of Cheema et al. [22] MRI is the most reliable imaging modalities for assessing perfusion to the scaphoid in nonunions. In a head-to-head comparison of MRI vs the gold standard of intraoperative punctate bleeding, hypointensity on non-contrast T1-weighted-imaging of the proximal pole was 72% sensitive and 100% specific, in addition to having a 100% positive predictive value, and 73% negative predictive value for osteonecrosis. Furthermore, 90% of scaphoids with MRI findings in keeping with osteonecrosis were confirmed to have the same finding during surgery.

The study of Mallee et al. [23] MRI generates a strong magnetic field to align the hydrogen atoms in the body. This alignment is altered with use of radiofrequency pulses and can be detected to build the images. MRI was the first non-invasive method to create high-resolution images of the musculoskeletal system. In scaphoid injury, bone marrow oedema consists mainly of liquid with hydrogen atoms, and thus is well visualised.

The study of Bervian et al. [8] CT did not correlate strongly with a diagnosis of avascular necrosis of the proximal segment of the scaphoid, corroborating other studies that show conflicting results on this topic. This can be explained in part by the absence of a direct measurement of the radiation density, as Hounsfield units. MRI is considered the most reliable test for the pre-operative diagnosis of

avascular necrosis.

#### Limitations

This study has some limitations as the small sample size, which has a direct impact on the power of the study to examine differences and patterns of scaphoid fractures. Further studies should have larger sample sizes. Another limitation is the retrospective nature Therefore; our findings could form the basis for a larger prospective study in order to corroborate our results.

## 6. Conclusion

Multidetector CT had the superiority over MRI in detection of cortical involvement in scaphoid fractures but multidetector CT was inferior to MRI in detection of trabecular scaphoid fractures with high signal intensity denotes bone marrow edema.

MRI was superior to MDCT in early detection of stage I Scaphoid non-union advanced collapse (SNAC wrist).

MRI was superior to CT in early detection of avascular necrosis of proximal segment of scaphoid bone especially Grade I which is denoting bone marrow edema.

## 7. Recommendations

Our findings could form the basis for a larger prospective study.

## References

- [1] Beasley RW. *Beasley's Surgery of the Hand*. New York: Thieme. ISBN. 2003; 978-1-282-95002-3.
- [2] Eathorne SW. The wrist: Clinical anatomy and physical examination—An update. *Primary Care: Clinics in Office Practice*. 2005; 32 (1): 17-33.
- [3] Schmitt R, Rosenthal H. Imaging of Scaphoid Fractures According to the New S3 Guidelines. *Rofo*. 2016; 188 (5): 459-69.
- [4] Dias JJ. Definition of union after acute fracture and surgery for fracture nonunion of the scaphoid. *J Hand Surg Br*. 2001; 26 (4): 321–325.
- [5] Dias JJ, Taylor M, Thompson J, Brenkel IJ, Gregg PJ. Radiographic signs of union of scaphoid fractures. An analysis of inter-observer agreement and reproducibility. *J Bone Joint Surg Br*. 1988; 70 (2): 299–301.
- [6] Singh HP, Forward D, Davis TR, Dawson JS, Oni JA, Downing ND. Partial union of acute scaphoid fractures. *J Hand Surg Br*. 2005; 30 (5): 440–445.
- [7] Karl JW, Swart E, Strauch RJ. Diagnosis of occult scaphoid fractures: a cost-effectiveness analysis. *JBJS*. 2015; 97 (22): 1860-8.
- [8] Bervian MR, Ribak S, Livani B. Scaphoid fracture nonunion: correlation of radiographic imaging, proximal fragment histologic viability evaluation, and estimation of viability at surgery: diagnosis of scaphoid pseudarthrosis. *Int Orthop*. 2015; 39 (1): 67-72.

- [9] Querellou S, Arnaud L, Williams T, Breton S, Colin D, Le Roux PY, et al. Role of SPECT/CT compared with MRI in the diagnosis and management of patients with wrist trauma occult fractures. *Clinical nuclear medicine*. 2014; 39 (1): 8-13.
- [10] Larribe M, Gay A, Freire V, Bouvier C, Chagnaud C, Souteyrand P. Usefulness of dynamic contrast-enhanced MRI in the evaluation of the viability of acute scaphoid fracture. *Skeletal radiology*. 2014; 43 (12): 1697-703.
- [11] Murthy NS. The role of magnetic resonance imaging in scaphoid fractures. *The Journal of hand surgery*. 2013; 38 (10): 2047-54.
- [12] De Zwart AD, Beeres FJ, Rhemrev SJ, Bartlema K, Schipper IB. Comparison of MRI, CT and bone scintigraphy for suspected scaphoid fractures. *European Journal of Trauma and Emergency Surgery*. 2016; 42 (6): 725-31.
- [13] Ilica AT, Ozyurek S, Kose O, Durusu M. Diagnostic accuracy of multidetector computed tomography for patients with suspected scaphoid fractures and negative radiographic examinations. *Japanese journal of radiology*. 2011; 29 (2): 98-103.
- [14] Memarsadeghi M, Breitenseher MJ, Schaefer-Prokop C, Weber M, Aldrian S, Gäbler C, et al. Occult scaphoid fractures: comparison of multidetector CT and MR imaging—initial experience. *Radiology*. 2006; 240 (1): 169-76.
- [15] Wijetunga AR, Tsang VH, Giuffre B. The utility of cross-sectional imaging in the management of suspected scaphoid fractures. *Journal of medical radiation sciences*. 2019; 66 (1): 30-7.
- [16] Bäcker HC, Wu CH, Strauch RJ. Systematic review of diagnosis of clinically suspected scaphoid fractures. *Journal of wrist surgery*. 2020; 9 (01): 081-9.
- [17] Clementson M, Björkman A, Thomsen NO. Acute scaphoid fractures: guidelines for diagnosis and treatment. *EFORT open reviews*. 2020; 5 (2): 96-103.
- [18] Smith M, Bain GI, Turner PC, Watts AC. Review of imaging of scaphoid fractures. *ANZ journal of surgery*. 2010; 80 (1-2): 82-90.
- [19] Slade III JF, Dodds SD. Minimally invasive management of scaphoid nonunions. *Clinical Orthopaedics and Related Research*®. 2006; 445: 108-19.
- [20] Bhat AK, Acharya AM, Sourab SS. What Exactly is Avascular Necrosis in Nonunion Scaphoid?. *Journal of Karnataka Orthopaedic Association*. 2021; 9 (1): 02-7.
- [21] Xie C, Ather S, Mansour R, Gleeson F, Chowdhury R. Dual-energy CT in the diagnosis of occult acute scaphoid injury: a direct comparison with MRI. *European radiology*. 2021; 31 (6): 3610-5.
- [22] Cheema HS, Cheema AN. Radiographic evaluation of vascularity in scaphoid nonunions: A review. *World Journal of Orthopedics*. 2020; 11 (11): 475.
- [23] Mallee WH, Wang J, Poolman RW, Kloen P, Maas M, de Vet HC, et al. Computed tomography versus magnetic resonance imaging versus bone scintigraphy for clinically suspected scaphoid fractures in patients with negative plain radiographs. *Cochrane Database of Systematic Reviews*. 2015; 6: 11-15.