



***Helicobacter Pylori*-Negative Gastric Mucosa-Associated Lymphoid Tissue Lymphoma Treated with Radiation Therapy Alone**

Jose Ma. Hermoso Zalदारriaga, Don Peter Santiago Dator, Kenneth Cortez Sy

Department of Radiation Oncology, St. Luke's Medical Center, Quezon City, Republic of the Philippines

Email address:

jmaphzalदारriaga@stlukes.com.ph (Jose Ma. Hermoso Zalदारriaga)

*Corresponding author

To cite this article:

Jose Ma. Hermoso Zalदारriaga, Don Peter Santiago Dator, Kenneth Cortez Sy. *Helicobacter Pylori*-Negative Gastric Mucosa-Associated Lymphoid Tissue Lymphoma Treated with Radiation Therapy Alone. *International Journal of Clinical Oncology and Cancer Research*. Vol. 7, No. 4, 2022, pp. 93-98. doi: 10.11648/j.ijccocr.20220704.13

Received: November 19, 2022; **Accepted:** December 6, 2022; **Published:** December 15, 2022

Abstract: This is a case of a 60-year-old Filipino gentleman with a six-month-history of nonspecific gastric symptoms which would be ascribed to gastroesophageal reflux disease. Each time, the patient would be prescribed proton pump inhibitors, but with only temporary and minimal relief. Eventually, further investigation would reveal that the patient actually had gastric mucosa-associated lymphoid tissue lymphoma (MALToma). Peculiar, however, is that the patient's gastric MALToma is *Helicobacter pylori*-negative. The patient subsequently underwent involved-site radiation therapy to the entire stomach. A total of 3000 cGy in 20 fractions (150 cGy per fraction) was prescribed to the planning target volume, delivered using 6-megavoltage photons via volumetric modulated arc therapy (VMAT) modality in a Varian Halcyon linear accelerator. All the target criteria and organs-at-risk dose constraints were successfully met. Treatment was delivered daily, Mondays to Fridays. For every session, the patient was likewise asked to be nil per os 4 hours prior, similar to when he was simulated. Cone beam CT (CBCT) image verification was performed in every treatment session. The patient was prescribed Ondansetron 8 mg/tablet, 1 tablet orally, 1-2 hours prior to every radiation session, as prophylaxis against nausea and vomiting. The entire course of radiation therapy was well-tolerated. There were no treatment interruptions. The patient did not report any subjective complaints during and even after the course of treatment. Post-radiation therapy, there was complete clinical and endoscopic response.

Keywords: Gastric MALToma, Lymphoma, Radiation Therapy, Case Report

1. Introduction

Gastric mucosa-associated lymphoid tissue lymphoma (MALToma) is a rare form of non-Hodgkin lymphoma affecting the stomach. Majority of cases are associated with *Helicobacter pylori* infection. In a rare subset, however, the microorganism is not implicated in disease etiopathogenesis. What follows is a case of a *Helicobacter pylori*-negative gastric MALToma that has been treated with involved-site radiation therapy to the entire stomach, with complete clinical response thereafter. Subsequent to this is a brief discussion on the pertinent literature on the diagnosis, management, and the role of radiation therapy in this uncommon disease.

2. Case Presentation

R. P. P. is a 60-year-old Filipino male, previously well with no known comorbidities, who presented with a six-month-history of abdominal discomfort, bloating, and gassiness. These symptoms would be unrelated to food intake, would occur intermittently during the day, on most days of the week. He had seen two family physicians and one gastroenterologist already. Every time, he would be diagnosed with gastroesophageal reflux disease (GERD), prescribed proton pump inhibitors (PPIs) which would unfortunately provide only temporary and minimal relief. The patient works as a telecommunications executive, is a

never-smoker, but is an occasional alcohol beverage drinker consuming 2 bottles of beer per week. He has no family history of any malignancies nor any gastrointestinal diseases.

Due to the persistence of these symptoms, the patient sought consult with a fourth physician- a gastroenterologist- in May 2022. A urea breath test was performed which was negative for the detection of *Helicobacter pylori* infection.

The patient then underwent an esophagogastroduodenoscopy (EGD), which subsequently revealed patches of hyperemia as well as areas of pallor with mucosal breaks at the distal corpus of the stomach, compatible with erosive and atrophic gastritis (Figure 1). Biopsies of these lesions were subsequently obtained via cold forceps.

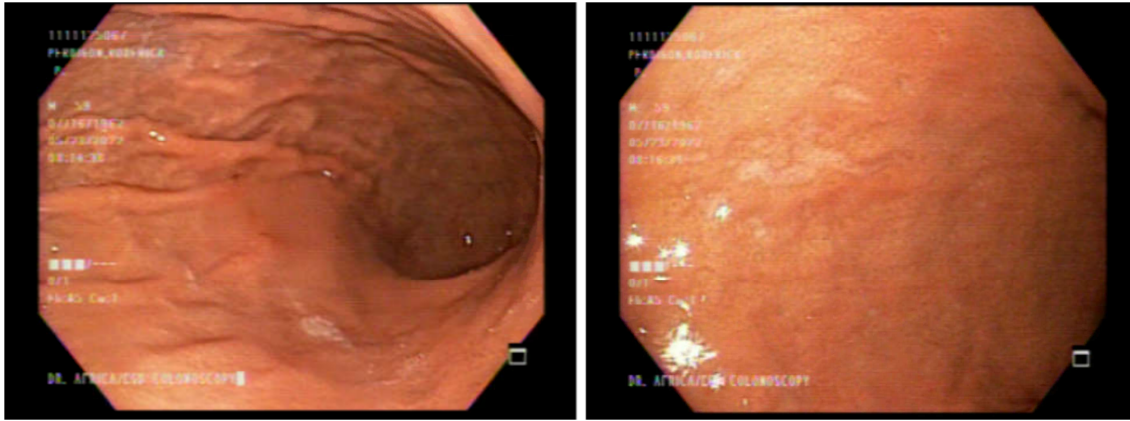


Figure 1. Patches of hyperemia and areas of pallor with mucosal breaks at the distal corpus.

No *Helicobacter pylori* was seen on Giemsa stain. However, on histopathology, atypical lymphoid proliferation was visualized. Hence, immunohistochemistry staining was subsequently performed. CD3, CD5, CD10, Cyclin D1, and Bcl2 staining were all negative. However, CD20 was positive and highlights focal lymphoepithelial lesions and glandular destruction. Ki-67 was also positive but with only low expression at 5%. This immunohistochemistry staining profile supports the diagnosis of an extranodal marginal zone lymphoma of the mucosa-associated lymphoid tissue (MALToma). Thereafter, the patient was referred to a medical oncologist.

Two weeks after, the patient underwent positron emission tomography/computed tomography (PET/CT) scan, which revealed no specific evidence of hypermetabolically active lymphoma. As such, the patient was diagnosed with *Helicobacter pylori*-negative Gastric MALToma, Stage I. The patient was then referred to our service for involved-site radiation therapy (ISRT).

2.1. Radiation Therapy

Prior to computed tomography (CT) simulation, the patient was asked to be on nil per os (NPO) for 4 hours, in order to prevent gastric distention and ensure reproducibility during the actual radiation therapy sessions. The patient was simulated with no oral nor IV contrast, in the treatment position (i.e. supine, head-first, arms up), under free breathing, with an abdominopelvic thermoplastic mask for immobilization, from the carina down to the pelvis.

The target volumes and organs-at-risk (OARs) were subsequently contoured. The clinical target volume (CTV) was defined as the entire stomach. The CTV was then expanded by 2 cm craniocaudally and 1 cm in all other directions to form the planning target volume (PTV), patterned after a multi-institution retrospective review of Gastric MALToma patients treated with ISRT from 2003 to 2015 [1]. The bowels, duodenum, liver, kidneys, and spinal cord were subsequently contoured as OARs (Figure 2).

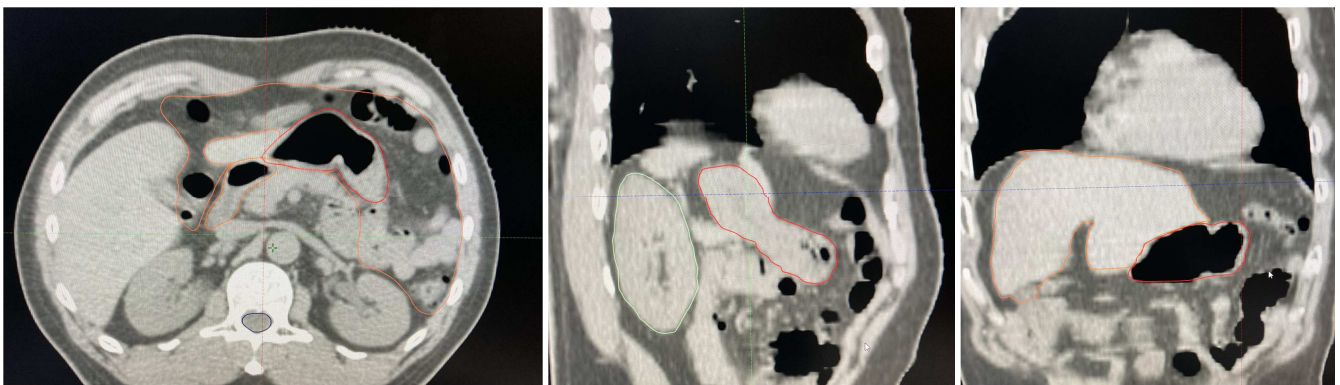


Figure 2. Contour of the Clinical Target Volume (CTV) (Red) and the OARs: Bowels (Peach), Duodenum (Brown), Liver (Orange), Kidneys (Lime), and Spinal Cord (Blue).

A total of 3000 cGy in 20 fractions (150 cGy per fraction) was prescribed to the PTV, delivered using 6-megavoltage photons via volumetric modulated arc therapy (VMAT) modality in a Varian Halcyon linear accelerator. All the target criteria and OAR dose constraints were successfully met (Tables 1 and 2).

Table 1. PTV criteria and planning values.

Target criteria	Goals	Value
Receiving prescribed dose (PD)	D95% \geq 95% of PD	D95% = 3000 cGy (100%)
Near minimum dose	D98% \geq 95% of PD	D98% = 2956 cGy (99%)
Near maximum dose	D2% \leq 107% of PD	D2% = 3153 cGy (100.05%)
Median dose	D50%	D50% = 3129 cGy
Homogeneity index (HI)	HI \leq 0.1	0.09
Conformity index (CI)	CI $<$ 2	0.96

Table 2. OAR dose constraints and planning values.

Organ-at-risk (OAR)	OAR dose constraint	Value
Kidney, Right	Mean dose $<$ 1500 - 1800 cGy	Mean dose = 538 cGy
	V12Gy $<$ 55%	V12Gy = 0.3%
	V20Gy $<$ 32%	V20Gy = 0.8%
	V23Gy $<$ 30%	V23Gy = 0.0%
	V28Gy $<$ 20%	V28Gy = 0.0%
Kidney, Left	Mean dose $<$ 1500 - 1800 cGy	Mean dose = 1023 cGy
	V12Gy $<$ 55%	V12Gy = 25%
	V20Gy $<$ 32%	V20Gy = 7%
	V23Gy $<$ 30%	V23Gy = 5%
	V28Gy $<$ 20%	V28Gy = 2%
Spinal Cord	Maximum dose $<$ 3600 cGy	Maximum dose = 1316 cGy
Bowels	V45Gy $<$ 195 cc	V45Gy = 0.0 cc
Liver	Mean dose $<$ 3000-3200 cGy	Mean dose = 1115 cGy
Duodenum	D100% $<$ 4500 cGy	D100% = 842 cGy

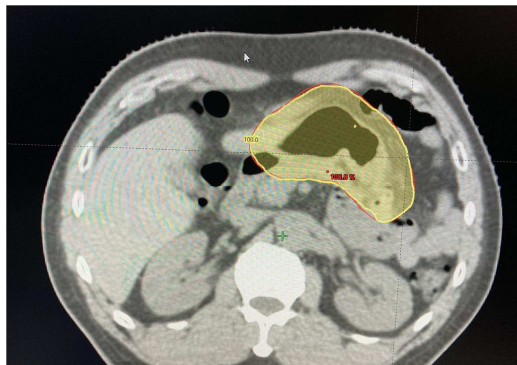


Figure 3. The 95% isodose color wash to the PTV.

Treatment was delivered daily, Mondays to Fridays. For every session, the patient was likewise asked to be NPO 4 hours prior, similar to when he was simulated. Cone beam CT (CBCT) image verification was performed in every treatment session. The patient was prescribed Ondansetron 8 mg/tablet, 1 tablet orally, 1-2 hours prior to every radiation session, as prophylaxis against nausea and vomiting.

The entire course of radiation therapy was well-tolerated. There were no treatment interruptions. The patient did not report any subjective complaints during and even after the course of treatment.

2.2. Follow-up

Upon completion of the entire course of radiation therapy, the patient noted complete resolution of the previously-noted

epigastric discomfort, bloating, and gassiness. A repeat EGD was performed by the same endoscopist 3 months post-radiation therapy. The previously visualized patches of hyperemia and areas of pallor with mucosal breaks at the distal corpus were no longer seen. The patient was advised another repeat EGD in 3 months for monitoring.

3. Discussion

Mucosa-associated lymphoid tissue lymphoma (MALToma) is a slow-growing non-Hodgkin lymphoma (NHL) that develops from B cells. It is a type of marginal zone lymphoma- a lymphoma that develops in a region at the edge of lymphoid tissues called the marginal zone. Isaacson and Wright were the first to report on extranodal marginal zone lymphoma of gastric origin in 1983 [2].

In adults, marginal zone lymphoma accounts for 5-17% of all NHLs; MALToma is the most frequent overall, being the third most frequent NHL and representing 7-8% of all B-cell neoplasms. It mostly affects middle-aged adults, at a median age of 60 years, with a slight female preponderance. Gastric MALToma is the most common and represents 30-40% of all extranodal lymphomas [3].

Prolonged antigenic stimulation either by infection or by an autoimmune process induces polyclonal B-cell proliferation and subsequent production of reactive oxygen species. Reactive oxygen species may induce a wide array of genetic abnormalities and combined with the proliferation of B lymphocytes increases the risk of DNA damage through double-strand breaks and translocations.

Genetic disorders frequently include the nuclear factor kappa B (NF- κ B) activation genes, a crucial transcription factor that controls the expression of multiple genes involved in B-cell survival and proliferation during immunological responses. The most prevalent structural chromosomal aberration found in 15-40% of MALToma cases is the t (11;18) (q21; q21) translocation. Lymphoepithelial lesions, which are highly indicative of MALToma, particularly gastric MALToma, are marked by invasion or necrotic destruction of the glandular epithelium by infiltrating lymphoma cells [4].

Microorganisms like *Helicobacter pylori*, *Helicobacter heilmannii*, Hepatitis C virus (HCV), *Campylobacter jejuni*, *Borrelia burgdorferi*, and *Chlamydia psittaci* are suspected to be connected to MALToma. *Helicobacter pylori* in particular has been found to be related to the development of gastric MALToma, accounting for 90% of all cases [1-2]. This suggests that 10% of gastric MALTomas develop without *H. pylori* infection. These *H. pylori*-negative gastric MALTomas' pathophysiology is yet unknown. There have been many speculations up to this point. NF- κ B activation may be caused, for instance, by genetic alterations. Among these changes, t (11;18) (q21;q21) is more frequently seen in gastric MALTomas that are *H. pylori*-negative. This translocation leads to the fusion of the N-terminus of the API2 gene to the C-terminus of the MALT1 gene, which results in the synthesis of an API2-MALT1 fusion protein, which in turn activates the NF- κ B in a canonical and non-canonical pathway. By causing the proteolytic cleavage of NF- κ B-inducing kinase (NIK), API2-MALT1 fusion protein activates NF- κ B through a noncanonical mechanism, leading to unregulated NIK activity and noncanonical NF- κ B activation. This genetic alteration may be the cause of *H. pylori*-negative gastric MALToma because the uncontrolled activation of NF- κ B causes carcinogenesis [1, 5].

About one-third of cases of extranodal marginal zone lymphoma involve the stomach, making it the organ most frequently affected. Salivary glands, orbits and ocular adnexa, thyroid, lungs, skin, breasts, liver, and other gastrointestinal sites besides the stomach are additional areas that frequently exhibit the condition. It has been shown that up to 25% of patients with gastric MALToma have disseminated disease [4]. The high rate of relapse in the gastric stump following surgical excision may be explained by the fact that gastric MALToma is frequently multifocal. About 10% of patients have synchronous involvement of the gastrointestinal and extraintestinal sites [5]. Nonspecific dyspepsia, epigastric discomfort, and nausea are common symptoms of gastric MALToma. With iron deficiency anemia getting increasingly worse, chronic bleeding may become apparent. Although any part of the stomach can be affected, the antrum is the part of the organ that is most frequently involved. Macroscopic characteristics of this lymphoma are nonspecific and include intragastric nodularities, enlarged rugal folds, thickened gastric walls, irregularly shaped superficial erosions, and shallow ulcers [4].

Esophagogastroduodenoscopy screening is the

conventional method for detecting gastric MALToma lesions. It is prudent to check for *H. pylori* via a stomach biopsy or urea breath test, and if positive at baseline, repeat the test following treatment. It is also advised to use endoscopic ultrasound to assess the invasion of the stomach wall and regional lymph nodes. Although optional, fluorescence in situ hybridization for t (11;18) can help direct treatment and response to antibiotic therapy. The endoscopic results are divided into four categories: superficial-spreading, mass-forming, diffuse infiltrating, and unclassified. Of these, the superficial-spreading type responds to antibiotic treatment the best. Even though many gastric MALToma lesions resemble early stomach malignancies endoscopically, it is important to distinguish between the two because each illness has a different course of treatment. Endoscopic ultrasonography is used to gauge the depth of the afflicted lesion. Because stomach MALT lymphomas with deep submucosal invasions respond less well to eradication therapy, depth examination is crucial. Histopathology provides a conclusive diagnosis for gastric MALTomas [1, 3] Fischbach (2014) stated that at least 10 samples are necessary considering that it is crucial to perform an adequate number of biopsies from the lesions in order to make an accurate diagnosis and rule out the potential of diffuse large B cell lymphomas [6]. Immunostaining for B-cell markers can aid in diagnosis in addition to histopathology.

Regardless of presentation, stage, or histologic grade, *H. pylori* eradication therapy should be given to all patients with *H. pylori*-positive MALTomas. At least 6 weeks after the end of the eradication therapy and at least 2 weeks after stopping the use of proton pump inhibitors, the efficacy of the *H. pylori* eradication must be verified by urea breath testing. The use of antibiotics is based on local antibiotic resistance patterns as well as the epidemiology of the infection in the patient's country of residence. The most popular method relies on three medications taken for 10 to 14 days: a proton pump inhibitor, together with either amoxicillin or metronidazole and clarithromycin. The eradication of *H. pylori* frequently results in a complete remission of the lymphoma on its own without the need for any additional treatment in approximately 75% of cases [1], thus fulfilling all four of Koch's postulates and proving the microbe as the primary causative cause. Infection with microorganisms other than *H. pylori* is another proposed causative factor. This may help to explain why some patients with gastric MALToma who are *H. pylori*-negative can be cured by *H. pylori* eradication therapy.

Alternative therapies should be considered for patients with nongastric MALTomas and gastric MALTomas who do not respond to *H. pylori* eradication or who have no signs of *H. pylori* infection. There is no evidence-based consensus yet, on the best alternative therapy approaches. For localized illness, involved-site radiation therapy (ISRT) is a viable option. The prognosis for MALToma is often favorable, with most series reporting 5-year overall survival rates of more than 85%. Compared to non-gastrointestinal lymphomas,

gastric MALTomas appear to have a longer reported median time to progression, but no discernible variations in overall survival have been found between the two disease groupings [4]. According to several reports, patients with gastric MALTomas who get radiation had 5-year cause-specific survival rates of 80–100% [7-11]. Nam et al. (2014) reported on 34 patients diagnosed with gastric MALToma and treated with radiotherapy alone who had 5-year overall survival and cause-specific survival rates between 90.3 to 100%. [7]. Similarly, Kim et al. (2013) reported on 33 patients, of whom 17 were *H. pylori* negative, who had complete remission within 15 months of radiotherapy. No local relapse occurred and the 5-year local progression-free survival was 100% [8]. Ohkubo et al. (2017) reported on 13 patients receiving radiotherapy alone who had a 5- and 10-year overall survival rate of 92% and 87% respectively. With regards to toxicity, commonly reported were nausea, vomiting, dyspepsia, anorexia, diarrhea, and/or abdominal pain [12-14]. Acute toxicities occurred 3 months after RT but were brief, controllable, and did not interfere with the course of treatment [14-16].

4. Conclusion

MALToma is a slow-growing non-Hodgkin lymphoma that develops from B cells. It is a type of marginal zone lymphoma, a lymphoma which develops in a region at the edge of lymphoid tissues called the marginal zone. Marginal zone lymphoma accounts for 5 to 17 percent of all NHLs. Gastric MALToma is the most common and represents 30% to 40% of extranodal lymphomas. The most prevalent structural chromosomal aberration found in 15 to 40 percent of MALToma cases is the t (11;18) (q21;q21) translocation. This results in the synthesis of an API2-MALT1 fusion protein, which in turn activates the NF- κ B in a canonical and non-canonical pathway. NF- κ B controls genes responsible for proliferation of B-cells.

One-third of cases of gastric MALT lymphoma involve the stomach, making it the organ most frequently affected. Salivary glands, orbits and ocular adnexa, thyroid, lungs and other gastrointestinal sites besides the stomach are additional areas that frequently exhibit the condition. About 10% of patients have synchronous involvement of the gastrointestinal and extraintestinal sites. Nonspecific dyspepsia, epigastric discomfort, and nausea are common symptoms of gastric MALT lymphoma. Histopathology remains the gold standard for diagnosing gastric MALToma; however, direct visualization and cytogenetic tests may aid in the management and rule out other similar diseases as well. Antibiotic therapy remains the mainstay of treatment for gastric MALTomas that are *H. pylori* positive. For cases that are either *H. pylori* positive but unresponsive to antibiotic therapy or *H. pylori* negative, involved-site radiation therapy is a feasible option, with control and overall survival rates up to 100% with minimal and manageable toxicities.

Statements

Author's Contributions

JHZ, DPSD, and KSY conceived of the discussed topic; JHZ and DPSD drafted the initial paper; KSY made the final revisions to the final paper.

Consent for Publication

As the corresponding author, I confirm that the manuscript has been read by and approved for submission by all authors. Written informed consent was obtained from the patient for publication of this case report and all accompanying images.

Conflicts of Interest

The authors declare no conflict of interest.

References

- [1] Asano, N. (2015). Helicobacter pylori -negative gastric mucosa-associated lymphoid tissue lymphomas: A review. *World Journal of Gastroenterology*, 21 (26), 8014. <https://doi.org/10.3748/wjg.v21.i26.8014>
- [2] Zullo, A., Hassan, C., Ridola, L., Repici, A., Manta, R., and Andriani, A. (2020). Gastric MALT lymphoma: Old and new insights. *Annals of Gastroenterology*, 7.
- [3] Violeta, F. (2018). MALT lymphoma: Epidemiology, clinical diagnosis and treatment. *Journal of Medicine and Life*, 11 (3), 187–193. <https://doi.org/10.25122/jml-2018-0035>
- [4] Press, O. W., and Lichtman, M. A. (2017). General Considerations of Lymphomas: Epidemiology, Etiology, Heterogeneity, and Primary Extranodal Disease. In O. W. Press, M. A. Lichtman, & J. P. Leonard (Eds.), *Williams Hematology Malignant Lymphoid Diseases* (Vol. 1–Book, Section). McGraw-Hill Education. hemonc.mhmedical.com/content.aspx?aid=1148368200
- [5] Lim, H. W., Kim, T. H., Choi, I. J., Kim, C. G., Lee, J. Y., Cho, S. J., Eom, H. S., Moon, S. H., & Kim, D. Y. (2016). Radiation therapy for gastric mucosa-associated lymphoid tissue lymphoma: Dose-volumetric analysis and its clinical implications. *Radiation Oncology Journal*, 34 (3), 193–201. <https://doi.org/10.3857/roj.2016.01865>
- [6] Fischbach, W. (2014). Gastric MALT lymphoma—Update on diagnosis and treatment. *Best Practice & Research. Clinical Gastroenterology*, 28 (6), 1069–1077. <https://doi.org/10.1016/j.bpg.2014.09.006>
- [7] Nam, T.-K., Ahn, J.-S., Choi, Y.-D., Jeong, J.-U., Kim, Y.-H., Yoon, M. S., Song, J.-Y., Ahn, S.-J., & Chung, W.-K. (2014). The Role of Radiotherapy in the Treatment of Gastric Mucosa-Associated Lymphoid Tissue Lymphoma. *Cancer Research and Treatment: Official Journal of Korean Cancer Association*, 46 (1), 33–40. <https://doi.org/10.4143/crt.2014.46.1.33>
- [8] Kim, S. W., Lim, D. H., Ahn, Y. C., Kim, W. S., Kim, S. J., Ko, Y. H., & Kim, K.-M. (2013). Clinical outcomes of radiation therapy for early-stage gastric mucosa-associated lymphoid tissue lymphoma. *World Journal of Gastroenterology: WJG*, 19 (36), 6062–6068. <https://doi.org/10.3748/wjg.v19.i36.6062>

- [9] Ohkubo, Y., Saito, Y., Ushijima, H., Onishi, M., Kazumoto, T., Saitoh, J., Kubota, N., Kobayashi, H., Maseki, N., Nishimura, Y., & Kurosumi, M. (2017). Radiotherapy for localized gastric mucosa-associated lymphoid tissue lymphoma: Long-term outcomes over 10 years. *Journal of Radiation Research*, 58 (4), 537–542. <https://doi.org/10.1093/jrr/rrw044>
- [10] Yahalom, J., Xu, A., Noy, A., Lobaugh, S., Chelius, M., and K. Chau et al. (2021). Involved-site radiotherapy for *Helicobacter pylori*-independent gastric MALT lymphoma: 26 years of experience with 178 patients. *Blood Advances*, 5 (7), 1830–6. <https://doi.org/10.1182/bloodadvances.2020003992>
- [11] Olszewski, A. and J. Castillo. (2013). Comparative outcomes of oncologic therapy in gastric extranodal marginal zone (MALT) lymphoma: analysis of the SEER-Medicare database. *Annals of Oncology*, 24 (5): 1352–59. <https://doi.org/10.1093/annonc/mds644>
- [12] Tsang, R. W., Gospodarowicz, M. K., Pintille, M., Bezjak, A., Wells, W., Hodgson, D., and M. Crump. (2001). Stage I and II malt lymphoma: results of treatment with radiotherapy. *International Journal of Radiation Oncology, Biology, Physics*, 50 (5): 1258–64. [https://doi.org/10.1016/S0360-3016\(01\)01549-8](https://doi.org/10.1016/S0360-3016(01)01549-8)
- [13] Lee, S. K., Lee, Y. C., Chung, J. B., Chon, C. Y., Moon, Y. M., and J. K. Kang et al. (2004). Low grade gastric MALTOMA: Treatment strategies based on 10 year follow-up. *World Journal of Gastroenterology*, 10 (2): 223–6. doi: 10.3748/wjg.v10.i2.223
- [14] Vrieling, C., de Jong, D., Boot, H., de Boer, J. P., Wegman, Froukje, and B. M. P. Aleman. (2008). Long-term results of stomach-conserving therapy in gastric MALT lymphoma. *Radiotherapy and Oncology*, 87 (3): 405–11. <https://doi.org/10.1016/j.radonc.2008.02.012>
- [15] Schechter, N. and J. Yahalom. (2000). Low-grade MALT lymphoma of the stomach: a review of treatment options. *International Journal of Radiation Oncology, Biology, Physics*, 46 (5): 1093–103. [https://doi.org/10.1016/S0360-3016\(99\)00522-2](https://doi.org/10.1016/S0360-3016(99)00522-2)
- [16] Aleman, B. M. P., Haas, R., and R. van der Maazen. (2010). Role of radiotherapy in the treatment of lymphomas of the gastrointestinal tract. *Best Practice & Research Clinical Gastroenterology*, 24 (1): 27–34. <https://doi.org/10.1016/j.bpg.2009.12.002>