

## Research Article

# Suprascapular Nerve: Anatomical and Clinical Study

El Sayed Aly Mohamed Metwally<sup>1,\*</sup>, Rasha Mohamed Elshenety<sup>1</sup>, Bahaa Ahmed Motawea<sup>2</sup>

<sup>1</sup>Department of Anatomy and Embryology, Faculty of Medicine, Alexandria University, Alexandria, Egypt

<sup>2</sup>Orthopaedic Department, Faculty of Medicine, Alexandria University, Alexandria, Egypt

### Email address:

sayedmetwally2020@yahoo.com (E. S. A. M. Metwally)

\*Corresponding author

### To cite this article:

El Sayed Aly Mohamed Metwally, Rasha Mohamed Elshenety, Bahaa Ahmed Motawea. Suprascapular Nerve: Anatomical and Clinical Study. *International Journal of Clinical and Experimental Medical Sciences*. Vol. 2, No. 3, 2016, pp. 31-39. doi: 10.11648/j.ijcems.20160203.11

**Received:** March 23, 2016; **Accepted:** March 30, 2016; **Published:** April 25, 2016

**Abstract:** The suprascapular nerve arises from the upper trunk (Erb's point) of the brachial plexus in the posterior triangle of the neck. This research was conducted to study the anatomy of the suprascapular nerve in the scapular region and its relation to both suprascapular and spinoglenoid notches. This data is very important in suprascapular nerve block and suprascapular nerve surgical decompression. Dissection of 20 scapular regions of 10 formalin preserved male cadavers was done. Also thirty three adult patients; 26 males and 7 females suffering from vague shoulder pain subjected to suprascapular nerve surgical decompression. In all cadaveric specimens, careful dissection and anatomical study of suprascapular nerve regarding its course, distribution and relations was carried out. Origin of the nerve was demonstrated from upper trunk of the brachial plexus. Passage of the nerve through a narrow medial compartment of supraglenoid canal in all cases has been identified. Measurements of two important diameters relevant to suprascapular notch were also reported. The transverse scapular ligament was identified to be of uniform thickness. In the clinical study of all cases with suprascapular nerve entrapment regardless its etiology whether idiopathic or not, conservative therapy by means of the exercise was of limited value especially for the motor affection. All of the cases were subjected to surgical maneuverer to decompress the nerve. It is concluded that the anatomical findings allow better choice of the surgical procedure, more precise surgical dissection, better results and fewer complications.

**Keywords:** Suprascapular Nerve, Suprascapular Notch, Spinoglenoid Notch, Suprascapular Nerve Entrapment, Suprascapular Nerve Block

## 1. Introduction

The suprascapular nerve arises from the upper trunk (Erb's point) of the brachial plexus in the posterior triangle of the neck. Its root value is C5&6. The suprascapular nerve and vessels reach the suprascapular notch of the upper border of scapula. The suprascapular nerve enters the supraspinous fossa by passing through the suprascapular foramen which is formed by the suprascapular notch and the transverse scapular ligament.<sup>1</sup>

The suprascapular nerve supplies sensory fibers to about 70% of the shoulder joint, including the superior and posterosuperior regions of the shoulder and the acromioclavicular joints.<sup>2</sup>

The suprascapular nerve is liable to be compressed where it

crosses osteofibrous canals at the suprascapular and at the spinoglenoid notches.<sup>3</sup> Compression by tumors and ganglion cysts, traction injuries, direct trauma such as fracture of scapula and variations in anatomical course of the nerve have been reported as the causes of suprascapular nerve entrapment.<sup>4-6</sup>

Suprascapular nerve entrapment is characterized by pain in the posterolateral region of the shoulder, atrophy of the infraspinatus and supraspinatus muscles and weakness of the arm's external rotation and abduction. 1-2% of shoulder pain is caused by the entrapment of the suprascapular nerve, and therefore can be easily overlooked in the differential diagnoses of shoulder discomfort.<sup>7</sup> The diagnosis of the entrapment

syndrome is based on the history, physical findings and the abnormal electromyography findings for the affected muscles.<sup>8</sup>

The syndrome is treated via non-operative procedures, such as the avoidance of activities that result in irritation to the nerve and a rehabilitation program<sup>8</sup> or the surgical decompression of the suprascapular nerve.<sup>4</sup>

Suprascapular nerve block has shown some promise as an alternative treatment for patients with shoulder pain.<sup>7</sup>

Anatomical variations in the course of the suprascapular nerve are important for possible entrapment of the nerve, especially for individuals who are involved in violent overhead activities, such as volleyball players and baseball pitchers. Therefore, thorough investigations of suprascapular nerve at these sites are needed.

## 2. Material & Methods

### 2.1. Materials and Subjects

**Anatomical study:** This study was conducted by anatomical dissection of 20 scapular regions of 10 formalin preserved male cadavers obtained from the Anatomy Department, Faculty of Medicine, Alexandria University. None of these shoulder specimens showed any evidence of past history of trauma or previous surgical intervention. They were exposed and carefully dissected.


The specimens were placed in a prone position and a standard posterior approach to the shoulder joint was utilized. A linear incision was made from the posterolateral corner of the acromion medially along the length of the scapular spine. The skin, soft tissue, and fascia were removed. The deltoid and trapezius muscles were detached from their attachment from medial to lateral and reflected inferiorly allowing for visualization of the supraspinatus and infraspinatus muscles. Both of them were cut and retracted medially to allow visualization of the supraspinous and infraspinous fossae.

The suprascapular nerve was identified and traced as it passes inferior to the superior transverse ligament, across the supraspinous fossa, the spinoglenoid notch and infraspinous fossa. The suprascapular artery was identified and traced as it runs over the superior transverse ligament.

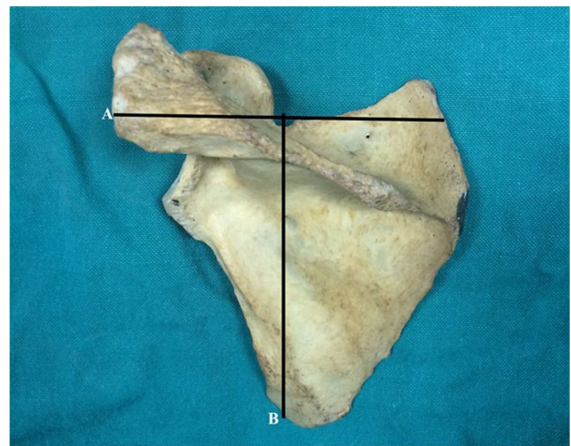
Measurements were taken by using Vernier Caliper (with an accuracy up to 0.05 mm) to measure the distance of the suprascapular foramen from fixed landmarks (Figure 1 & 2).

**Clinical study:** From December 2012 to October 2015, thirty three adult patients; 26 males and 7 females, with a mean age of 40 years (17 to 67 years) suffering from vague shoulder pain attending the orthopedic outpatient clinic of El Hadra University Hospital. All of them were diagnosed clinically and via investigations to have suprascapular nerve entrapment. The right shoulder was involved in thirty two patients, of whom it was the dominant side and the left shoulder in only one patient. Seven of them had a past history of trauma of the affected shoulder (Figure 3), eight patients with a ganglion cyst (Figure 4), ten patients due do repetitive sports injuries in overhead activities while the

remaining eight patients had idiopathic entrapment.



**Figure 1.** A photograph of the left scapular region showing Vernier caliper used for measuring the horizontal diameter from the lower end of lateral border of acromion (A) till the suprascapular notch (→). SN: suprascapular nerve, V: suprascapular vessels, C: clavicle, SS: supraspinatus muscle.



**Figure 2.** A photograph of left scapula showing a horizontal line (A) that extends transversely from just above the lower end of the lateral border of acromion and a vertical line (B) that extends vertically along the most prominent point of the spine of scapula. The point of intersection between the horizontal line (A) and the vertical line (B) indicates the site of safe reach to the suprascapular notch.

Function was assessed by the rating system of Constant and Murley.<sup>9</sup> All patients presented with deep, diffuse posterolateral pain in the shoulder, which was radiating to the upper arm and the neck. All patients reported tenderness on palpation over the suprascapular and spinoglenoid notches. The strength was measured according to Narakas<sup>10</sup> with weights applied at the wrist with pronated forearm, extended elbow and 90° abducted arm in the plane of the scapula. Up to 11 kg weight, maintained for five seconds, five times should be considered. The average abducting force before surgical treatment was 2 kg (0 to 3). Wasting of the supraspinatus and infraspinatus muscles was graded based on subjective assessment as mild, moderate, and severe with obvious atrophy of the muscle mass in both fossae. A total of 23 out of 33 patients had wasting of both muscles; moderate atrophy in eight and severe in 15. Seven patients out of 33 had isolated atrophy of the infraspinatus muscle; mild in one and moderate in six. Both muscles appeared normal in only

three patients.

The diagnosis was confirmed by electrophysiological studies in all 33 patients. In 23 patients signs of nerve degeneration were found. Isolated denervation of the infraspinatus muscle was seen in only seven patients while the remaining three it was inconclusive. In all patients plain radiography, CT and MRI were carried out. In seven patients plain radiograph and CT showed united fracture in the region of suprascapular notch with callus formation (Figure 3). In eight cases, MRI showed a ganglion cyst in the region of suprascapular notch extending to supraspinous fossa (Figure 4). In the remaining 18 cases, imaging studies were free.

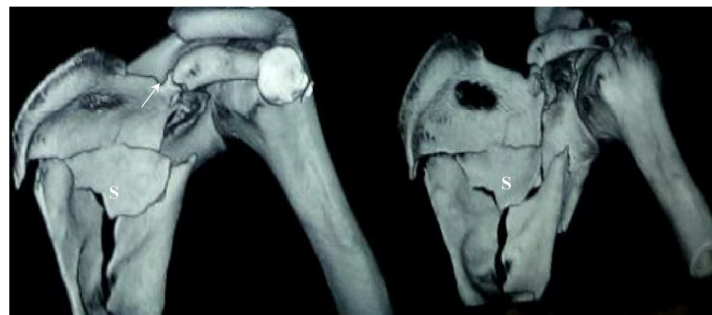According to the international guidelines, a two months conservative trial was followed in all cases through active muscular exercise and a course of anti-inflammatory and neurotonic drugs. In all cases, surgical intervention was done after the failure of the previous conservative trial. The patients were placed in a semiprone position, then a posterior skin incision parallel and slightly cephalad to the spine of the scapula approximately 10 to 12 cm in length was done (Figure 5 A). The trapezius muscle was split in the axis of its fibers. The fibers of the trapezius were elevated and retracted cephalad with a wide blunt retractor separating it from the supraspinatus muscle in the plane of a thin fatty layer separating them. With blunt dissection using a wet, gloved index finger, the suprascapular ligament was located overlying its notch. Only minimal distal retraction of the supraspinatus muscle was required (Figure 5 B). The suprascapular ligament was sharply released with care being

taken to avoid injuring the suprascapular artery and vein immediately superficial to it and protecting the suprascapular nerve beneath (Fig 5 C). Further exploration of the nerve or neurolysis was done if needed to ensure complete decompression. The trapezius muscle was repaired and the wound was closed in the routine manner. Active range of motion was allowed as tolerated on the first day postoperative.<sup>11</sup> The same posterior approach was extended to expose the spinoglenoid notch and infraspinous fossa in seven patients in whom preoperative electrophysiological studies had shown isolated involvement of the infraspinatus. The suprascapular nerve was decompressed then the infraspinatus muscle was retracted distally and spinoglenoid ligament was excised.

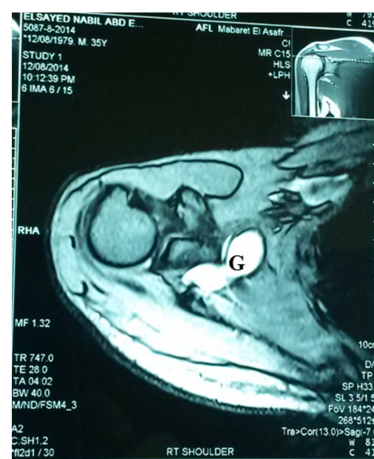
During dissection, careful inspection and palpation was done to rule out any abnormal masses. Eight ganglion cysts were found and excised; five of them arising in the suprascapular notch and three arising from the posterior glenohumeral joint caused entrapment of the suprascapular nerve in the spinoglenoid notch. And in these three cases, the deltoid and trapezius insertions were detached to facilitate excision of these ganglion cysts.<sup>11</sup>

## 2.2. Statistical Analysis

The results obtained were analyzed using SPSS program (version 17.0) and expressed as mean and standard deviation (SD). Statistical significance ( $P < 0.05$ ) among the groups was determined by one way ANOVA.

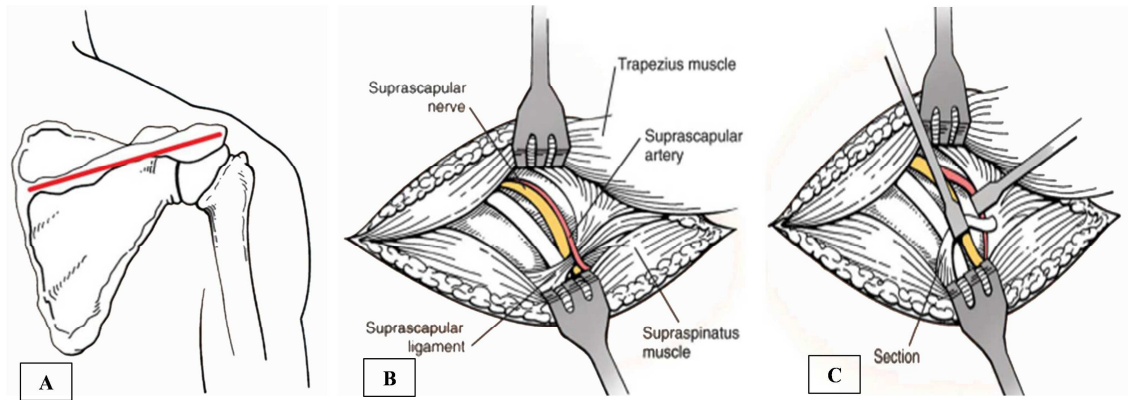


**Figure 3.** A reconstruction CT coronal cut of the left shoulder showing comminuted fracture of scapula (S) causing posttraumatic suprascapular nerve entrapment at the suprascapular notch (→).



**Figure 4.** MRI axial cut of the right shoulder showing lobulated contour suprascapular ganglion cyst (G) measuring 2x5.2 cm extending inferiorly along the course of the suprascapular nerve.





**Figure 5.** Posterior surgical approach. A, Skin incision. B, Supraspinatus muscle retracted downward to bring into view suprascapular artery and nerve. C, Suprascapular artery and transverse scapular ligament are isolated, permitting easy removal of ligament.<sup>11</sup>

### 3. Results

#### 3.1. Anatomical Results

##### I. Origin of suprascapular nerve:

In all the specimens, the suprascapular nerve originates from the upper trunk of the brachial plexus, which also gives the upper subscapular nerve. (Figure 6)

##### II. Course and distribution of suprascapular nerve:

The suprascapular nerve runs parallel to the inferior belly of omohyoid muscle. It enters the suprascapular notch inferior to the transverse scapular ligament which separates it from the suprascapular artery (Figure 7). The transverse scapular ligament separates the suprascapular vessels above from the suprascapular nerve below. In all the specimens, the subscapularis muscle was anterior to the suprascapular notch and partially covers the lower part of this notch (Figure 7). It enters the supraspinous fossa deep to the supraspinatus muscle, supplying it from its deep surface (Fig 8) then it passes through the spinoglenoid foramen (Figure 9).

The spinoglenoid foramen was bounded by the spine of scapula superiorly, back of the neck of the glenoid cavity laterally and infraspinatus muscle inferiorly. It was divided by a fascial septum (spinoglenoid ligament or inferior transverse scapular ligament) into a larger lateral and smaller medial compartments. In all the specimens, the suprascapular nerve and vessels passed through the medial compartment (Figure 10). Immediately after the nerve emerges from the spinoglenoid foramen, it supplies the infraspinatus muscle from its deep surface and was accompanied by suprascapular vessels (Figure 10).

In all the specimens the suprascapular nerve crossed the infraspinous fossa from lateral to medial.

##### III. The thickness of transverse scapular ligament:

The thickness of transverse scapular ligament as measured by Vernier caliber, was in an average of 9.84mm (range 8.11-11.3 mm) (Table 1).

##### IV. Measurements to fixed landmarks:

The vertical diameter which extends from the most prominent point on the spine to the upper border of the scapula was in an average of 2.5 cm (range 2.4-2.8 cm). The horizontal diameter which extends from just above the lower end of the

lateral border of the acromion till the suprascapular notch (→) was in an average of 4.8 cm (range 4.5-5.2 cm) (Table 2).

**Table 1.** Thickness of transverse scapular ligament in 20 scapular region specimens in mm.

Thickness in mm	Number of specimens	Percentage
8-	6	30%
9-	7	35%
10-	4	20%
11+	3	15%
Total	20	100%
Range	8.11-11.3	
Mean	9.84	
S.D.	0.88	

**Table 2.** Measurements of vertical and horizontal diameters in 20 scapular region specimens in cm.

Vertical diameter in cm			Horizontal diameter in cm		
Range of vertical diameter (cm)	No.	%	Range of horizontal diameter (cm)	No.	%
<2.5	3	15.0	<4.6	3	15.0
2.5-	5	25.0	4.6-	4	20.0
2.6-	7	35.0	4.7-	6	30.0
2.7-	3	15.0	4.8-	4	20.0
2.8+	2	10.0	4.9+	3	15.0
Range	2.4-2.88			4.52-5.22	
Mean	2.64			4.68	
S.D.	0.123			0.811	

#### 3.2. Clinical Results

A final examination of the thirty three cases was made at a mean follow-up of 42 weeks (20 to 94) after the operation. Constant score shows, no difference according to the etiology. There were no intraoperative or postoperative complications (table 3).

**Effects of the surgery on pain:** On the subjective scale, 25 of the 33 patients who had pain before the operation had none at the final review (15 points). One still had slight pain (13 or 14 points) and seven had moderate pain (10 to 12 points).

**Effects of the surgery on the daily activities:** Twenty seven of the 33 patients who overexerted their shoulder due to overuse, were able to participate in all of their previous

activities without restriction, the remaining 6 patients were not able to return to their previous work.

**Effects of the surgery on range of movement:** In 25 patients there was a pain free range including flexion, abduction, external and internal rotation while the remaining eight patients had mild pain with movements.

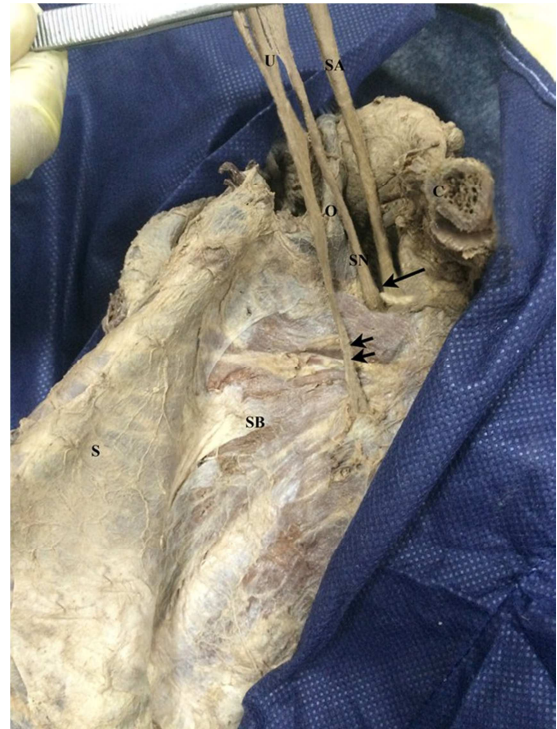**Effects of the surgery on force of abduction:** The mean force of abduction which was attained at follow-up was 6 kg (mean 1.5 to 10). For comparison, the mean abduction force in the contralateral unaffected shoulder was 7 kg (3 to 11) (fig 11).

**Effects of the surgery on muscle wasting:** Of the 25 patients who had wasting of both muscles, 13 had full recovery of muscle bulk, in seven the atrophy became less marked and in five there was no noticeable atrophy of the supraspinatus while that of infraspinatus became less marked. Isolated atrophy of infraspinatus, which was found in seven patients before surgery, persisted in four.

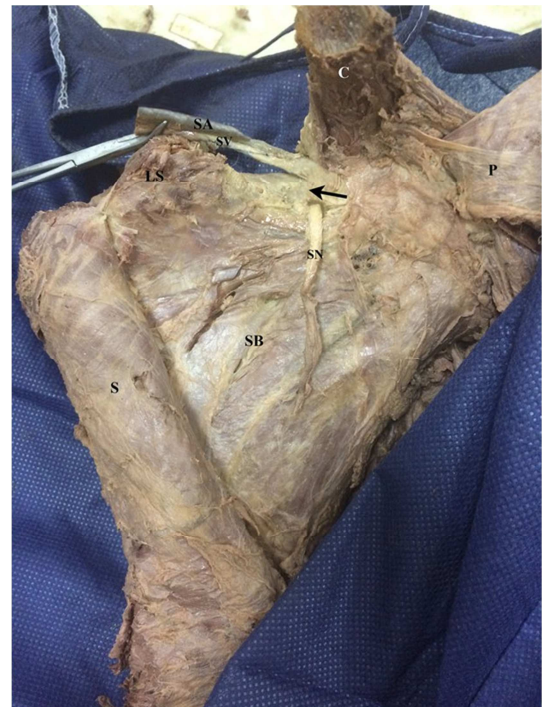
**Effect of time lapse:** Patients who were operated on within six months of the onset of symptoms, showed better recovery than those who had surgery after a longer interval.

**Table 3.** Clinical evaluation of the studied patients pre and post operative.

	Pre operative		Post operative		p
	No.	%	No.	%	
Pain					
No	8	24.2	25	75.8	0.0001*
Mild	18	54.5	7	21.2	
Moderate	7	21.2	1	3.0	
Daily activities					
Normal activities	6	18.2	0	0.0	0.0021*
Overexerted due to overuse	27	81.8	0	0.0	
Return to previous work	0	0.0	27	81.8	
Not able to work	0	0.0	6	18.2	
Range of motion					
No pain on motion	9	27.3	25	75.8	0.001*
Pain at flexion abduction, external and internal	24	72.7	8	24.2	
Muscle wasting					
No wasting	8	24.2	17	51.5	0.0136*
With wasting	25	75.8	5	15.2	
Atrophy	0	0.0	7	21.2	
Persisted	0	0.0	4	12.1	
Force of abduction					
After 6 months of follow up					
Range	1.5-10.0				0.254
Mean±S.D.	6.22±3.68				
In contralateral unaffected side					
Range	3-11				
Mean±S.D.	7.1±3.11				

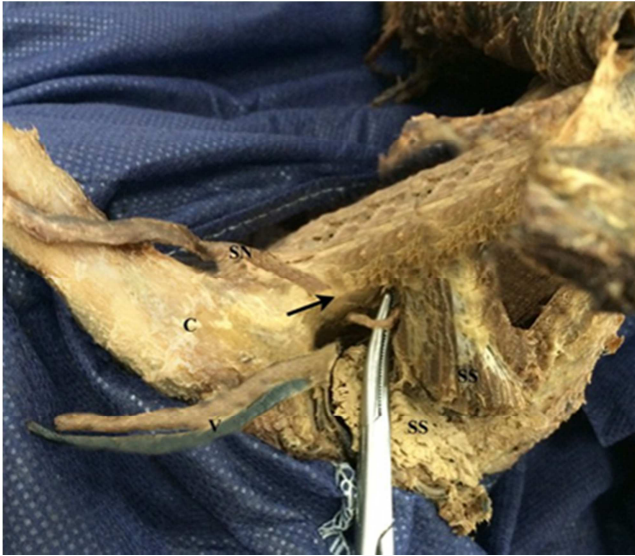

**Figure 6.** A photograph of the left scapular region (anterior view) showing the suprascapular nerve (SN) passing inferior to the transverse scapular ligament (→) while the suprascapular artery (SA) passing above it. SB: subscapularis muscle, S: serratus anterior muscle, C: clavicle, inferior belly of omohyoid muscle, U: upper trunk of brachial plexus, Double arrow: upper subscapular nerve.

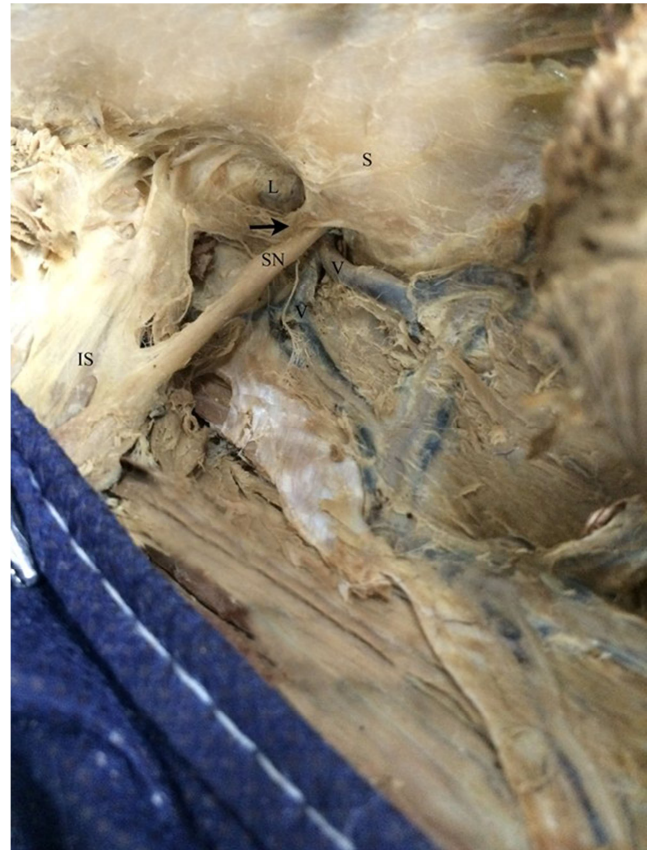

**Figure 7.** Previous photo showing the suprascapular nerve (SN) passing below the transverse scapular ligament (→) while the suprascapular artery (SA) and suprascapular vein (SV) passing above (→). Notice the suprascapular nerve retracted downward to show the transverse scapular ligament. The subscapularis muscle (SB) was anterior to the suprascapular notch and covers the lower part of this notch. S: serratus anterior muscle, C: clavicle, P: pectoralis minor muscle, LS: levator scapulae.

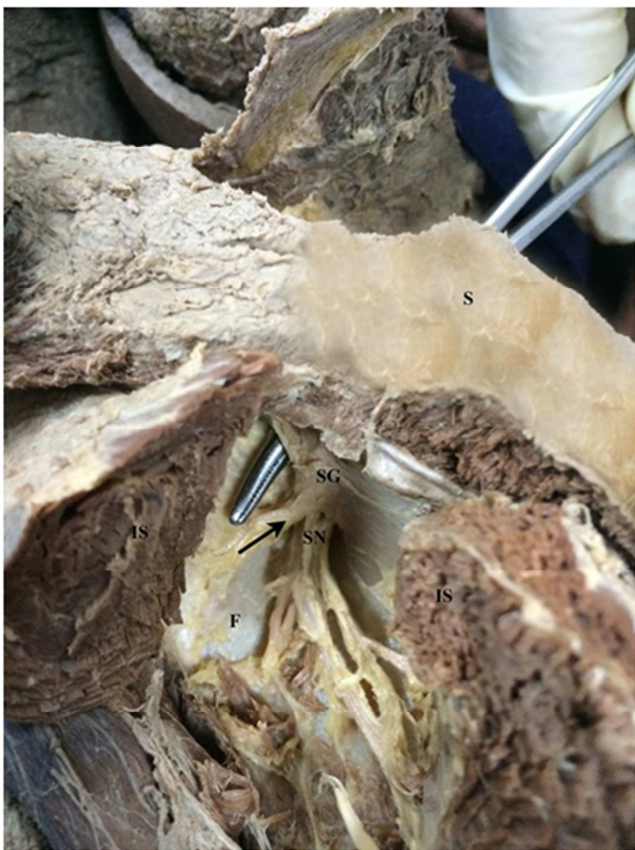



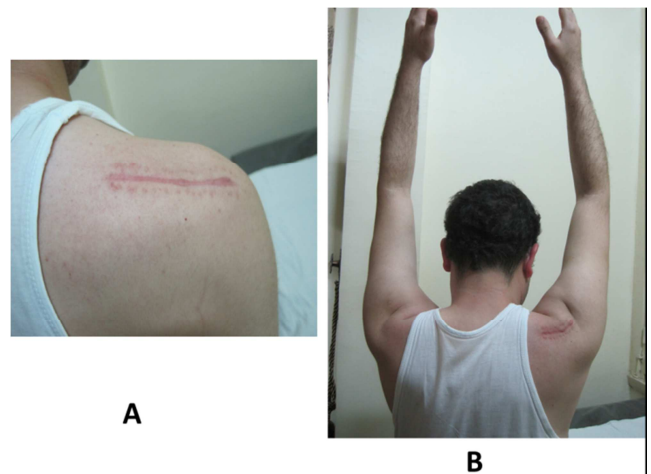
**Figure 8.** A photograph of the left scapular region (superior view) showing the suprascapular nerve (SN) passing below the transverse scapular ligament (→) while the suprascapular vessels (V) passing above (→). A branch from (SN) (hold by forceps) supplying the deep surface of supraspinatus muscle (SS) after its direct emergence from suprascapular notch.



**Figure 10.** A photograph of the left scapular region showing the suprascapular nerve (SN) passing through the spinoglenoid notch. The SG notch is divided into 2 compartments by a fascial septum (→); the medial one through which the SN and vessels (V) pass and lateral one (L). IS: infraspinatus muscle, S: spine.



**Figure 9.** A photograph of the left scapular region showing the suprascapular nerve (SN) passing through the spinoglenoid notch (SG). The SG is divided into 2 compartments by a fascial septum (inferior transverse scapular ligament) (→); the medial one through which the SN passes while the lateral is indicated by a forceps. IS: infraspinatus muscle, S: spine, F: infraspinatus fossa.



**Figure 11.** A photograph of a patient after surgical decompression showing: A- surgical incision, B- pain free range of abduction of the right shoulder equal to the contralateral side.

## 4. Discussion

Injury to the suprascapular nerve may occur because of the nerve's proximity to the operative field. The purpose of this study was to define a safe zone, using bony landmarks.

Iatrogenic injury to the suprascapular nerve may occur

during arthroscopic repair of chronic, massive rotator cuff tears.<sup>7-9</sup>

Prior anatomic studies of the suprascapular nerve have attempted to define a safe zone to avoid injury during arthroscopic transglenoid Bankart repairs, SLAP repairs, and open surgical procedures.<sup>3, 7, 8</sup>

In the present study, the suprascapular nerve originated from the upper trunk of the brachial plexus, which also gives upper subscapular nerve, a finding which was in agreement with Tasaki et al.<sup>12</sup>

In the present study, the suprascapular nerve runs parallel to the inferior belly of omohyoid muscle. It enters the suprascapular notch inferior to the transverse scapular ligament which separates it from suprascapular artery.

The transverse scapular ligament separates the suprascapular vessels above from the suprascapular nerve below. The subscapularis muscle lies anterior to the suprascapular notch and covers the lower part of this notch. However, Polguj et al.<sup>13</sup> found that the suprascapular notch was bounded by the fascia of the supraspinatus muscle, which is attached to the superior margin of the scapula as well as to the superior transverse scapular ligament.

In a similar study done by Bayramoglu et al.<sup>14</sup> the suprascapular ligament was divided into two parts (anterior and posterior) which differs from the results of the present study that shows the ligament is only one mass.

Polguj et al.<sup>13</sup> in their study on suprascapular nerve found that the suprascapular nerve and vein pass below the ligament in 61.3% of the specimens which differs from current findings in which all the specimens had the suprascapular vessels above and the suprascapular nerve below the ligament.

Bayramoglu et al.<sup>15</sup> found that hypertrophy of the subscapularis muscle might be an etiologic factor for suprascapular nerve entrapment at the suprascapular notch. This is in agreement with the results of the present study that showed the subscapularis muscle forming the anterior boundary of suprascapular notch.

Warner et al.<sup>16</sup> in their study on the suprascapular nerve stated that it runs parallel to the inferior belly of omohyoid muscle, which is similar to the findings of the present study.

In the present study, the suprascapular nerve enters the supraspinous fossa deep to the supraspinatus muscle, supplying it from its deep surface, then it passes through the spinoglenoid foramen which is bounded by the spine of scapula superiorly, back of the neck of the glenoid cavity laterally and infraspinatus muscle inferiorly. It is also divided by a fascial septum (spinoglenoid ligament or inferior transverse scapular ligament) into a larger lateral and smaller medial compartments.

Plancher et al.<sup>17</sup> classified spinoglenoid ligament into two types; type 1 (a thin indistinct band of tissue) and type 2 (a well formed ligament), a finding which is not apparent in the present study. The ligament was seen as being of uniform thickness and cannot be differentiated into two parts as previously stated.

In all specimens of the present study the suprascapular nerve and vessels passes through the medial compartment.

Immediately after emerging from the spinoglenoid foramen, the suprascapular nerve supplies the infraspinatus muscle from its deep surface and was accompanied by suprascapular vessels. In all cadaveric specimens, the suprascapular nerve crosses the infraspinous fossa from lateral to medial.

Ghodadra et al.<sup>18</sup> in their study stated that the suprascapular nerve release is often performed for compression neuropathy and to release pressure on the nerve associated with arthroscopic labral repair. This report describes a novel arthroscopic technique for decompression of the suprascapular nerve at the suprascapular notch or spinoglenoid notch through a subacromial approach. Through the subacromial space, spinoglenoid notch cysts can be visualized between the supraspinatus and infraspinatus at the base of the scapular spine this approach is explained by the finding of the present study that the spinoglenoid foramen is bounded by the spine of scapula superiorly, back of the neck of the glenoid cavity laterally and infraspinatus muscle inferiorly.

In the present study, the thickness of transverse scapular ligament as measured was in an average of 9.84 mm (range: 8.11-11.3 mm). The vertical diameter which extends from the most prominent point on the spine to the upper border of scapula was in an average of 2.5 cm (range 2.4-2.8 cm). The horizontal diameter which extends from just above the lower end of the lateral border of acromion till the suprascapular notch was in an average of 4.8 cm (range 4.5-5.2 cm)

Ruotolo et al.<sup>19</sup> in their study concluded that the thickness of transverse scapular ligament was 7 -8mm, a finding which is near to the present study.

Ide et al.<sup>20</sup> classified the ligament as either ligament- or membrane-type depending on its thickness. The width of the ligament and its maximal distance to bone and nerve were measured. Among the 115 specimens, the ligament was absent in 21 cases (18.3%), the ligament-type was present in 25 (21.7%), and the membrane-type was present in 69 (60.0%). The ligament width varied from 1.8 to 9.0 mm (mean, 5.4 mm), the maximal distance from ligament to bone varied from 3.0 to 11.1 mm (mean, 5.7 mm), and the distance from ligament to the nerve was from 0.1 to 7.0 mm (mean, 3.1 mm). As there was considerable variation in the distances from the ligament to the bone and nerve, the ligament may play a role in paralysis of the infraspinatus muscle, depending on these distances. These findings are different from the present study and this could be explained by the small sample size of the present study.

Warner et al.<sup>16</sup> evaluated the limits within which lateral mobilization of chronic massive retracted rotator cuff tears can be performed during open procedures without risking neurovascular injury. Even with delineation of these safe zones, however, iatrogenic injury to the suprascapular nerve during open rotator cuff repair and clavicle excision has been reported.

Knowledge of the distance from the suprascapular notch to the lateral border of the acromion may be used to establish a safe zone for anterolateral portal placement. Bigliani et al.,<sup>21</sup> described a safe zone enabling surgeons to avoid the suprascapular nerve during arthroscopic Bankart repair and

open surgical procedures. This safe zone, located in the posterior glenoid neck, measured 2 cm in diameter at the level of the supraglenoid tubercle and 1 cm in diameter at the level of the scapular spine. A finding which is near the findings of the present study and the measurements of the present study are easy to perform.

Woolf *et al.*<sup>22</sup> described the safety of the superior-medial portal, citing a mean distance of 2.42 cm from the suprascapular nerve. While this measurement is helpful in determining a safe distance from the suprascapular nerve to this single portal, many surgeons employ multiple arthroscopic portals for rotator cuff repairs.

Shishido and Kikuchi<sup>23</sup> described a safe zone for avoiding suprascapular nerve injury in open dissection of the posterior shoulder joint and arthroscopic procedures for Bankart repair in which blind drilling is involved.

In the present study of the 25 patients who had wasting of both muscles, 13 had full recovery of muscle bulk, in seven the atrophy became less marked and in the remaining five patients there was no noticeable atrophy of the supraspinatus while that of infraspinatus became less marked. Isolated atrophy of infraspinatus, which was found in seven patients before surgery, persisted in four of them.

25 of the 33 patients who had pain before the operation had none at the final review, One still had slight pain and seven had moderate pain. 27 of the 33 patients who overexerted their shoulder due to overuse, were able to participate in all of their previous activities without restriction, the remaining 6 patients were not able to return to their previous work. In 25 patients there was a pain free range including flexion, abduction, external and internal rotation while the remaining eight patients had mild pain with movements. Patients who were operated on within six months of the onset of symptoms, showed better recovery than those who had surgery after a longer interval.

Researchers<sup>24-30</sup> found that if there is evidence of muscular atrophy or severe pain, not controlled by drugs, the operation should not be delayed beyond three months.

Martin *et al.*<sup>31</sup> stated that, the patients who were operated on within six months of the onset of symptoms, showed better recovery than those who had surgery after a longer interval and that operative excision is indicated in patients whose symptoms result from compression of the nerve by a ganglion. In the present study, regardless of the cause of suprascapular nerve compression the delay in operation within 6 months had better recovery.

Black and Lombardo<sup>32</sup> in their study found that if the patient experiences a decrease in pain or increase in strength, and the electrophysiological findings show improvement during the preoperative period, the operation should be postponed or cancelled. When this occurs, the patient will usually recover spontaneously, particularly if the entrapment follows trauma.

## 5. Conclusion

Overviewing the results of the present study, careful investigation should be done as compression of the

suprascapular nerve may be at the suprascapular notch or spinoglenoid notch or it may be idiopathic. Patients who were operated upon within six months of the onset of symptoms, showed better recovery than those who had surgery after a longer interval and that operative excision is indicated in patients whose symptoms result from compression of the nerve by a ganglion.

## Conflict of Interest

None declared.

## References

- [1] Standring S. *Gray's Anatomy: The Anatomical Basis of Clinical Practice*. 40th ed. London: Longmans, Green and Co, 2008: 1123–1124.
- [2] Neeta VK. *Clinical anatomy 2nd edition. Superficial muscles of the back and scapular region*. 2012; 13: 111–112.
- [3] Ritchie ED, Tong D, Chung F, Norris AM, Miniaci A, Vairavanathan SD. Suprascapular nerve block for postoperative pain relief in arthroscopic surgery: a new modality. *Anesth Analg*. 1997; 84: 1306–1312.
- [4] Brown DE, James DC, Roy S. Pain relief by suprascapular nerve block in glenohumeral arthritis. *Scand J Rheumatol*. 1988; 17: 411–415.
- [5] Green S, Buchbinder R, Glazier R, Forbes A. Systematic review of randomised controlled trials of interventions for painful shoulder: selection criteria, outcome assessment, and efficacy. *BMJ*. 1998; 316: 354–360.
- [6] Van der Heijden GJ, van der Windt DA, Kleijnen J, Koes BW, Bouter LM. Steroid injections for shoulder disorders: a systematic review of randomized clinical trials. *Br J Gen Pract*. 1996; 46: 309–316.
- [7] Van der Windt DA, van der Heijden GJ, Scholten RJ, Koes BW, Bouter LM. The efficacy of non-steroidal anti-inflammatory drugs (NSAIDs) for shoulder complaints. A systematic review. *J Clin Epidemiol*. 1995; 48: 691–704.
- [8] Fabre T, Piton C, Leclouerec G, F. Delion G, Durandea A. Entrapment of the suprascapular nerve. *J Bone Joint Surg [Br]*. 1999; 81-B: 414–419.
- [9] Constant CR, Murley AHG. A clinical method of functional assessment of the shoulder. *Clin Orthop*. 1987; 214: 160–164.
- [10] Narakas AO. Compression and traction neuropathies about the shoulder and arm. In: *Operative nerve repair and reconstruction*. Philadelphia: J. B. Lippincott, 1991; 2: 1151–1157.
- [11] Miller RH, Dlabach JA. Shoulder and elbow injuries. In: *Campbell's Operative Orthopaedics*. Canale & Beaty. 12th ed. Philadelphia, Pennsylvania. Mosby. 2013; 44: 2631–2634.
- [12] Tasaki A, Nimura A, Mochizuki T, *et al.* Anatomic observation of the running space of the suprascapular nerve at the suprascapular notch in the same direction as the nerve. *Knee Surg Sports Traumatol Arthrosc*. 2015; 23(9): 2667–2673.



- [13] Polguj M, Jędrzejewski K, Majos A, Topol M. Variations in bifid superior transverse scapular ligament as a possible factor of suprascapular entrapment: an anatomical study. *Int Orthop*. 2012; 36(10): 2095–2100.
- [14] Bayramoğlu A, Demiryürek D, Tüccar E, et al. Variations in anatomy at the suprascapular notch possibly causing suprascapular nerve entrapment: an anatomical study. *Knee Surg Sports Traumatol Arthrosc*. 2003; 11(6): 393-398.
- [15] Bayramoglu A, Demiryurek D, Erbil M, Aktekin M, Tetik O, Doral M N. Hypertrophy of the subscapularis muscle might be an etiologic factor for suprascapular nerve entrapment at the suprascapular notch. *Neuroanatomy*. 2002; 1: 5-6.
- [16] Warner J P; Krushell R J; Masquelet A; Gerber C. Anatomy and relationships of the suprascapular nerve: anatomical constraints to mobilization of the supraspinatus and infraspinatus muscles in the management of massive rotator-cuff tears. *J Bone Joint Surg Am*. 1992; 74 (1): 36-45.
- [17] Plancher KD, Peterson RK, Johnston JC, Luke TA. The spinoglenoid ligament. Anatomy, morphology, and histological findings *J Bone Joint Surg Am*. 2005; 87: 361-365.
- [18] Ghodadra N, Nho SJ, Verma NN, et al. Arthroscopic decompression of the suprascapular nerve at the spinoglenoid notch and suprascapular notch through the subacromial space. *Arthroscopy*. 2009; 25: 439-445.
- [19] Ruotolo CL, Fow JE, Nottage WM. The supraspinatus footprint: an anatomic study of the supraspinatus insertion. *Arthroscopy*. 2004; 20(3): 246-249.
- [20] Ide J, Maeda S, Takagi K. Does the inferior transverse scapular ligament cause distal suprascapular nerve entrapment? An anatomic and morphologic study. *J Shoulder Elbow Surg*. 2003; 12(3): 253-255.
- [21] Bigliani L. U, Dalsey R. M., McCann P. D., April E. W. An anatomical study of the suprascapular nerve. *Arthroscopy*. 1990; 16; (4), 301–305.
- [22] Woolf S. K., Guttman D., Karch M. M., Graham R. D, Reid B., Lubowitz J. H. The superior-medial shoulder arthroscopy portal is safe. *Arthroscopy*. 2007; 23: 247–250.
- [23] Shishido H and Kikuchi S. Injury of the suprascapular nerve in shoulder surgery: an anatomic study. *Journal of Shoulder & Elbow Surgery*. 2001; 10(4): 372–376.
- [24] Vastamaki M, Göransson H. Suprascapular nerve entrapment. *Clin Orthop*. 1993; 297: 135-143.
- [25] Emery P, Wedderburn L, Grahame R. Suprascapular nerve block for shoulder pain in rheumatoid arthritis. *BMJ*. 1989; 299: 1079–1080.
- [26] Post M, Mayer J. Suprascapular nerve entrapment: diagnosis and treatment. *Clin Orthop*. 1987; 223: 126-136.
- [27] Callahan JD, Scully TB, Scott A, Shapiro SA, Worth RM. Supra- scapular nerve entrapment: a series of 27 cases. *J Neurosurg*. 1991; 74: 893-896.
- [28] Ferretti A, Cerullo G, Russo G. Suprascapular neuropathy in volley-ball players. *J Bone Joint Surg [Am]* 1987; 69-A: 260-263.
- [29] Ringel SP, Treihaft M, Carry M, Fisher R, Jacobs P. Suprascapular neuropathy in pitchers. *Am J Sports Med*. 1990; 18: 80-86.
- [30] Fritz RC, Helms CA, Steinbach LS, Genant HK. Suprascapular nerve entrapment: evaluation with MR imaging. *Radiology*. 1992; 182: 437-444.
- [31] Martin SD, Warren RF, Martin TL, et al. Suprascapular neuropathy: results of non-operative treatment. *J Bone Joint Surg [Am]*. 1997; 79-A: 1159-1165.
- [32] Black KP, Lombardo JA. Suprascapular nerve injuries with isolated paralysis of the infraspinatus. *Am J Sports Med*. 1990; 18: 225-228.