

Donovanosis – A Case Report with a Review of Literature

Hristo Mangarov¹, Valentina Broshtilova², Atanas Batashki³, Yoanna Velevska⁴, Petar Vatov⁵,
Svetlana Bezhanova¹, Irina Iungareva¹, Sonya Marina¹

¹Department of Dermatology and Venereology, Medical Institute of the Ministry of Internal Affairs, Sofia, Bulgaria

²Department of Dermatology and Venereology, Military Medical Academy, Sofia, Bulgaria

³Department of Special Surgery, Medical University, Plovdiv, Bulgaria

⁴Department of Infectious Diseases, Parasitology and Dermatovenereology, Medical University, Varna, Bulgaria

⁵Department of Surgical Diseases, MB Urology, Medical University, Varna, Bulgaria

Email address:

soniamarina1@yahoo.com (Sonya Marina)

To cite this article:

Hristo Mangarov, Valentina Broshtilova, Atanas Batashki, Yoanna Velevska, Petar Vatov, Svetlana Bezhanova, Irina Iungareva, Sonya Marina. Donovanosis – A Case Report with a Review of Literature. *International Journal of Clinical Dermatology*. Vol. 6, No. 1, 2023, pp. 10-13. doi: 10.11648/j.ijcd.20230601.12

Received: June 9, 2023; Accepted: June 28, 2023; Published: July 6, 2023

Abstract: Donovanosis (Granuloma inguinale) is a sexually transmitted bacterial infection affecting the genital, perineal, and perianal regions. It is caused by *Klebsiella granulomatis*, formerly known as *Donovania granulomatis* and *Calymmatobacterium granulomatis*. Without treatment, the infection followed a chronic progressive course with the formation of ulcerations. Upon chronification, severe tissue destruction occurs and malignant transformation is possible. Healing is complete with timely diagnosis and treatment. Donovanosis has not been reported in Bulgaria and herein, we present the first clinical case of this "exotic" for our country sexually transmitted bacterial infection. Our patient was a 38-year-old man of Nigerian origin. The dermatological status is represented by papular and erosive-ulcerative lesions on the skin of the foreskin, the body of the penis, the scrotum and the lower abdomen. Upon Giemsa staining of ulcer material, Donovan corpuscles are found in monocytes. The histopathological examination a lesion demonstrated irregular acanthosis, focal dyskeratosis in the lower epidermal segment, moderate spongiosis, papillary oedema, edema swollen endothelium obstructing the vessels of small and medium caliber, abundant granulomatous tuberculoid infiltrate of epithelioid cells and lymphocytes around the blood vessels in the middle dermis and interstitial. Infectious granulomas are represented by tissue macrophages, epithelioid cells and lymphocytes located around areas of collagen necrosis. Based on the anamnesis, dermatological status and examinations, the diagnosis of donovanosis was made. Epithelialization of the ulcers occurred after an extended course of systemic treatment with doxycycline for 20 days, followed by azax for 7 days. The topical treatment included baths with potassium permanganate and fusidine cream.

Keywords: Donovanosis, Sexually Transmitted Infection, Genital Ulceration, Diagnosis, Treatment

1. Introduction

Donovanosis (Granuloma inguinale), also known as phagedenic disease of the genitals infected granuloma, sclerosing granuloma, infectious granuloma, inguinal granuloma, venereal and fifth venereal disease, without treatment, is a chronic and progressive sexually transmitted bacterial infection (STI). It is known as "carnivorous STIs" because of the type of red meat on the ulcers and their spread in depth. It is caused by *Klebsiella granulomatis*, formerly known as *Donovania granulomatis* and *Calymmatobacterium granulomatis*. It proceeds mainly with painless, genital,

perineal and perianal ulcerations [1, 2]. Upon chronification, tissue destruction occurs with the risk of malignant transformation. Superinfections with other STIs, including syphilis and HIV, have been reported [3]. The disease is rare in temperate countries, but is common in the tropics and subtropics [2]. Endemic areas are Papua New Guinea, the Caribbean, South India, South Africa, Southeast Asia, South America, Indonesia, Argentina, Australia and Brazil [2, 4].

2. Clinical Case

We represent a 38-year-old man of Nigerian origin. From about 3 weeks, slightly painful "pimples" appear on the

genitals and lower abdomen, which are sore. He felt a slight burning and pain. He applied antibiotic and corticosteroid creams to no avail. The dermatological status is represented by papular and erosive-ulcerative lesions ranging in size from 0.5-1 cm to 1.5-2.5 cm, with an elevated edge and discrete serous-purulent secretion with an unpleasant fetor on the skin of the foreskin, the body of the penis, the scrotum and the lower abdomen (Figure 1). Conducted paraclinical studies of CBC, ESR and CRP did not show abnormalities.

Serological tests for syphilis, AIDS, hepatitis B and C and Chlamydia trachomatis (IgG, IgM) were negative. Upon Giemsa staining of ulkus material, Donovan corpuscles are found in monocytes. Microbiological examination of ulkus secretion also found *Streptococcus pyogenes* with sensitivity to amikacin, amoxicillin/clav. acid, cefepime, cefotaxime/ceftriaxone, ciprofloxacin, co-trimoxazole, erythromycin, gentamicin and levofloxacin.

The punch biopsy made from a lesion and the subsequent histopathological examination demonstrated irregular acanthosis, focal dyskeratosis in the lower epidermal segment, moderate spongiosis, papillary oedema, edema swollen endothelium obstructing the vessels of small and medium caliber, abundant granulomatous tuberculoid infiltrate of epithelioid cells and lymphocytes around the blood vessels in the middle dermis and interstitial (Figure 2). Infectious granulomas (Figure 3) are represented by tissue macrophages, epithelioid cells and lymphocytes located around areas of collagen necrosis (Figure 4).

Based on the anamnesis, status and examinations, the diagnosis of donovanosis was made. We applied an extended course of treatment. Systemic oral therapy was performed with doxycycline 100 mg, 2 times a day 1 tab., 20 days, followed by azax 500 mg, 1 time per day, 7 days. Local therapy included 2 times a day baths with KMnO_4 and fucidin cream. Epithelialization of the ulks with a residual hypopigmentation occurred (Figure 5).

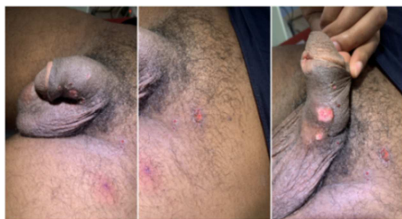

Figure 1. Erosive-ulcerative lesions on the body of the penis, pubis and inguinal.

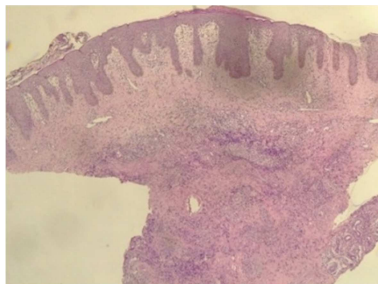


Figure 2. (H&E, x 4) Tuberculoid infectious granuloma in middle dermal segment.

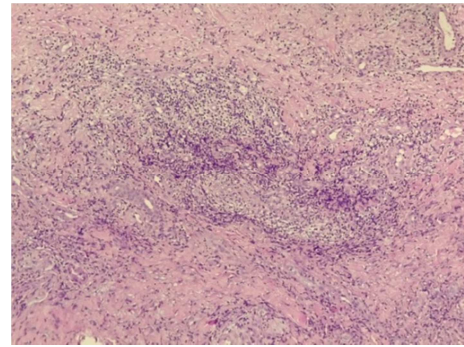


Figure 3. (H&E, x 100) Interstitial infectious granuloma represented by collagen necrosis peripherally distinguished by tissue macrophages, epithelioid cells, lymphocytes and plasmocytes.

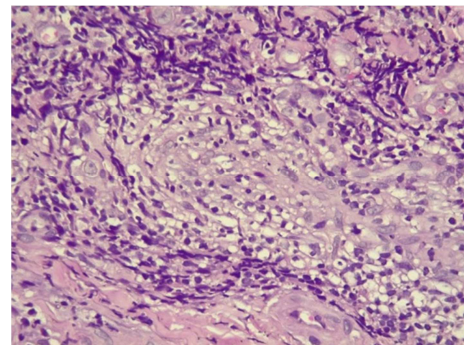


Figure 4. (H&E, x 400) Tissue macrophages with amorphous haematoxylin-positive cytoplasmic oval deposits (donovan corpuscles).

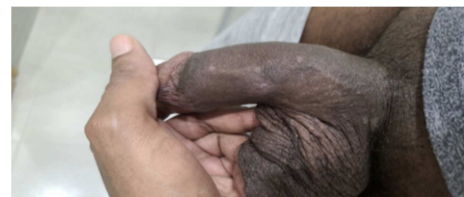

Figure 5. Residual hypopigmentation.

3. Discussion

Donovanosis was first described by K. McLeod in Calcutta, India, in 1881 [5]. C. Donovan discovered the causative agent of the disease in 1905 when he was working in a hospital in Madras [6]. He suggested that intracellular inclusions in macrophages were protozoa, which were later called Donovan corpuscles. The term donovanosis was proposed by M. Marmell and E. Santora in 1950 in honour of C. Donovan [7].

Granuloma inguinale is an STI [1, 2, 7, 8]. The disease mainly affects sexually active groups (20-40 years), extremely rarely children or other age groups (9). According to some authors there is no sexual predisposition, according to others the ratio of men to women is 2: 1 [2, 7]. In the same patient an association with HIV, syphilis and other STIs was observed [1, 10]. Infection is predominantly sexually transmitted, rarely by direct skin-to-skin contact, by autoinoculation or faecal contamination [7, 8, 11]. Vertical transmission of the infection from mother to newborn in vaginal birth is also possible [7]. Donovanosis is caused by *Klebsiella granulomatis*, Gram (-) intracellular, facultative, aerobic, rod-shaped bacteria,

formerly known as *Calymmatobacterium granulomatis* [1, 2, 7, 12, 13]. In microscopic examination, microorganisms are visualized in macrophages in the form of small oval bodies called Donovan bodies, pathognomonic to infection [1, 2]. They are relatively easy to stain on Giemsa, Leishman or Wright [1-3, 7, 8]. J. S. Carter *et al.* based on molecular studies in 1999 found that *C. granulomatis* was over 90% similar to *K. pneumoniae* and *K. rhinoscleromatis* [13]. The authors propose a reclassification of the microorganism as *Klebsiella granulomatis* *comb. nov.*, which remains to this day.

The incubation period of the disease ranges from 1 to 365 days, most often 2-3 weeks [1-3, 7, 8, 12, 13]. In 90% of patients the first lesions are in the genital, perianal or perineal areas, in 10% are inguinal and in about 6% are extragenital [1, 2, 8, 9, 11, 12]. In men, they are most often on the penis (foreskin, coronary furrow, frenulum, glans) and anus, and in women on the labia minora, cervix and upper genital tract. The lips, oral mucosa, pharynx, larynx, face, scalp, neck, axillae, chest and abdomen are extragenitally affected.

The onset is slow and gradual, with papule, papulo-vesicle or subcutaneous nodule/nodus appearing at the inoculation site, which may be single or multiple. The latter in the inguinal region resemble bubon, the so-called pseudobubon. The initial lesion progresses to a painless, easily bleeding ulcer, with a soft base and a raised bumpy, serpyiginous, slowly growing periphery. Patients often do not notice it and seek help in advancing the disease. In skin folds it is possible to occur autoinoculation and the formation of new "mirror" lesions. Regional lymphadenitis rarely develops. The general condition is preserved [1, 2, 8, 12, 14]. In pregnant women, the disease has a more aggressive course and more slowly responds to treatment [12].

4 types of lesion have been described [1, 2, 10, 1]:

1. ulcerogranulomatous – most frequent, single or multiple, soft, easily bleeding, erythematous, painless ulcers, centrifugally growing;
2. hypertrophic or verucosus - the lesions have irregular, raised edges and a dry surface;
3. necrotic - deep, painful ulcers with an unpleasant fetor and subsequent tissue destruction;
4. sclerotic or cicatricial - with extensive fibrosis and formation of cicatrices.

In the course of the disease, a number of complications may arise. Syphilis, HIV, or other STIs superinfection often occurs, with men with donovosis considered "superspreaders" of HIV [1, 2, 10, 12, 1]. In untreated patients with secondary bacterial infection, lymphadenitis and sepsis rarely develop [1, 2, 12, 14]. With the cicatricial form, obstruction of the urinary tract is possible [1, 2, 14]. In women, labial edema and elephantiasis, profuse vaginal discharge, even bleeding, strictures of the urethra, vagina or anus, rectovaginal fistulas and hematuria [1, 2, 14] may be observed. A spinocellular carcinoma of the vulva after a prolonged course of the disease has been described [15]. Mental disorders, even suicidal trials, have been reported [14]. Rarely, hematogenous dissemination of infection occurs. It is observed in immunocompromised patients. The spleen, liver, intestines, lungs, uterus, ovaries,

muscles, joints and bones are affected with osteolytic lesions, primarily of the tibia and vertebrae [12]. The clinical picture proceeds with a violation of the general condition, fever, anemia, night sweats, weight loss and sepsis.

In non-endemic areas, diagnosing donovosis is challenging and requires thinking about this "exotic" STI [12]. The fastest, most economical and reliable diagnostic method is direct microscopy with Giemsa, Leishman or Wright staining [3, 7, 16]. Identification of Donovan corpuscles in the tissue swab is pathognomonic to the disease [1, 2, 12, 16]. Histological examination from an active lesion with Giemza or silver staining showed chronic inflammation with infiltration of plasma cells and polymorphonuclear leukocytes [2, 12]. Other diagnostic options are both PCR testing, which is not widely available, and serological tests, which are not accurate enough to confirm the diagnosis [1-3, 12].

Donovanosis should differ in differential diagnostic terms from syphilis, chancroid, tuberculosis, lymphogranuloma venereum, ulcer molle, leishmaniasis, carcinoma, chronic herpetic ulcerations, bipolar aphthosis, Behçet's disease, pyoderma gangrenosum, amoebiasis, paracoccidioidomycosis and histiocytosis of Langerhans cells [1, 2, 7, 8, 10, 12].

Treatment of donovosis was initially carried out with antimonite used to treat calla-azar as it was supposed to be caused by a leishmaniasis-like protozoa [2, 8]. In 1913, H. B. Araújo and G. Vianna introduced intravenous treatment with antimony potassium tartrate, which was the first effective drug for donovosis [2, 7, 8, 10, 12, 17].

Currently, the recommended first-line therapy of donovosis is oral azithromycin 1 g per week or 500 mg daily. Possible alternatives are oral doxycycline 2 times a day 100 mg, ciprofloxacin 2 times a day 500 mg or sulfamethoxazole/trimethoprim 2 times a day 480 mg. In pregnant women, oral erythromycin is recommended 4 times a day 500 mg, and in children oral azithromycin 20 mg/kg 1 time daily.

In case of slow response to lesions, gentamicin 1 mg/kg/d 3 times daily was administered parenterally. The duration of therapy for all regimens is at least 3 weeks or until complete epithelialization of the lesions [1, 15, 16, 18].

With significant tissue loss and in cicatrix, surgical interventions are necessary [12, 18].

Relapses were noted after 6-18 months, despite successful therapy [2, 10].

Both follow-up of patients for 2-3 months for at least 1 year and a clinical examination of sexual partners from the last 6 months are recommended [1, 12].

It is necessary to disinfect personal and bed linen that has been in contact with active ulcers, since they are the most contagious [2, 10, 12].

4. Conclusion

Diagnosis of donovosis in non-endemic areas, such as Bulgaria, is extremely challenging. Our patient clinically presented with ulcerogranulomatous lesions and the differential diagnosis was extremely versatile. The

histopathological analysis directed towards infectious etiology, however, verification needed precise microbiological findings. Direct microscopy forwarded to donovanosis and prompted an extended systemic antibiotic treatment. The complete healing proved timely diagnosis and demonstrated the first case of granuloma inguinale in our country.

References

- [1] O'Farrell, N. Donovanosis. Sexually Transmitted Infections. 2002; 78 (6): 452–457.
- [2] Belda Junior, W. Donovanosis. Anais brasileiros de dermatologia. 2020; 95 (6): 675–683.
- [3] Murray PR, Rosenthal KS, Pfaller MA. Medical Microbiology (5th ed.). 2005; Philadelphia: Elsevier Mosby. p. 336. ISBN 978-0-323-03303-9.
- [4] Muller EE, Kularatne R. The changing epidemiology of genital ulcer disease in South Africa: has donovanosis been eliminated?. Sex Transm Infect. 2020; 96 (8): 596–600.
- [5] McLeod K. Précis of operations performed in the wards of the first surgeon, medical college hospital, during the year 1880. Ind Med Gaz. 1881; 16 (5): 123–130.
- [6] Donovan C. Medical cases from Madras General Hospital. Ulcerating granuloma of the pudenda. Ind Med Gaz. 1905; 40: 414.
- [7] Marmell M, Santora E. Donovanosis - Granuloma inguinale. Incidence, nomenclature, diagnosis. Am J Syph Gonorr Ven Dis. 1950; 34: 83–90.
- [8] Kampmeier R. Granuloma inguinale. Sex Transm Dis. 1984; 11: 318–321.
- [9] Ahmed N, Pillay A, Lawler M, et al. Donovanosis causing lymphadenitis, mastoiditis and meningitis in a child. Lancet. 2015; 385 (9987): 2644.
- [10] Martins S, Jardim MML. Donovanose. In: Belda W. Jr, Di Chiacchio N., Criado P. R., editors. Tratado de Dermatologia. Ed Atheneu; São Paulo: 2018: 1587–1592.
- [11] Goldberg J. Studies on Granuloma inguinale V. Isolation of a bacterium resembling donovania granulomatis from the faeces of a patient with granuloma inguinale. Br J Vener Dis. 1962; 38: 99–102.
- [12] Santiago-Wickey JN, Crosby B. Granuloma Inguinale. 2022 Aug 8. In: StatPearls [Internet]. Treasure Island (FL): StatPearls Publishing; 2022 Jan–. PMID: 30020678.
- [13] Carter JS, Bowden FJ, et al. Phylogenetic evidence for reclassification of Calymmatobacterium granulomatis as Klebsiella granulomatis comb. nov. Int J Syst Bacteriol. 1999; 49: 1695–1700.
- [14] Ramachander M, Jayalaxmi S, Pankaja P. A study of donovanosis at Guntur. Ind J Dermatol Venereol. 1967; 33: 237–244.
- [15] Sethi S, Sarkar R, Garg V. Squamous cell carcinoma complicating donovanosis not a thing of the past. Int J STD AIDS. 2014; 25: 894–897.
- [16] O'Farrell N, Hoosen AA, Coetzee K, et al. A rapid stain for the diagnosis of granuloma inguinale Genitourin Med. 1990; 66: 200–201.
- [17] Aragão HB, Vianna G. Pesquisa sobre o granuloma venéreo. Mem Inst Oswaldo Cruz. 1913; 5: 211–238.
- [18] O'Farrell N, Hoosen A, Kingston M. 2018 UK National guideline for the management of donovanosis. Int J STD AIDS. 2018: 1–3.