



Microscopic Anatomy of Sertoli and Leydig Cells During Fetal Development in Baladi Rabbit

Reda Mohamed^{1,2,*}, Zein Adam², Mohammed Gad², Khalid Mazher³

¹Department of Basic Veterinary Sciences, School of Veterinary Medicine, Faculty of Medical Sciences, The University of the West Indies, St. Augustine, Republic of Trinidad and Tobago

²Department of Anatomy and Embryology, Faculty of Veterinary Medicine, Beni Suef University, Beni Suef, Egypt

³Department Cytology and Histology, Faculty of Veterinary Medicine, Beni Suef University, Beni Suef, Egypt

Email address:

kkidareda@gmail.com (R. Mohamed)

*Corresponding author

To cite this article:

Reda Mohamed, Zein Adam, Mohammed Gad, Khalid Mazher. Microscopic Anatomy of Sertoli and Leydig Cells During Fetal Development in Baladi Rabbit. *International Journal of Animal Science and Technology*. Vol. 2, No. 1, 2018, pp. 1-5. doi: 10.11648/j.ijast.20180201.11

Received: November 26, 2017; Accepted: December 8, 2017; Published: January 10, 2018

Abstract: Fifty three baladi rabbit embryos and fetuses were used in this study. The results revealed that the testicular differentiation occurred with the formation of the testicular cords with their constituents, gonocytes and primitive Sertoli cells at the 18th day postconception. The Sertoli cells were increased in number from 20th day postconception onwards and they appeared as small sized cells with oval darker nuclei. The Leydig cells were demonstrated at the 20th day of gestation life as clusters of polyhedral large cells with strongly acidophilic finely granular cytoplasm and large, vesicular, spherical and eccentric nuclei. At 28th day postconception up to the full term rabbit fetus, the Leydig cells of the testis showed a marked reduction in size and number.

Keywords: Microscopic Anatomy, Sertoli Cells, Leydig Cells, Fetus, Rabbit

1. Introduction

Testicles are the important organ for production of spermatozoa and testosterone. The domestic rabbit is valued as a popular live laboratory animals used in laboratory researchers as it give offsprings monthly and copulation is necessary to initiate ovulation. It copulates readily and ovulates approximately 10 hours after copulation, so that allow accurate pregnancy timing [1]. Leydig cells are responsible for secretion of testosterone hormone which maintains spermatogenesis. The present study aimed to record normal structural changes in the prenatal developmental stages of Sertoli and Leydig cells in rabbit, so that it could be used as an aid to distinguish from altered cells on rabbits.

2. Material and Methods

The present study was done on 53 rabbit embryos and fetuses ranged from 9 days to full term (full term is 30 to 31 days as mentioned by [2] collected from the ethically

approved adult healthy pregnant female rabbits which were mated with a healthy fertile buck. The female was left with male for two hours periods in the late afternoon as a day 0 pregnancy for the purpose of timing the pregnancy [3]. Since the ovulation in rabbit is induced only after coital stimulation and occurred about 10 to 12 hours [4] after copulation. About 12 hours were discarded from the calculation to arrive at the true age. The crown vertebral rump length (C. V. R. L) was measured from start point of the forehead up to the base of the tail along the dorsum of the embryo or fetus.

The specimens were immediately transformed into 10% Neutral buffered formalin for 24 to 48 hours and Bouin's fluid for 12 to 24 hours. After fixation, the specimens were processed by routine paraffin embedding technique and were sectioned at 4-6 um thick and stained by different stains according to [5] including Harris Haematoxyline and eosin stain (H&E) for general histological examination and Crossman's trichrome stain for detection of collagen fibers and smooth muscles fibers;. Stained sections were examined by light microscope and photographed by Leica microscope system with digital camera at different powers.

3. Results

The indifferent gonad of rabbit started their differentiation into fetal testes at the 18th day postconception. The testicular differentiation was evident by the formation of an incomplete tunica albuginea and primitive testicular cords which consisted of numerous primitive supportive cells together with gonocytes. The primitive supportive (Sertoli) cells were smaller in size with oval darker nuclei (Figure 1).

The Sertoli cells were increased in number from 20th day postconception onwards due to their migration from the interstitium through the interrupted basement membrane and the successive mitotic division (Figure 2).

In 25th day-old rabbit fetus up to the full term rabbit fetus, the supportive cells transformed into columnar-shaped cells with oval or elongated nuclei which most of them were perpendicular to the basement membrane of the testicular cord, while few of them were centrally situated. (Figures 3, 4).

The interstitial tissue started to differentiate at the 19th day postconception to form small polyhedral interstitial cells with oval euchromatic nuclei and acidophilic cytoplasm showing progressive different phases of mitotic division (Figure 5).

On reaching 20th day postconception, the testicular interstitium was permeated by many blood capillaries and the testicular interstitial cells acquired the characters of typical endocrine cells. They appeared as clusters or irregular groups of polyhedral large cells with strongly acidophilic finely granular cytoplasm and large, vesicular, spherical and eccentric nuclei (Figure 6).

At 28th day postconception up to the full term rabbit fetus, the interstitial cells of the testis showed a marked reduction in size and number as most of these cells suffered from retrogressive changes as they appeared smaller in size with pyknotic smaller nuclei and scanty undifferentiated cytoplasm (Figure 7).

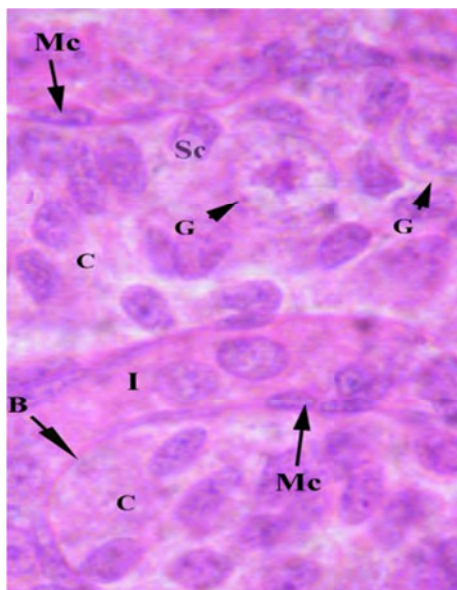


Figure 1. A higher magnification of a developing testicular cord of 18 days-old rabbit fetus showing gonocytes and supporting cells. H&E stain, X1000. C – Testicular cord; G – Gonocytes; Sc – Supporting (Sertoli) cells.

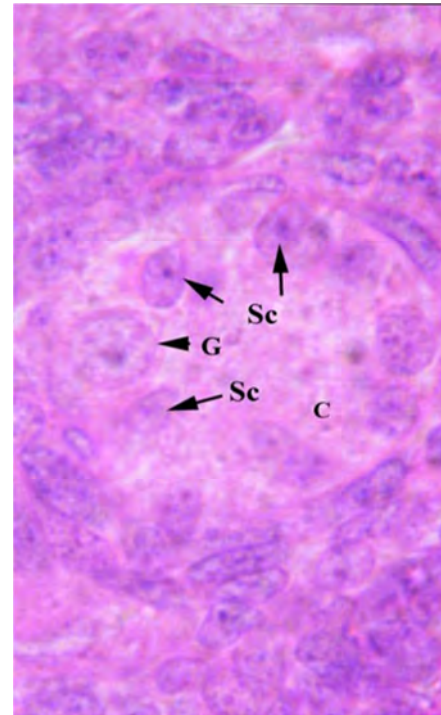


Figure 2. A photomicrograph of the testis of 20 days-old rabbit fetus showing testicular cord became large and more cellular and gonocytes appeared more larger than before. Note, myoepithelial cells appeared around the testicular cords and the basal lamina completely surrounded the cords. H&E stain, X1000. B – Basal lamina; C – Testicular cords; G – Gonocytes; I – Interstitium; Sc – Supporting (Sertoli) cells; Mc – Myoepithelial (Myoid) cells.

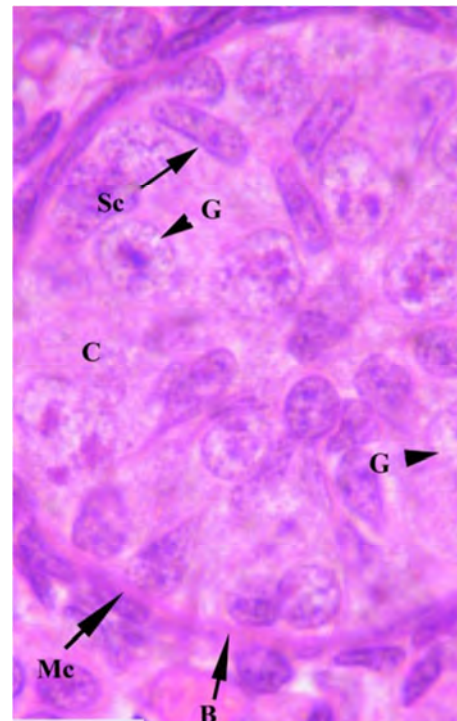


Figure 3. A higher magnification of testicular cord of full term rabbit fetus showing prespermatogonia with large nucleus and two nuclei. The supporting cells took their elongated columnar shape. Note, well-developed basal lamina enveloped the cord and surrounded by myoid cells. H&E stain, X1000. B – Basal lamina; C – Testicular cord; G – Gonocytes; Mc – Myoid cells; Sc – Supporting (Sertoli) cells.

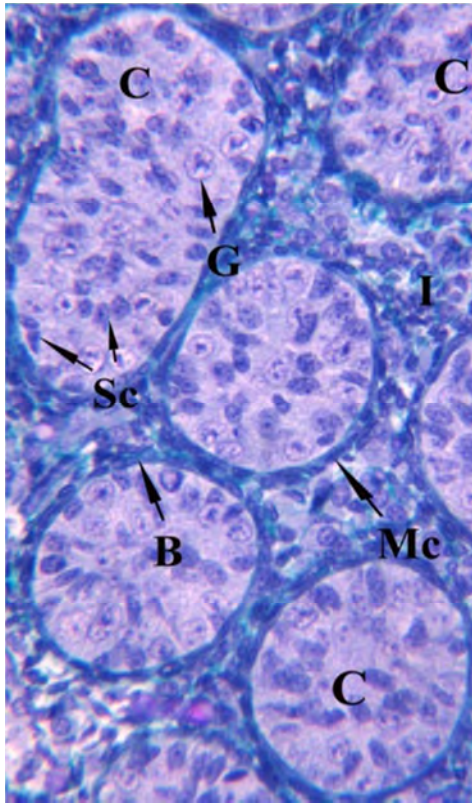


Figure 4. A photomicrograph of the full term fetal rabbit testis showing testicular cords surrounded by continuous basal lamina and complete layer of myoid cells Crossman's trichrome stain, X400. B – Basal lamina; C – Testicular cords; G – Gonocytes; I – Testicular interstitium; Mc – Myoid cells; Sc – Sertoli cells.

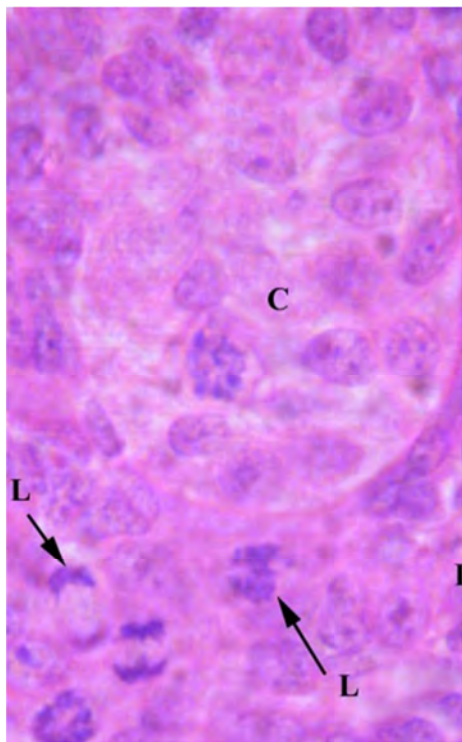


Figure 5. A photomicrograph of 19 days-old fetal rabbit testis showing interstitial cells slightly developed with numerous mitotic activities. H&E stain, X1000. C – Testicular cord; I – Testicular interstitium; L – Interstitial (Leydig) cells.

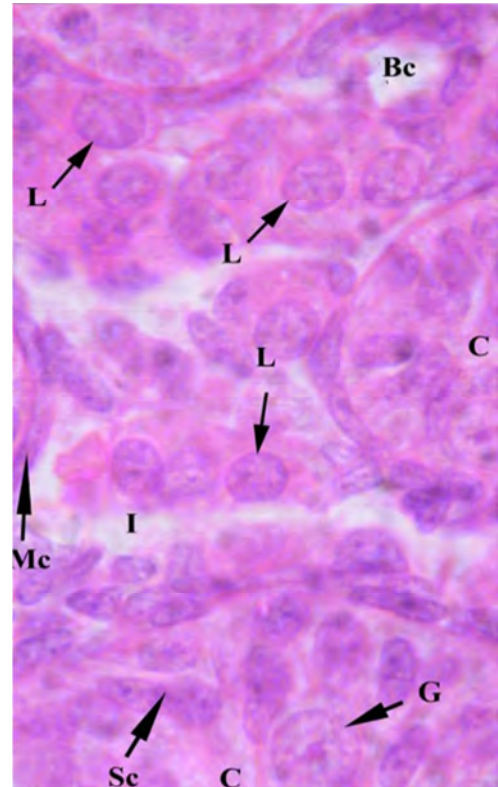


Figure 6. A section through testis of 20 days-old rabbit fetus showing well-developed interstitial cells appeared large polyhedral with round eccentric nuclei and acidophilic cytoplasm. Note, blood capillary. H&E stain, X1000. Bc – Blood capillary; C – Testicular cords; G – Gonocytes; I – Testicular interstitium; L – Leydig cells; Mc – Myoid cells; Sc – Sertoli cells.

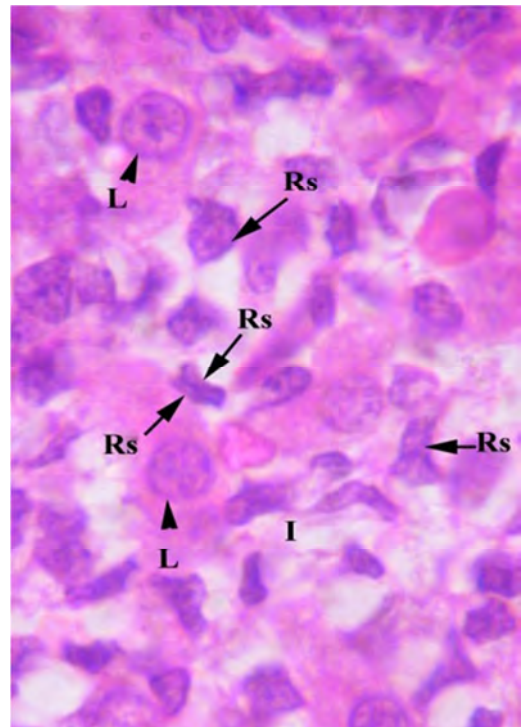


Figure 7. A photomicrograph of testicular interstitium of full term rabbit fetus showing retrogressive changes of the majority of Leydig cells while few cells remain active. H&E stain X, 1000. I – Testicular interstitium; L – Active Leydig cells; Rs – Retrogressed Leydig cells.

4. Discussion

The indifferent gonad of the rabbit, in the present work as well as that of Konsowa (1997) started its differentiation into fetal testis at 18th day postconception. This differentiation started at 14th, 14.5th, 15th, 16th, 16.5th or 19th day of fetal rabbit life [6, 7, 3, 8, 9, 10] respectively. Accurately there is a main definite time of testicular differentiation in the same species but these different times could be attributed to the different methods of fetal age calculation.

The current investigation, corresponding with those of [10] in rabbit clarified that the testicular cords contained testicular parenchymal cells which could be differentiated into the primitive Sertoli cells.

In agreement with [13] in rabbit, our results revealed that the primitive Sertoli cells appeared within the testicular cords at 18th day postconception. While, these cells appeared in 15th, 16th, 22nd or 28th day day-old rabbit fetus according to [3, 11, 10, 12] respectively

The current study revealed that the Sertoli cells were small elongated columnar cells with ill distinct boundaries and centrally situated nuclei. While, the Sertoli cells in rabbit are smaller, with dark nucleus and cytoplasm [13]. However, the primitive supporting cells of fetal rabbit testis are oval or pyramidal shaped cells have lightly acidophilic cytoplasm and oval nucleus [10]. On the other hand, the Sertoli cells of the same animal appear as elongated narrow cells with an elongated vesicular nucleus [12].

The present results were in agreement with those of [10] in rabbit, clarified that most of the Sertoli cells are regularly arranged along the basal portion of the testicular cord, while few cells are localized in the center of the testicular cord. While the Sertoli cells are regularly arranged along the basal portion of the testicular cord in rabbit [12].

In agreement with that given by [10, 12] in rabbit, the present work revealed that the Sertoli cells were differentiated from the primitive gonadal cells. While, in rabbit stated that the Sertoli cells originate from coelomic epithelium and mesonephric corpuscles in rabbit [3, 13].

In the work under discussion, The Sertoli cells of rabbit fetus were increased in number from 20th day postconception onwards due to their migration from the interstitium through the interrupted basement membrane and the successive mitotic division, the same observation was obtained in 25th day-old rabbit fetus [10].

In rabbit, the current investigation clarified that the interstitial cells were firstly appeared between the testicular cords at 19th day postcoitum. While, the Leydig cells appear in 16th day-old rabbit fetus [13]. On the other hand, the interstitial cells can be demonstrated in 22nd day-old rabbit fetus [10].

The current study revealed that the testicular interstitial cells acquired the typical endocrine characters at 20th day postconception. While, the differentiation of the fetal Leydig cells can be detected at 19th day postcoitum in rabbit [13]. In this connection, [10, 12] agreed that the differentiation of the fetal Leydig cells occur at 28th day-old rabbit fetus.

The study under investigation showed that the developed

Leydig cells appeared as large polyhedral cells with round eccentric nucleus and acidophilic cytoplasm. Similar result was recorded in rabbit [10].

In agreement with [10] in rabbit, the interstitial cells of the testis are differentiated from the testicular mesenchyme between the cords. In this connection, the fetal Leydig cells are differentiated from fibroblasts cells [12].

In the work under discussion, the interstitial endocrine cells of rabbit fetus were grouped into small or large clusters that occupied parts of the spaces between the developing testicular cords. The same observation was obtained in rabbit [10]. While, the Leydig cells at late fetal period of rabbit are present singly and rare in doublets [12].

The findings as well those gained by [10] in rabbit stated that the interstitial cells show an increase in their number due to their differentiation from mesenchymal cells and their infrequent mitosis.

The study under investigation showed that that from 28th day postcoitum up to the full term rabbit fetus, the number interstitial endocrine cells was decreased as that many Leydig cells underwent regression and the retrogressed cells appeared as smaller undifferentiated cells with pyknotic nuclei. While few of them remained active. Similar result was recorded in goat [14].

5. Conclusion

The histological differentiation of the testes occurred with the formation of the testicular cords with their constituents, gonocytes and primitive Sertoli cell at the 18th day postconception. The Leydig cells were demonstrated at the 20th day of gestation life and they suffered from retrogressive changes from 28th day postconception up to the full term rabbit.

Acknowledgements

The authors acknowledge the expert technical assistance of Anatomy and Histology Departments.

Conflict of Interest

All the authors do not have any possible conflicts of interest.

References

- [1] George, F. W. and J. D. Wilson (1979). The regulation of androgen and estrogen formation in fetal gonads. *Annales de biologie animale, biochimie, biophysique*, 19 (4B), 1297-1306.
- [2] Nielsen, H. C. and J. S. Torday (1983). Anatomy of fetal rabbit gonads and the sexing of fetal rabbits. *Laboratory Animals* 17, 148-150.
- [3] Diaz-Hernandez, V., A. Leon del Rio, M. Zamora, and H. Merchant- Larios (2008). Expression profiles of SRY and SOX9 in rabbit gonads: The classical model of mammalian sex differentiation. *Sexual Development* 2 (3), 152-166.

- [4] Hayashi, T., Y. Kageyama, K. Ischizaka, K. Kihara, and H. Oshima (2002). Involvement of apoptosis in the control of Sertoli cells and pre-meiotic germ cell numbers in the developing rabbit testis. *Andrologia* 34 (1), 34-40.
- [5] J. D. Bancroft and A. Gamble, "Theory and practice of histological" techniques. 6th Ed., Churchill- Livingstone, Edinburgh, London, Melbourne, New York: 2008.
- [6] Jost, A., S. Perlman, and S. Magre (1985). The initial stages of testicular differentiation in the rabbit fetus. *Archives d'anatomie microscopique et de morphologie experimentale* 74 (1), 69-75.
- [7] Allen, B. M, (1904). The embryonic development of the ovary and testis of the mammals. *The American Journal of Anatomy* 3 (2), 89-154.
- [8] Wartenberg, H., I. Kinsky, C. Viebahn, and C. Schmolke (1991). Fine structural characteristics of testicular cord formation in the developing rabbit gonad. *Journal of Electron Microscopy Technique* 19 (2), 133- 157.
- [9] Hoar, R. M. and I. W. Monie (1981). Comparative development of specific organ system. *Developmental Toxicology*, 13-33.
- [10] El-Oksha, S. M., (1993). Developmental studies on the testis of rabbit. MSc Thesis, Faculty of Veterinary Medicine, Moshtohor, Zagazig University (Benha), Egypt.
- [11] Gondos, B. and L. A. Conner (1973). Ultrastructure of developing germ cells in the foetal rabbit testis. *American journal of Anatomy* 136 (1), 23- 41. In.
- [12] Konsowa, M. M., (1997). The development of the male genitalia of the rabbit with reference to its vasculature. PhD Thesis, Faculty of Veterinary Medicine, Zagazig University, Egypt.
- [13] Bjerregaard, P., F. Bro-Rasmussen and T. Reumert (1974) Ultrastructure development of fetal rabbit testis. *Zeitschrift Fur Zellforschung Und Mikroskopische Anatomie* 147, 401-413.
- [14] Mazher, K. M., (1997). Histological studies of the testis of the goat fetuses. MVSc Faculty of Veterinary Medicine, Cairo. University (Beni Suef Branch), Egypt.