

Acute Myelitis After Correction of Hypospadias with Caudal Anesthesia

Jeniffer Almeida Correa do Nascimento¹, Matheus de Castro Abi-Ramia Chimelli¹,
Jose Eduardo Smilgevicius Silva¹, Marcelo Grisolia Gonçalo¹, Pedro Paulo Vanzillota²

¹Department of Anesthesiology, Hospital Federal da Lagoa, Rio de Janeiro, Brazil

²Department of Anesthesiology, Hospital Municipal Jesus, Rio de Janeiro, Brazil

Email address:

jeniarnascimento@gmail.com (J. A. C. do Nascimento), matheuscarchimelli@gmail.com (M. de C. Abi-Ramia C.),

sassa_mc@hotmail.com (J. E. S. Silva), marcelo_ufrj@hotmail.com (M. G. Gonçalo), pedro@idea.med.br (P. P. Vanzillota)

*Corresponding author

To cite this article:

Jeniffer Almeida Correa do Nascimento, Matheus de Castro Abi-Ramia Chimelli, Jose Eduardo Smilgevicius Silva, Marcelo Grisolia Gonçalo, Pedro Paulo Vanzillota. Acute Myelitis After Correction of Hypospadias with Caudal Anesthesia. *International Journal of Anesthesia and Clinical Medicine*. Vol. 8, No. 1, 2020, pp. 26-29. doi: 10.11648/j.ijacm.20200801.16

Received: February 14, 2020; Accepted: March 4, 2020; Published: April 23, 2020

Abstract: Combined epidural anesthesia with general anesthesia is the preferred anesthetic technique for lower limb surgery as well as lower abdominal, genitourinary and perineal surgery in children. This case report below depicts a rare complication: acute myelitis. It occurred following surgical correction of hypospadias (first stage) under combined caudal epidural anesthesia with general anesthesia in an Eight-months-old infant, weighing 9.8 kilograms, with no surgical/anesthetic history, without known allergies, previously healthy, with adequate developmental milestones, physical examination without abnormalities, without difficult airway predictors, with adequate fasting time and normal laboratorial exams. Some etiologies for this case report have been suggested such as spinal cord trauma, infectious and vascular causes, local anesthetic and noxious chemicals neurotoxicity and demyelinating diseases. In spite of thorough scrutiny, we were not able to define a single cause for the clinical manifestations. In this setting, the treatment goal was to provide support measures and rehabilitation of neurological deficits.

Keywords: Anesthesia, Acute Myelitis, Correction of Hypospadias, Neurological Deficits

1. Introduction

Pediatric anesthesia is a challenging subspecialty for anesthesiologists as there are still sparse published randomized clinical trials, due to safety concerns. There are insufficient data in terms of benefits and safety regarding regional anesthesia. Neuraxial techniques are mostly used when patients are under general anesthesia, which consists in a potential risk factor for neurologic complications [1].

The most popular regional anesthesia techniques for the pediatric population are caudal and lumbar epidural block, ilioinguinal/iliohypogastric block and dorsal penile nerve block. The caudal epidural block was first described in 1943 and it has become one of the most used regional anesthesia techniques, as it provides efficient postoperative analgesia for lower limb surgery as well as lower abdominal, genitourinary

and perineal surgeries [2].

The risk factors for complications vary between adult and pediatric patients who undergo an epidural block due to anatomic differences and immaturity of the central nervous system. Data suggests low rate of severe complications associated with pediatric epidural anesthesia. Until today, there is still reluctance by anesthesiologists in publishing data about perioperative complications, which hinders complete understanding and correct addressing of potential risk factors for neurologic injury [3].

Regarding pharmacology of local anesthetics, younger children have larger volume of distribution (Vd), lower depuration rate and smaller protein-bound fraction. The large Vd offsets the higher levels of free drug fraction, leaving toxicity unchanged. Thus, the maximum dose (ml per kg) is the same as in adults. The onset of the block starts earlier, but the duration is shorter [4].

Ropivacaine has become more important in anesthesia, although many authors believe its collateral effects must be further evaluated. In relation to the neurotoxicity, higher concentrations may cause mitochondrial morphological disturbances, interfering with cellular viability [5]. Moreover, ropivacaine has vasoconstrictive properties and may reduce blood flow in epidural vessels and contribute to local ischemia [14].

The case report below displays an acute myelitis that occurred following surgical correction of hypospadias (first stage), which was done under general anesthesia and epidural caudal block.

2. Case Presentation

Eight-months-old infant, weighing 9.8 kilograms, with no surgical/anesthetic history, without known allergies, was admitted in the Hospital Federal da Lagoa for elective surgical correction of hypospadias. Previously healthy and exclusively breastfeeding, with adequate developmental milestones (sitting unassisted and crawling). Physical examination without abnormalities, without difficult airway predictors, with adequate fasting time and normal laboratorial exams (INR 1.3; PTTa 30"; 279,000 platelets).

In the operating room, the patient was monitored with noninvasive blood pressure (NIBP), pulse oximetry and 5-lead cardioscopy. Following monitoring, the patient underwent anesthetic induction with facial mask providing O₂ 3L per minute, N₂O 6L per minute and sevoflurane 8%. Peripheral venous puncture was performed and a 24G catheter was placed in the left arm. After reaching adequate level of anesthesia, patient was intubated and a 4.0 endotracheal tube with cuff was placed following direct laryngoscopy on the first attempt and the mechanical ventilation (pressure-controlled mode) was applied. Sevoflurane was then reduced to 2% associated with nitrous oxide 60% and oxygen 40%. Amoxicillin + clavulanate 200 mg was administered as prophylactic antibiotic. The patient was positioned on left lateral decubitus and his lower limbs were flexed towards his abdomen and his head was flexed towards his chest for the performance of caudal epidural blockade. Caudal epidural block was performed after asepsis with 0.5% alcoholic chlorhexidine, placing of sterile fields and puncture of the sacral hiatus and confirmed by loss of resistance to air on the syringe. The anesthetic used was ropivacaine 0.5% 5 ml and clonidine 15 mcg. Then, as requested by the surgical team, a pad was placed underneath the sacrum.

Throughout the surgery, the infant stayed hemodynamically stable and the parameters remained within normal range for his age. Postoperative nausea and vomiting prophylaxis was made with dexamethasone 1,2 mg IV at the beginning of the procedure, and ondansetron 1 mg IV at the end. Total surgical length was 3 hours.

At the end of the surgery, the patient recovered the respiratory drive, although the tidal volume was low and he also presented immobility of all four limbs. At this moment, it was hypothesized that he was presenting total spinal

anesthesia. Two hours after the end of the surgery, an attempt of extubation was made, but the patient had difficulty breathing and a laryngeal mask size 1.5 was placed after a bolus dose of propofol 30 mg IV. Two hours later, the tidal volume was still low with the laryngeal mask and it was decided to reintubate the patient. A bolus dose of propofol 30 mg was injected as well as lidocaine 15 mg intravenously and a 4.0 endotracheal tube with cuff was placed following direct laryngoscopy. Then the patient was transferred to the Pediatric Intensive Care Unit to completely recover from the total spinal anesthesia (main hypothesis at the time).

On the next day, the infant woke up to physical stimuli but showed no movement of upper or lower limbs and was still connected to a mechanical ventilator. A cranial computed tomography scan (CT scan) as well as cervical, thoracic, lumbar and sacral CT scan were requested. Also CSF was collected to study biochemistry, cellularity, cultures, oligoclonal bands, IgM and IgG antibodies for EBV, PCR for enterovirus, PCR for cytomegalovirus, PCR for herpes simplex 1 and 2 and anti-aquaporin-4 IgG antibodies. Moreover, an evaluation from the Neuropediatrics was requested. It was recommended the prescription of dexamethasone 1 mg per kg per day, to address a possible anesthetic neurotoxicity.

The CT scan was done at the hospital and showed no abnormality, no signs of bleeding, hematoma or spinal cord compression. The neurosurgery team examined the infant and determined that he had acute flaccid myelitis after the surgical correction of hypospadias, with absent motor response to painful stimuli and absence of painful sensitivity below the neck. There was no surgical indication.

As the neuraxial CT scan was completely normal, a MRI was requested (cranial, cervical, thoracic, lumbar and sacral spine). After new analysis and further discussion between Pediatric ICU and Neuropediatrics, higher doses of methylprednisolone were recommended (30 mg per kg per day for 5 days), as the anesthetic toxicity became the most probable cause. Additionally, fundus examination was performed to exclude some demyelinating illnesses such as Devic's Disease (neuromyelitis optica).

Three days following the surgery, MRI scan (Figure 1) was performed which revealed transverse myelitis (hyperintensity area affecting area postrema, transition between medulla and spinal cord and spinal cord up until D2, centrally, delineating the "grey H", determining an expansive effect, without enhancement by contrast in T2), along with budging of cerebellar tonsils towards the foramen magnum (0,2 cm). Discrete contrast-enhancing edema over posterior cervical muscles was also present. Thus, the more likely differential diagnosis were mechanical causes, vascular and least likely neurotoxic. In this sense, following five days of pulse therapy, prednisolone was maintained (2 mg per kg per day). An electroneuromyography was requested and showed preganglionic neural impairment at C3 level. Up to this point there was no improvement from neurological symptoms. Another neuraxial MRI scan was scheduled five weeks after the first one.

Following further case discussion, on the fourteenth day post surgical procedure, IV immunoglobulin 400 mg per kg for 5 days was initiated empirically, focusing on the treatment of demyelinating diseases. CSF study was clean, as well as the dilated fundus examination. After the immunoglobulin treatment, the patient showed subtle improvement, now moving lower limbs laterally but still with no improvement in painful sensitivity.

Subsequent MRI scan revealed mitigation of transverse myelitis longitudinally extensive, without budging of cerebellar tonsils. However, this improvement on the imaging study was no accompanied by clinical recovery. Therefore, it was recommended by the pediatric surgery team the performance of a tracheostomy to provide respiratory comfort and a gastrostomy.

Only on the ninth day post surgery, a recovery of motor function was observed with slight lower limbs movement bilaterally.

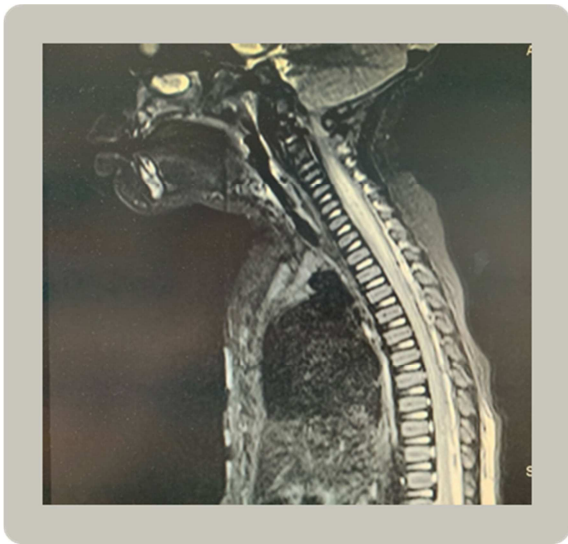


Figure 1. MRI scan revealing transverse myelitis.

3. Discussion

Faced with this unfortunate outcome following general anesthesia associated with caudal epidural anesthesia, we did not find any article or scientific publication which portrayed similar complication, or specifically acute flaccid tetraplegia as an adverse consequence post surgery.

Initially, the main etiology considered was total spinal anesthesia, as there was a delayed recovery from the motor blockade. Nonetheless, this hypothesis was ruled out after prolongation of motor blockade for more than 24 hours without spontaneous resolution [6].

Another hypothesis suggested was spinal cord injury following endotracheal intubation, but the patient had no history of cervical luxation or subluxation or any previous trauma that would predispose him to injury after head and/or neck extension [7]. Moreover, there was no difficulty managing the airway. MRI scan did not show any abnormality that would support this hypothesis. There was minimal

contrast-enhanced edema over posterior cervical muscles but with no clinical relevance.

Besides spinal cord injury, central infection and/or epidural abscess consequent to caudal epidural block have also been proposed. Epidural abscess presents a delayed onset of symptoms, so such a sudden manifestation of neurological deficit makes this diagnosis very unlikely. Most epidural abscesses are not related to catheters, they are in fact more related to skin, soft tissue, joint or bone infections with hematogenous dissemination into epidural space. This hypothesis was ruled out after imaging study and CSF study [8, 9].

A vascular etiology was also considered [10]. An extensive longitudinal myelitis could have been caused by a reduced arterial blood flow in cervical area due to vasoconstriction induced by clonidine associated with ropivacaine (vasoconstrictive agents). However, studies show that clonidine can cause vasoconstriction in high concentrations and there is little evidence for this mechanism with clinically used concentrations [13]. Conversely, ropivacaine can diminish blood flow of epidural vessels, thus supporting the vascular disturbance hypothesis [14].

Ropivacaine is widely used in anesthetic clinical practice, although some studies suggest that higher concentration may cause mitochondrial fragmentation, induce DRP1 mitochondrial fission protein and ultimately lead to mitochondrial dysfunction. Thus, ropivacaine may disrupt homeostasis and impair neural cells [5]. The clinical relevance of this information is insufficient to support a cause-effect relationship in this case report. Inflammatory injury is more commonly reported when continuous epidural anesthesia is used through epidural catheters and it affects the area in which they are injected. In this particular case, it is unlikely that the caudal epidural anesthetic injection can be held accountable for such an injury that far from the injection site [3, 11]. Furthermore, clonidine as adjunct was also administered epidurally, but a study evaluating neurotoxicity of this drug found no significant neurotoxic effects [16].

Another possible culprit for the development of such noteworthy neurological deficits is alcoholic chlorhexidine, an ubiquitous and effective bacterial cleansing agent [17]. Many cases of adhesive arachnoiditis were attributed to contamination of intrathecal or epidural local anaesthetic solution with noxious chemicals such as alcoholic chlorhexidine. It is very implausible that contamination occurred in this case. Further, there are recent data supporting the hypothesis that this substance can be used for skin antisepsis before subarachnoid block without increasing the risk of neurologic complications attributed to the local anesthetic [15].

It was also hypothesized that the patient might already have had and underlying disease that manifested after a trigger such as surgical-anesthetic trauma, as in multiple sclerosis and neuromyelitis optica [12]. In this manner, CSF was screened for the presence of oligoclonal bands and anti-aquaporin-4 IgG antibodies, but the tests were all negative.

4. Conclusion

In this report, there was a strong link between the surgical-anesthetic trauma and the appearance of the acute flaccid tetraplegia, although the exact etiology is not clear. Despite general anesthesia associated with caudal epidural block being well established in our clinical practice, there is lack of evidence regarding its safety and lack of data about its perioperative complications.

Some etiologies for this case report have been suggested such as spinal cord trauma, infectious and vascular causes, local anesthetic and noxious chemicals neurotoxicity and demyelinating diseases. In spite of thorough scrutiny, we were not able to define a single cause for the clinical manifestations. In this setting, the treatment goal was to provide support measures and rehabilitation of neurological deficits.

References

- [1] Suresh, S., Long, J., Birmingham, P. K., & De Oliveira Jr, G. S. (2015). Are caudal blocks for pain control safe in children? An analysis of 18,650 caudal blocks from the Pediatric Regional Anesthesia Network (PRAN) database. *Anesthesia & Analgesia*, 120 (1), 151-156.
- [2] Beyaz, S. G., Tokgöz, O., & Tüfek, A. (2011). Caudal epidural block in children and infants: retrospective analysis of 2088 cases. *Annals of Saudi medicine*, 31 (5), 494-497.
- [3] Meyer, M. J., Krane, E. J., Goldschneider, K. R., & Klein, N. J. (2012). Neurological complications associated with epidural analgesia in children: a report of 4 cases of ambiguous etiologies. *Anesthesia & Analgesia*, 115 (6), 1365-1370.
- [4] Jöhr, M. (2015). Regional anaesthesia in neonates, infants and children: an educational review. *European Journal of Anaesthesiology (EJA)*, 32 (5), 289-297.
- [5] Chen, Y., Yan, L., Zhang, Y., & Yang, X. (2019). The role of DRP1 in ropivacaine-induced mitochondrial dysfunction and neurotoxicity. *Artificial cells, nanomedicine, and biotechnology*, 47 (1), 1788-1796.
- [6] Desparmet, J. F. (1990). Total spinal anesthesia after caudal anesthesia in an infant. *Anesthesia & Analgesia*, 70 (6), 665-667.
- [7] Muckart, D. J., Bhagwanjee, S., & van der Merwe, R. (1997). Spinal cord injury as a result of endotracheal intubation in patients with undiagnosed cervical spine fractures. *Anesthesiology: The Journal of the American Society of Anesthesiologists*, 87 (2), 418-420.
- [8] Strafford, M. A., Wilder, R. T., & Berde, C. B. (1995). The risk of infection from epidural analgesia in children: a review of 1620 cases. *Anesthesia & Analgesia*, 80 (2), 234-238.
- [9] Martinez-Garcia, E., Pelaez, E., Roman, J. C., & Perez-Gallardo, A. (2005). Transverse myelitis following general and epidural anaesthesia in a paediatric patient. *Anaesthesia*, 60 (9), 921-923.
- [10] Jha S, Kumar R. Transverse myelitis following spinal anesthesia. *Neurol India*. 2006 Dec; 54 (4): 425-7.
- [11] Mukherjee D, Gautam S, Agarwal A, et al. Unexplained episode of sensory-motor deficit following lumbar epidural analgesia. *Korean J Pain*. 2019 Jan; 32 (1): 53-54.
- [12] Gunaydin B, Akcali D, Alkan M. Epidural anaesthesia for Caesarean section in a patient with Devic's Syndrome. *Anaesthesia*. 2001 Jun; 56 (6): 565-7.
- [13] Nishikawa T, Dohi S: Clinical evaluation of clonidine added to lidocaine solution for epidural anesthesia. *ANESTHESIOLOGY* 1990; 73: 853-9.
- [14] J. B. Dahl, L. Simonsen, T. Mogensen, J. H. Henriksen, and H. Kehlet, "The effect of 0.5% ropivacaine on epidural blood flow," *Acta Anaesthesiologica Scandinavica*, vol. 34, no. 4, pp. 308–310, 1990.
- [15] Sviggum, H. P., Jacob, A. K., Arendt, K. W., Mauermann, M. L., Horlocker, T. T., & Hebl, J. R. (2012). Neurologic complications after chlorhexidine antiseptics for spinal anesthesia. *Regional Anesthesia & Pain Medicine*, 37 (2), 139-144.
- [16] Torsten E. Gordh, Stina Ekman & Anne-Sofie Lagerstedt (1984) Evaluation of Possible Spinal Neurotoxicity of Clonidine, *Upsala Journal of Medical Sciences*, 89: 3, 266-273.
- [17] Killeen, T., Kamat, A., Walsh, D., Parker, A. and Aliashkevich, A. (2012), Severe adhesive arachnoiditis resulting in progressive paraplegia following obstetric spinal anaesthesia: a case report and review. *Anaesthesia*, 67: 1386-1394.