

Review Article

New Targets in Advanced Thyroid Cancer Refractory Iodine

Lynda Marianela Vásquez Proaño

Clinical Oncology, Ministry of Public Health, Quito, Ecuador

Email address:

vascog12@yahoo.es

To cite this article:Lynda Marianela Vásquez Proaño. New Targets in Advanced Thyroid Cancer Refractory Iodine. *Cancer Research Journal*.

Vol. 7, No. 2, 2019, pp. 39-44. doi: 10.11648/j.crj.20190702.12

Received: September 24, 2018; **Accepted:** October 12, 2018; **Published:** April 22, 2019

Abstract: The majority of deaths due to thyroid cancer occur in patients with advanced DTC refractory to radioactive iodine. The spectacular advances in molecular medicine of recent years have opened new therapeutic possibilities. Currently, there is general agreement that treatment with Tyrosine Kinase Inhibitors (TKI) should only be considered in patients with differentiated thyroid carcinoma refractory to radioactive iodine, with progressive and / or symptomatic metastatic disease that can not otherwise be treated locally. Most of these "new molecules" are multichannel inhibitors with varied action, which interact on different proteins such as RET, BRAF, cKIT, MET, EGFR, MAPK, PDGFR, etc. In addition, they have the additional advantage that they markedly prevent angiogenesis by acting on VEGFR 1, 2, and 3. TKI are associated with progression-free survival but not curative. Also, causes adverse effects that can affect the quality of life. The prolongation of progression-free survival has been demonstrated with sorafenib and lenvatinib compared with placebo in two phase III trials. These two drugs have been approved by the FDA and the European Medicines Agency for use in patients refractory to radioactive iodine with metastatic disease. Based on the Phase II Trials there are other Tyrosine Kinase Inhibitors (TKI) available such as sunitinib, axitinib or pazopanib that can produce some kind of clinical benefit and therefore need further investigation.

Keywords: Target, Cancer, Thyroid

1. Introduction

About One third of patients with differentiated thyroid cancer (DTC) who develop metastatic disease are refractory to radioactive iodine. [1].

Between 1975 and 1999, 15 clinical trials with cytotoxic chemotherapy were initiated. Treatment with doxorubicin and cisplatin only achieved complete remissions in 12% of patients with thyroid carcinoma of follicular origin. The combination of bleomycin, doxorubicin and cisplatin achieved an average survival of 11 months and the response to etoposide was zero. Something similar happened in patients with medullary thyroid carcinoma, in which only 25% responded to treatment partially or completely. [2].

Fortunately, today things have changed and we are witnessing a new leap in the treatment of thyroid carcinoma. The spectacular advances in molecular medicine of recent years have opened new therapeutic possibilities. [2].

New treatment strategies are needed, therefore, new strategies under investigation include targeted therapy (eg

axitinib and sorafenib), vascular disrupting agents (such as combretastatin A4 phosphate, human VEGF monoclonal antibodies, eg bevacizumab, cetuximab), tumor suppressor gene therapy. Until now, none of these agents has shown good results in the treatment of anaplastic thyroid carcinoma, so further research is needed to contrast the aggressiveness of this tumor. [12].

Currently, there is general agreement that treatment with multikinase inhibitors (MKI) should only be considered in patients with differentiated thyroid carcinoma refractory to radioactive iodine, with progressive and / or symptomatic metastatic disease that can not otherwise be treated locally. The reasons for such limitations arise from clinical trials. Given that the first multicentre therapeutic trial of a Tyrosine Kinase Inhibitor was performed in progressed differentiated thyroid carcinoma; the evidence favored the clinical use of Tyrosine Kinase Inhibitors but also revealed limitations in terms of drug toxicity and patient eligibility. [1].

Most of these "new molecules" are multichannel inhibitors with varied action, which interact (selectively or together) on

various proteins such as RET, BRAF, cKIT, MET, EGFR, MAPK, PDGFR, etc. In addition, they have the additional advantage that they markedly prevent angiogenesis by acting on VEGFR 1, 2, and 3. [2].

The prolongation of progression-free survival has been demonstrated with sorafenib and lenvatinib compared with placebo in two phase III trials. These two drugs have been approved by the FDA and the European Medicines Agency for use in patients refractory to radioactive iodine with metastatic disease. [1].

It should be noted, and more in the context of thyroid carcinoma, that the use of tyrosine kinase inhibitors has been associated with the appearance of thyroid dysfunction. This effect has been seen especially after the administration of sunitinib and sorafenib. The most common dysfunction is the development of hypothyroidism, which has sometimes been described after a brief episode of thyrotoxicosis (mimicking the clinical stages of thyroiditis). [2] For this reason it is recommended to carefully and frequently evaluate the thyroid function in any patient treated with these molecules. [2].

2. Method

A bibliographic review on the new molecular targets in iodine-refractory thyroid cancer was carried out over the last years based on a search of globally recognized journals such as the guidelines of the American Thyroid Association (ATA), NCCN guides, Journal of Clinical Oncology, The Lancet, etc.

3. Result

Unfortunately, most deaths due to thyroid cancer occur in patients with advanced DTC refractory to radioactive iodine. [1].

In studies based on treatment with doxorubicin and cisplatin only achieved complete remissions in 12% of patients with thyroid carcinoma of follicular origin. The combination of bleomycin, doxorubicin and cisplatin achieved an average survival of 11 months and the response to etoposide was zero. Something similar happened in patients with medullary thyroid carcinoma, in which only 25% responded to treatment partially or completely. [2].

External beam radiation therapy has a limited role in patients with advanced differentiated thyroid carcinoma or medullary thyroid carcinoma and is not commonly used. Retrospective studies have found controversial about the use of external beam radiotherapy. The NCCN guidelines and the guidelines of the American Thyroid Association (ATA) suggest that external beam radiation therapy should be considered for patients with locally unresectable thyroid carcinoma or medullary thyroid carcinoma to optimize locoregional control. External beam radiation therapy can also be considered for patients with distant metastases such as in the brain and spinal column. [3].

In differentiated thyroid cancer, distant metastases have greater benefit if they are iodine-refractory iodine, small and localized in the lungs; otherwise, only palliation and

prolongation of survival is feasible. Chemotherapy is not indicated and participation in clinical trials should be encouraged. [12].

In medullary thyroid carcinoma in advanced disease, mono- or poly-chemotherapy has not shown a significant clinical benefit (<20% response rate), whereas radiotherapy is frequently used palliatively. [12].

In anaplastic carcinoma of the thyroid the most common single cytotoxic agent used against anaplastic carcinomas is doxorubicin alone or in combination with cisplatin. The results have been disappointing. The addition of bleomycin or other agents does not improve the efficacy of this combination. Recently, paclitaxel has been used in clinical trials and has shown some improvement in response rates, but not in survival. [12].

Currently, there is general agreement that treatment with Tyrosine Kinase Inhibitors (TKI) should only be considered in patients with differentiated thyroid carcinoma refractory to radioactive iodine, with progressive and / or symptomatic metastatic disease that can not otherwise be treated locally. [1].

- When considering the use of Tyrosine Kinase Inhibitors (TKI), these factors should be taken into account:

- TKI are associated with progression-free survival but not curative.

TKI causes adverse effects that can affect the quality of life.

The natural history of differentiated thyroid and medullary thyroid cancer with rates of disease progression ranging from a few months to a few years. [14].

Patients who are asymptomatic are not those indicated to receive TKI particularly if the adverse effects of the treatment affect the quality of life. On the other hand, if the disease progresses rapidly, they may have a greater benefit from TKI; even when adverse effects occur..

Optimal management of the adverse effects of TKI is also essential. Especially because of the adverse dermatological, hypertensive and gastrointestinal effects, since dose modification must be done, including dose reduction. [14].

In a multicentre, randomized, double-blind, placebo-controlled trial. Phase 3 study (DECISION), sorafenib (400 mg orally twice daily) was investigated in patients with cancer refractory to radioactive iodine or metastatic differentiated thyroid cancer that had progressed within the last 14 months. Adult patients (≥ 18 years of age) with this type of cancer were enrolled from 77 centers in 18 countries. As inclusion criteria, participants had to have at least one lesion measurable by CT or MRI according to the criteria for evaluation of response in solid tumors (RECIST), with PS 0-2; adequate functioning of bone marrow, liver and renal function; and serum thyroid stimulating hormone concentration less than 0.5 mIU / L. The primary endpoint was progression-free survival, assessed every 8 weeks. [11].

About 5% of patients develop differentiated thyroid carcinoma refractory to radioactive iodine, which generally does not respond to conventional chemotherapy, resulting in a long-term overall survival of approximately 10%. On November 22, 2013, the FDA approved sorafenib for the

treatment of refractory, progressed thyroid cancer; based on the results of a randomized, placebo-controlled trial (n: 471) that demonstrated a statistically significant improvement in progression-free survival [PFS; HR, 0.59; 95% confidence interval (CI), 0.45-0.76; $P < 0.001$, with a median PFS time of 10.8 months in the sorafenib arm and 5.8 months in the placebo arm. [4].

Sorafenib has clinically relevant antitumor activity in patients with metastatic refractory thyroid carcinoma, resistant

to iodine, with a general clinical benefit rate of 77%, a median PFS of 79 weeks and a generally acceptable safety profile. These results represent a significant advance over chemotherapy in both the response rate and the PFS. [10].

Sorafenib significantly improved progression-free survival compared to placebo in patients with differentiated iodine-refractory thyroid cancer. These results suggest that sorafenib is a new treatment option for patients with thyroid cancer refractory iodine. [11].

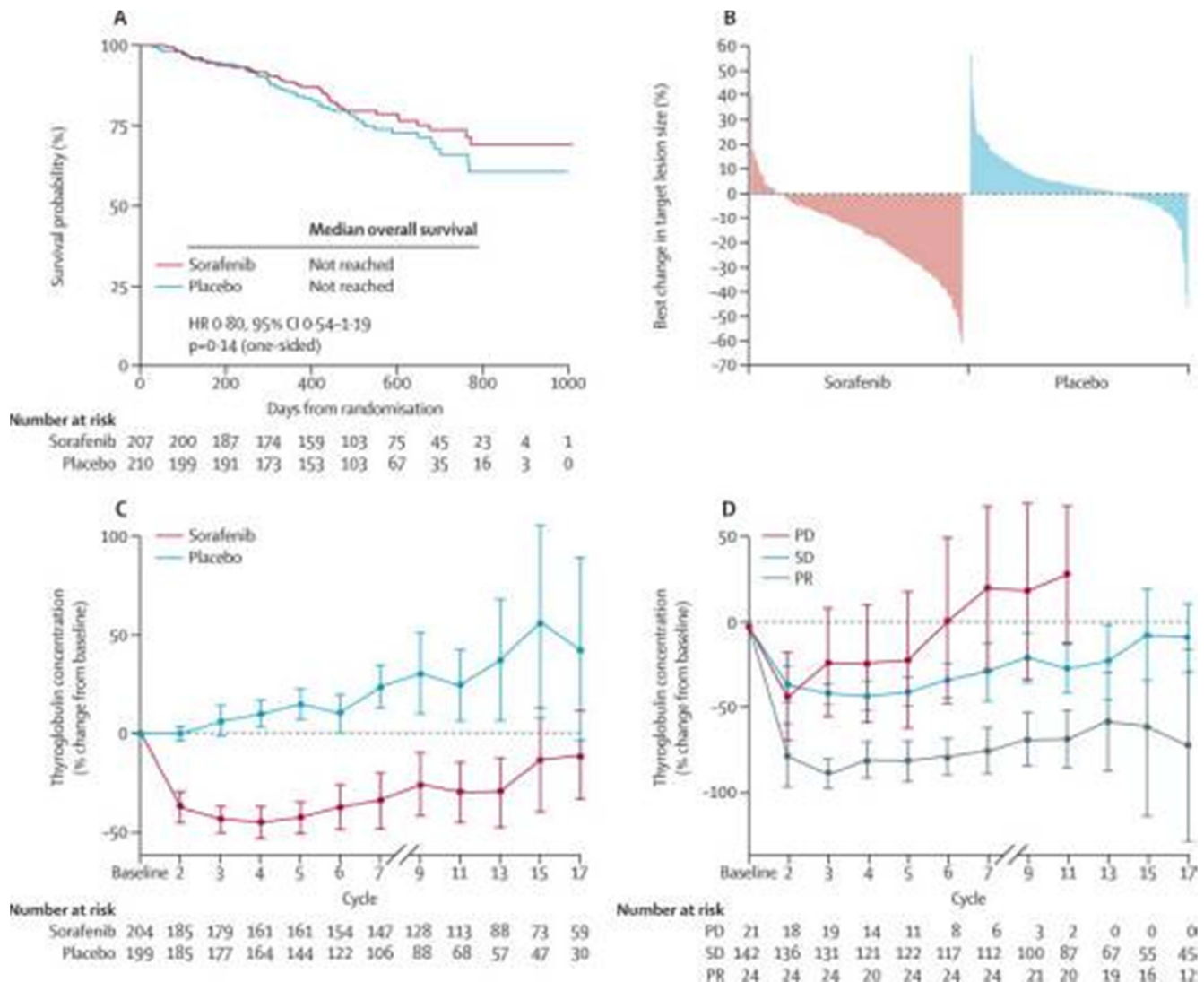


Figure 1. Decision study. Sorafenib vs Placebo in Advanced Thyroid Cancer Refractory Iodine. Overall survival, changes in target lesions and serum thyroglobulin concentrations (A) Kaplan-Meier global survival curve. (B) Cascade diagram showing the best change in the size of the target lesion for individual patients. (C) Changes in thyroglobulin concentrations according to the treatment group. (D) Changes in thyroglobulin concentrations in patients treated with sorafenib according to the tumor response. The error bars in (C) and (D) are 95% CI. HR = risk ratio. PD = progressive disease. SD = stable disease. PR = partial response. [11].

Lenvatinib is approved for thyroid cancer differentiated by the FDA, but has also been studied in medullary thyroid cancer. [15].

Lenvatinib is an oral tyrosine kinase inhibitor, which inhibits the kinase activities of the VEGF receptors VEGFR1 (FLT1), VEGFR2 (KDR), VEGFR3 (FLT4), FGFR1, 2, 3 and 4, the derived growth factor receptor of alpha platelets (PDGFR α), KIT and RET. A single randomized controlled trial [E7080-G000303 or SELECT (here in after referred to as Study 303)] together with

a safety database of 1,108 patients who were exposed to lenvatinib in several clinical trials was submitted to support approval in the United States. [4].

In study 303, the most common adverse reactions were hypertension (73% vs. 16% placebo), fatigue (67% vs 35%), diarrhea (67% vs.17%), arthralgia / myalgia (62% vs.28%), decreased appetite (54% vs.18%), decreased weight (51% vs 15%), nausea (47% vs. 25%), stomatitis (41% vs. 8%),

headache (38% vs. 11%), vomiting (36% vs. 15%), proteinuria (34% vs. 3%), palmar plantar erythrodysesthesia (32% vs. 1%), abdominal pain (31% vs. 11%), and dysphonia (31% vs. 5%). Haemorrhagic events occurred in 35% of patients treated with lenvatinib versus 18% who received placebo. The use of lenvatinib also resulted in an increase in the levels of thyroid stimulating hormone (TSH). The etiology of this increase is not understood, in 68% of the patients who received lenvatinib and in 5% of the patients who received placebo there were adverse reactions that led to dose reductions: 18% of the patients discontinued the treatment or with lenvatinib and 5% suspended placebo due to adverse reactions. The most frequent adverse reactions (at least 10%) that resulted in the reduction of the dose of lenvatinib were hypertension (13%), proteinuria (11%), decreased appetite (10%) and diarrhea (10%). Adverse events of grade 3 to 4 also occurred more frequently in the lenvatinib arm. [4].

Lenvatinib demonstrated antitumor activity in phase I studies against several solid tumors, including advanced medullary thyroid cancer. This phase II study demonstrated an objective response rate (ORR) for lenvatinib of 36% in patients with progressive medullary thyroid carcinoma. The ORR was similar between patients with (35%) and without previous treatment with anti-VEGF (36%). It is associated with greater tumor reduction and prolonged progression-free survival. These findings support the continued investigation of lenvatinib for the management of medullary thyroid carcinoma. [5].

In 2012, the FDA approved cabozantinib for the same indication based on the efficacy of XL184 (Cabozantinib) in the advanced medullary thyroid cancer (EXAM) trial. [8] Which is a double-blind phase III trial comparing oral cabozantinib at 140 mg per day with a placebo in 330 patients with documented radiographic progression of metastatic medullary thyroid carcinoma. The main end point is PFS. Other end points are the response rate, overall survival and safety. This study also used a 2:1 randomization scheme, but unlike the ZETA trial, the EXAM study did not allow the active drug to cross. The study reached its main endpoint of PFS prolongation: 11.2 months for the use of cabozantinib and 4 months for the placebo (hazard ratio, 0.28, 95% CI, 0.19 to 0.4; $P < .001$). Objective rates of tumor response and biochemical responses were also significantly improved with cabozantinib. [8].

The frequent occurrence of weakness, arterial hypertension, gastrointestinal discomfort (abdominal pain, diarrhea, constipation, vomiting and anorexia), skin lesions (erythema palmo plantar or hand-foot syndrome) or fatigue have been described. Patients may also report paresthesias in the hands and feet, hypopigmentation, instability, blurred vision, alteration in the sense of taste or flu-like symptoms. The appearance of anemia, leukopenia or decreased platelet count has been seen, with an increased risk of bleeding. Rarely (less than 10% of cases) there may be alterations in liver or kidney function tests, changes in the ionogram or appearance of severe hemorrhage. Usually, the adverse effects are dose-dependent, so they tend to be reduced by temporarily stopping the drug or decreasing the dose. [2].

Currently, the nonrandomized phase I / II trial of the

combination of vandetanib plus bortezomib is recruiting patients with solid tumors (including medullary thyroid carcinoma). [7].

Cabozantinib and vandetanib are approved by the FDA for the treatment of advanced medullary thyroid carcinoma. [3].

On April 6, 2011, the FDA approved vandetanib [6], which is an oral inhibitor of RET kinase, PDGFR and EGFR [13]; for the treatment of advanced thyroid cancer in patients with unresectable, locally advanced disease or metastatic disease [6] based on the ZETA study. [8].

Patients were randomized 2:1 with vandetanib, 300 mg / d orally ($n = 231$), or placebo ($n = 100$). The main objective was the demonstration of improvement in progression-free survival (PFS) with vandetanib compared with placebo. Another approach was to evaluate the global survival and the objective response rate. The analysis of PFS randomized to vandetanib (hazard ratio: 0.35, 95% confidence interval: 0.24 to 0.53, $p < 0.0001$). The objective response rate for the vandetanib arm was 44% compared to 1% for the placebo arm. The most frequent grade 3 and 4 toxicities ($> 5\%$) were diarrhea and / or colitis, hypertension, fatigue, hypocalcemia, skin rash and prolongation of the QT interval. This approval was based on a statistically significant and clinically significant improvement in the PFS. [6].

4. Discussion

Based on the Phase II Trials there are other Multicinas Inhibitors available such as sunitinib, axitinib, cabozantinib or pazopanib that may produce some kind of clinical benefit but only phase III results with vandetanib are expected in the near future. [1].

Axitinib is a potent selective inhibitor of VEGFR 1, 2 Y 3 and 10 times less potent to inhibit PDGFR and C-kit. A phase I trial of 36 patients with advanced solid tumors took axitinib 5 mg twice daily. It was shown that axitinib was rapidly absorbed, with peak plasma concentrations from 2 to 6 hours after administration. Based on the recognized importance of thyroid cancer angiogenesis and preliminary evidence of antitumor activity, the activity of this drug was investigated in a Phase II Trial. [9].

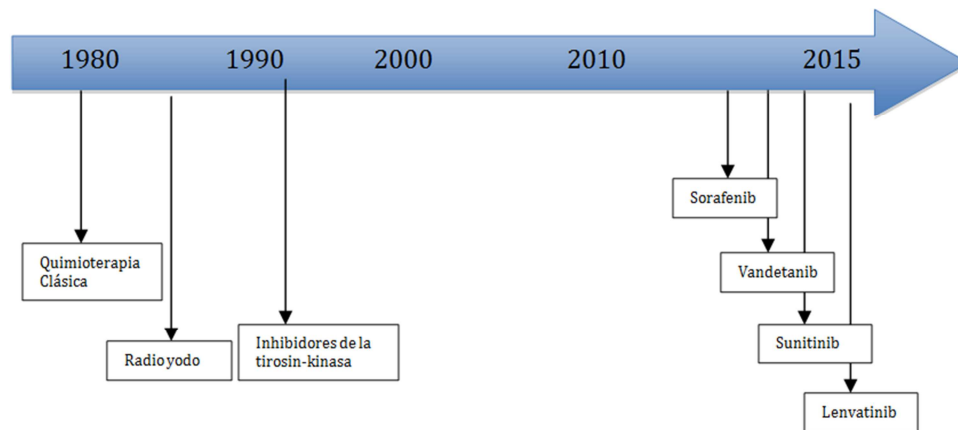
Axitinib has significant antitumor activity in all histological subtypes of thyroid cancer, as evidenced by the high response rate, the prolonged duration of response and overall survival. The modulation of VEGFR-2 and VEGFR-3 by axitinib demonstrates the selectivity of this oral inhibitor against VEGFRs. These results also validate the therapeutic efficacy of VEGFR inhibition in patients with advanced thyroid cancer. [9].

Pazopanib is another targeted agent that has shown promising activity in patients with differentiated thyroid cancer and in preclinical studies of anaplastic thyroid cancer. These results led to a phase II study ($N = 16$) of pazopanib in patients with advanced anaplastic thyroid cancer. However, the data from this trial showed minimal activity with pazopanib in this context; no confirmed RECIST responses were observed. [15]

Table 1. Therapeutic effects of different TKI in clinical trials recruiting patients with CDT or CMT.

Drug	Histologic subtype	Number of patients	Phase	RP (%)	SD%	SD> 6 months (%)	mPFS (weeks)
Motesanib	CMT	91	II	2	81	48	48
	CDT	93	II	14	67	35	40
	CMT	23	II	35	57		
Sunitinib	CMT	6	II		83		28
	CMT	15	II	33	27		
	CDT	31	II	14	68		
	CMT	30	II	20	73	53	
Vandetanib	CMT	19	II	16	64	53	
	CMT	331	III	45	42	83	30.5 months
	CMT	16	II	6	87	56	60
	CDT	41	II	15		53	79
Sorafenib	CDT	30	II	23			
	CDT	31	II	25	34		
	CMT	37	I	29		41	
XL184	CMT	11	I	18	27		
	CDT	45	II	31	42		
Pazopanib	CDT	37	II	49			

MT = Medullary Thyroid Carcinoma, CDT = Differentiated Thyroid Carcinoma, RP = Partial Response, SD = Stable Disease, mPFS = Median Progression Free Survival [12].

**Figure 2.** Evolution of treatment of advanced thyroid cancer refractory iodine. [16].**Table 2.** Most frequent Adverse Effects related to TKI. [17].

Adverse effects	Tyrosine kinase inhibitors (TKI) Frequency
Fatigue and weight loss	Everybody (26-59%)
Diarrhea	Everybody (30-68%)
Arterial hypertension	Everybody (30-67%)
Rash	Everybody (20-50%)
Increase in TSH	Everybody (30-60%)
Hand-foot syndrome	Sorafenib (76%)
Alopecia	Sorafenib (67%)
Proteinuria	Lenvatinib (31%)
Mucositis	Everybody (30%)
Hypocalcemia	Sorafenib (18%)
QTc prolongation	Vandetanib (23%, G>3 14%)

5. Conclusions

The present study concludes the importance of the new molecular targets for the treatment of advanced thyroid cancer, refractory iodine, since around one third of patients with differentiated thyroid cancer (DTC) develop metastatic disease. New treatment strategies have been developed which include targeted therapy (eg, axitinib and sorafenib), vascular disrupting agents (such as combretastatin A4 phosphate,

human VEGF monoclonal antibodies, eg bevacizumab, cetuximab), tumor suppressor gene therapy.

Currently, there is general agreement that treatment with Tyrosine Kinase Inhibitors (TKI) should only be considered in patients with differentiated thyroid carcinoma refractory to radioactive iodine, with progressive and / or symptomatic metastatic disease that can not otherwise be treated locally.

Patients who are asymptomatic are not those indicated to receive TKI particularly if the adverse effects of the treatment affect the quality of life. On the other hand, if the disease

progresses rapidly, they may have a greater benefit from TKI; even when adverse effects occur.

The prolongation of progression-free survival has been demonstrated with sorafenib and lenvatinib compared with placebo in two phase III trials. These two drugs have been approved by the FDA and the European Medicines Agency for use in patients refractory to radioactive iodine with metastatic disease.

fenib has clinically relevant antitumor activity in patients with metastatic refractory thyroid carcinoma, resistant to iodine, with a general clinical benefit rate of 77%, a median PFS of 79 weeks and a generally acceptable safety profile. These results represent a significant advance over chemotherapy in both the response rate and the PFS.

Lenvatinib is approved for thyroid cancer differentiated by the FDA, but has also been studied in medullary thyroid cancer.

Cabozantinib and vandetanib are approved by the FDA for the treatment of advanced medullary thyroid carcinoma.

Based on the Phase II Trials there are other Tyrosine Kinase Inhibitors (TKI) available such as sunitinib, axitinib or pazopanib that can produce some kind of clinical benefit and therefore need further investigation.

References

- [1] Eizaguirrea Garcilaso Riesco, Galofré Juan Carlos, Grande Enrique et al., Spanish Consensus for the management of patients with advanced radioactive iodine refractory differentiated thyroid cancer, *Endocrinología y Nutrición*, Elsevier 2016; 63 (4):e17- e24.
- [2] Galofré Juan Carlos, Gómez-Sáez José Manuel, Alvarez Escola Cristina et al., Uso de nuevas moléculas en el tratamiento del cáncer avanzado de tiroides, *Endocrinología y Nutrición*, Elsevier Doyma 2011; 58 (8):381- 386, doi:10.1016/j.endonu.2011.07.001.
- [3] Cabanillas Maria E, Amir Habra Mouhammed, Anti-tumour treatment, Lenvatinib : Role in thyroid cancer and other solid tumors, The University of Texas MD Anderson Cancer Center, Houston, TX, USA, *Cancer Treatment Reviews*, Elsevier, 42 (2016) 47-55, doi.org/10.1016/j.ctrv.2015.11.003.
- [4] Nair Abhilasha, Lemery Steven J., Yang Jun et al., FDA Approval Summary: Lenvatinib for Progressive, Radio-iodine-Refractory Differentiated Thyroid Cancer, *Clinical Cancer Research*, American Association for Cancer Research, 21 (23) December 1, 2015, doi: 10.1158/1078-0432.CCR-15-1377.
- [5] Schlumberger Martin, Barbara Jarzab Barbara, Cabanillas Maria E et al., A Phase II Trial of the Multitargeted Tyrosine Kinase Inhibitor Lenvatinib (E7080) in Advanced Medullary Thyroid Cancer, *Clinical Cancer Research*, 22 (1) Aug 26, 2015, page 44-53, doi: 10.1158/1078-0432. CCR-15-1127.
- [6] Thornton Katherine, Kim Geoffrey, Maher V. Ellen et al., Vandetanib for the Treatment of Symptomatic or Progressive Medullary Thyroid Cancer in Patients with Unresectable Locally Advanced or Metastatic Disease: U.S. Food and Drug Administration Drug Approval Summary, *CCR Perspectives in Drug Approval*, American Association for Cancer Research, *Clin Cancer Res*; 18 (14) Jun 4, 2012, pages 3722-30 doi: 10.1158/1078-0432.CCR-12-0411.
- [7] Fallahi Poupak, Di Bari Flavia, Ferrari Silvia Martina et al., Selective use of vandetanib in the treatment of thyroid cancer, *Drug Design, Development and Therapy*, 2015:9 3459–3470, doi.org/10.2147/DDDT.S72495.
- [8] Haddad Robert I., Dana - Farber Cancer Institute, Harvard Medical School; and Brigham and Women's Hospital, Boston, MA, How to Incorporate New Tyrosine Kinase Inhibitors in the Treatment of Patients With Medullary Thyroid Cancer, *Journal of Clinical Oncology*, Volume 31 Number 29 October 10 2013: pp 3618-3620, doi: 10.1200/JCO.2013.51.5098.
- [9] Cohen Ezra E. W., Rosen Lee S., Vokes Everett E. et al., Axitinib Is an Active Treatment for All Histologic Subtypes of Advanced Thyroid Cancer: Results From a Phase II Study, *American Society of Clinical Oncology, J Clin Oncol* 26:4708-4713, Volume 26, Number 29, October 10 2008, doi: 10.1200/JCO.2007.15.9566.
- [10] Abramson Vandana Gupta, Troxel Andrea B., Nellore Anoma et al., Phase II Trial of Sorafenib in Advanced Thyroid Cancer, *American Society of Clinical Oncology*, Volume 26 Number 29 October 10 2008, *J Clin Oncol* 26:4714-4719, doi: 10.1200/JCO.2008.16.3279.
- [11] Brose Marcia S, Nutting Christopher M, Jarzab Barbara et al., Sorafenib in radioactive iodine-refractory, locally advanced or metastatic differentiated thyroid cancer: a randomised, double-blind, phase 3 trial, *www.thelancet.com*, Jul 26, 2014, 384 (9940): pages 319-28, doi.org/10.1016/S0140 6736 (14) 60421-9
- [12] Pacini F., Castagna M. G., Brilli L., Pentheroudakis G. et al, on behalf of the ESMO Guidelines Working Group, Thyroid cancer: ESMO Clinical Practice Guidelines for diagnosis, treatment and follow-up, clinical practical guidelines, *Annals of Oncology*, Volume 23, Issue suppl_7, 1 October 2012, Pages vii110–vii119, doi:10.1093/annonc/mds230.
- [13] Wells Jr Samuel A., Robinson Bruce G., Gagel Robert F et al, Vandetanib in Patients With Locally Advanced or Metastatic Medullary Thyroid Cancer: A Randomized, Double-Blind Phase III Trial, *American Society of Clinical Oncology*, January 10,2012. 30 (2): pages 134-141, doi: 10.1200/JCO.2011.35.5040.
- [14] Haddad Robert I, MD Chair, Farber Dana, Brigham and Women Cancer Center, Lydiatt William M., MD Vice-Chair Fred, Pamela Buffett Cancer Center, Bischoff Lindsay, MD Vanderbilt-Ingram Cancer Center, *Guías NCCN*, 30 (2): page THYR-B, January 10 2012.
- [15] Corey J. Langer, MD, FACP, Tratamiento del cáncer de tiroides, *Clinical Care Options, LLC*, In Practice, 4/1/16, USF Health, chapter 4, page 12.
- [16] Brea Mayte, Navarro Ana, Avances en Cáncer de Tiroides, *Sociedad Española de Oncología Médica*, 2015, page 2.
- [17] Schmidt Angélica, Cross Graciela, Pitoia Fabián, Metástasis a distancia en cáncer diferenciado de tiroides: diagnóstico y tratamiento, Hospital de Clínicas «José de San Martín», División Endocrinología, Universidad de Buenos Aires (UBA), Buenos Aires, Argentina, *rev argent endocrinol metab*. 2017; 54 (2):92–100, doi.org/10.1016/j.raem.2017.05.001 0326-4610.