
Purple urine bag syndrome as a rare manifestation of urinary tract infection: A case report

Reza Elahi¹, Seyed Morteza Tabatabaee¹, Seyed Alireza Heydariezade¹, Mitra Ranjbar^{2,*}

¹Department of Internal Medicine, Iran University of Medical Sciences, Tehran, Iran

²Department of Infectious Diseases, Iran University of Medical Sciences, Tehran, Iran

Email address:

mitrananjbar@yahoo.com (M. Ranjbar)

To cite this article:

Reza Elahi, Seyed Morteza Tabatabaee, Seyed Alireza Heydariezade, Mitra Ranjbar. Purple Urine Bag Syndrome as a Rare Manifestation of Urinary Tract Infection: A Case Report. *Clinical Medicine Research*. Vol. 3, No. 6, 2014, pp. 171-173. doi: 10.11648/j.cmr.20140306.13

Abstract: Purple urine bag syndrome (PUBS) is purple discoloration of urinary catheter, tubing and bag and it is a rare and uncommon manifestation of urinary tract infection. Female gender, constipation, urinary tract infection, dementia, alkaline urine and high urinary bacterial counts are main risk factors. Here we report a 70 year old woman living in a nursing home presented with diarrhea, decreased oral intake and purple urine. The urine was evaluated and urine analysis showed PH=7 and pyuria. The result of urine culture was growth of more than 100000 colony of *Proteus Mirrabilis* sensitive to Imipeneme. The patient condition improved after antibiotic therapy. The main reason of this phenomenon is not clearly recognized but some authors believe that Indigo (blue pigment) and Indirubin (red pigment) which are metabolite derivate of tryptophan can cause this uncommon discoloration. This condition is benign without any serious consequences and the treatment of underlying disease should be considered.

Keywords: Urinary Tract Infection

1. Introduction

Purple urine bag syndrome (PUBS) is purple discoloration of urinary catheter, tubing and bag and it is a rare and uncommon manifestation of urinary tract infection (UTI) [1]. Although the main cause of this phenomenon is not well known, there are some risk factors which precipitate patients to develop purple urine. Female gender, constipation, urinary tract infection, dementia, alkaline urine and high urinary bacterial counts are main risk factors [2-5]. PUBS is a benign condition which do not seek specific treatment but management of underlying medical problem is more important than PUBS itself. Although this phenomenon is benign, it can cause great anxiety for the patient and caregivers. The physician might think about some important nephropathy e.g nephritic syndrome and would descide to do kidney biopsy and some oter unnescessary interventions. The main helpful and important point in patient's clinical history, is presenting of PUBS with diarrhea at the beginning which is an unusual presentation.

2. Case Presentation

A 70 year old woman living in a nursing home with past medical history of diabetes, stroke, chronic kidney disease and ischemic heart disease presented with diarrhea, decreased oral intake and purple urine. Her daily activity was limited and she was bedridden most of the day. The patient had a history of hospitalization because of atrial fibrillation and aspiration pneumonia four months before recent admission and had an indwelling urinary catheter for these four months. The physical examination was unremarkable except purple discoloration of urine and patient didn't have fever (temperature=36.5°C). The laboratory investigation revealed following results. The hemoglobin level was 11.5 mg/dl (MCV 93 fl), the leukocyte count $12.4 \times 10^3/\text{mm}^3$ with 80% polymorphonuclear cells and the platelet count $398 \times 10^3/\text{mm}^3$. The serum level of urea and creatinine was 114 and 1.8 mg/dl respectively (normally 17-43 and 0.5-1.5 mg/dl), aspartate aminotransferase, alanine aminotransferase, alkaline phosphatase and bilirubin level was normal. The prothrombin time (PT) and partial tromboplastin time (PTT) was normal and serum albumin level was 2.2 g/dl (normally 3.5-5.5 g/dl). Erythrocyte sedimentation rate was 33 mm/h.

The urine analysis showed PH=7 and the dipsticks revealed the excretion of protein (trace) and blood (2+). Microscopic evaluation of urine showed WBC (many), RBC (4-6) and bacteria (moderate). The urine culture was sent and showed growth of more than 100000 colony of *Proteus Mirrabilis* sensitive to imipeneme and resistant to sulphamethaxazole and nitrofurantoin. Patient underwent antibiotic therapy with Imipenem. The urine bag changed after 24 hours and discoloration of urine bag and catheter diminished. The patients' condition improved after 5 days and she discharged after one week.

3. Discussion

PUBS is a rare complication of UTI in long standing catheterized patients. Its prevalence reported 8.3%-16.7% in few studies [4, 6] but there is not any report of this syndrome in our country, Iran. Risk factors for occurring purple urine include female gender, constipation, old age, urinary tract infection, dementia, alkaline urine, high urinary bacterial counts and plastic urinary catheter and bag. Our patient's characteristics were compatible with mentioned risk factors except constipation and urinary PH. The main risk factor for developing PUBS is the history of chronic urinary catheterization. Our patient had a four-month history of catheterization plus risk factors like old age, female gender and living in nursing home. Constipation can cause bacterial over growth of intestinal normal flora which can precipitate patients to develop purple urine but our patient presented with diarrhea and this symptom is not like other case reports. In addition, although the alkaline urine is one of risk factors, our patient urine was not alkaline.

Literature review reveals that urinary tract infection with some bacterial species is more common in patients with PUBS. *Proteus* species, *Enterococcus* species, *Pseudomonas* species, *Morganella* species, *Escherichia coli* and *Klebsiella pneumonia* are among these species [7-9]. *Citrobacter* species, *Staphylococcus* species, *Streptococcus* species and even Methicillin-resistant *Staphylococcus Aureus* are seen in some cases but these species are not common in PUBS [10]. The urine culture of our patient showed the growth of *Proteus Mirrabilis* which is compatible with literature review.

There is not a general consensus on the main reason of developing purple urine in these patients, but some authors believe that metabolite derivate of tryptophan can cause this uncommon discoloration [6, 11]. Indole is produced by metabolism of tryptophan in gastrointestinal tract and absorb by liver. Indoxyl sulphate is the second derivate of this pathway that is made by conversion of indole in the liver and excretes to urine. Then bacterial indoxyl sulphatase catabolize indoxyl sulphate to indoxyl and finally, indoxyl turns to Indigo (blue pigment) and Indirubin (red pigment) in alkaline urine. The interaction of these pigments with plastic urinary bag and catheter cause purple discoloration of urine.

4. Conclusion

Rare incidence of this unusual complication of UTI can cause rigorous treatment and unnecessary interventions by caregivers. This condition is benign most of the times without serious consequences and the treatment of underlying disease should be considered. If patients are asymptomatic, changing urinary bag can resolve the problem and there is no need to rigorous treatment. But symptomatic patients need specific treatment in according to urinary culture.

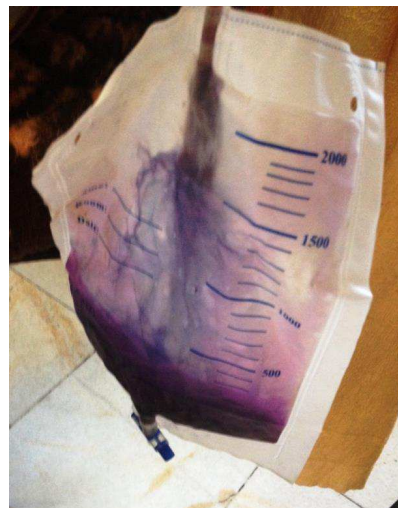


Figure 1. purple urine and cathater

References

- [1] Agapakis, D., et al., Purple Urine Bag Syndrome: a case report of an alarming phenomenon. *Hippokratia*, 2014. 18(1): p. 92-94.
- [2] Dealler, S.F., et al., Purple urine bags. *J Urol*, 1989. 142(3): p. 769-70.
- [3] Muneoka, K., et al., [Biochemical and bacteriological investigation of six cases of purple urine bag syndrome (PUBS) in a geriatric ward for dementia]. *Nihon Ronen Igakkai Zasshi*, 2008. 45(5): p. 511-9.
- [4] Shiao, C.C., et al., Purple urine bag syndrome: a community-based study and literature review. *Nephrology (Carlton)*, 2008. 13(7): p. 554-9.
- [5] Su, F.H., et al., Case analysis of purple urine-bag syndrome at a long-term care service in a community hospital. *Chang Gung Med J*, 2005. 28(9): p. 636-42.
- [6] Lin, H.-H., et al., Purple urine bag syndrome: a case report and review of the literature. *J Intern Med Taiwan*, 2002. 13: p. 209-12.
- [7] Koh, K.S. and V.H. Chong, Purple urine bag syndrome (PUBS): an unusual and rare manifestation of a common condition. *Ann Acad Med Singapore*, 2013. 42(12): p. 700-1.
- [8] Bhattarai, M., et al., Purple urine bag syndrome may not be benign: a case report and brief review of the literature. *Case Rep Infect Dis*, 2013. 2013: p. 863853.

- [9] Al Montasir, A. and A. Al Mustaque, Purple urine bag syndrome. *J Family Med Prim Care*, 2013. 2(1): p. 104-5.
- [10] Yaqub, S., S. Mohkum, and K.N. Mukhtar, Purple urine bag syndrome: A case report and review of literature. *Indian J Nephrol*, 2013. 23(2): p. 140-2.
- [11] Fu-Hsiung Su, B., et al., Case analysis of purple urine-bag syndrome at a long-term care service in a community hospital. *Chang Gung Med J*, 2005. 28(9): p. 636-42.