

Reinsertion of the Achilles Tendon with Bony Anchor in Insertional Achilles Tendinitis with Haglund's Deformity

Zengui Francis Zifa^{1,*}, El Adaoui Oussama^{1,2}, Fadili Omar¹, Haddoun Ahmed Reda^{1,2},
Fadili Mustapha^{1,2}

¹Trauma Surgery and Orthopaedics Department, Ibn Rochd Hospital University Center, Casablanca, Morocco

²Faculty of Medicine and Pharmacy of Casablanca, Hassan II University, Casablanca, Morocco

Email address:

zifafrancis@outloo.fr (Zengui Francis Zifa)

*Corresponding author

To cite this article:

Zengui Francis Zifa, El Adaoui Oussama, Fadili Omar, Haddoun Ahmed Reda, Fadili Mustapha. Reinsertion of the Achilles Tendon with Bony Anchor in Insertional Achilles Tendinitis with Haglund's Deformity. *Advances in Surgical Sciences*. Vol. 11, No. 1, 2023, pp. 1-4. doi: 10.11648/j.ass.20231101.11

Received: July 10, 2022; Accepted: July 25, 2022; Published: May 25, 2023

Abstract: Haglund's deformity is a common cause of hindfoot pain in adults and functional disability. Conservative treatment is effective often. Surgery is required only in intractable cases. Many surgical treatments in a Haglund deformity have been described. After resect and debridement, an anchor suture may use to reattach Achille's tendon. This study aims to show the place of the suture anchor to improve the reinsertion of the Achilles tendon in an insertional Achilles tendinitis and Haglund's deformity. We report a 54-year-old male complains of 2 years of chronic right heel pain while strength training. A focused exam of the left ankle showed a bump on the posterior heel with inflammation to the anterior and posterior Achilles tendon. A lateral X-ray and CT scan of the left ankle showed a bone spur and intratendinous calcification of the Achilles tendon with the Philip–Fowler angle at 87°. The Bohler's ankle was at 27°. After the failure of at least 6 months of conservative treatment, surgical management was indicated. It has consisted of a midline incision. Bursectomy and, resection of the posterosuperior tuberosity of the calcaneus was performed. Then, debridement of necrotic tissue and calcifications in the tendon and any posterior osteophytes were carried out. The tendon had been reinserted at its central part with single-row anchor. The lower leg was immobilized in 20° plantar flexion, this was switched to a walking boot with adjustable plantar flexion. Partial support was allowed at the 6th postoperative week. Full rehabilitation was prescribed after the removal of the cast. At 2-year follow-up, the patient is very satisfied and had no pain when standing on the toes of the operated leg. Dorsiflexion was symmetric. The effective return to full-sport activities was at 6 months at the same level.

Keywords: Achilles Tendinitis, Haglund's Deformity, Suture Anchor

1. Introduction

Haglund's deformity is an enlargement of the posterosuperior prominence of the calcaneus, which is frequently associated with insertional Achilles tendinitis [1, 2]. It's a common aetiology of hindfoot pain in adults and functional impairment. it's often bilateral and occurs in middle-aged and elderly patients, females are more concerned than males. Conservative treatment is effective usually by stretching exercises, physiotherapy, orthosis, local corticosteroid injection, and anti-inflammatory drugs [3]. Surgery is necessary only in refractory cases [4]. Many

surgical treatments for refractory Haglund deformities have been explored by open surgery or endoscopy, consisting of debridement, calcaneal osteotomy, local reinforcement with an autograft or tendon detachment and reattachment [5–9]. When > 50% of Achilles tendon insertion should be removed during careful debridement, reimplantation is necessary to use transfer tendons or sutures anchor repair [1, 10–13]. We report a 54-year-old male patient with the Insertional Achilles tendinitis and Haglund's deformity with failure of non-operative management, treated by open surgical approach and using one suture anchor to reimplant Achilles's tendon. This case aims to show the place of the suture anchor

to improve the reinsertion of the Achilles tendon Haglund's deformity and to evaluate the functional outcomes.

2. Case Report

A 54-year-old male complains of 2 years of chronic right heel pain while strength training. He's hypertensive and has been on antihypertensive drugs for 4 years. Initially, the pain was relieved with Achilles tendon stretching, orthotics, and anti-inflammatory drugs. Over the past year, these modalities are no longer helpful and he's beginning to have pain with walking and during sports activities. The patient was previously diagnosed with insertional Achilles tendinitis and has been enrolled in nonoperative management. He underwent one session of corticosteroid injection. He says that his therapy has recently increased in intensity and that he felt a bump in his Achilles tendon at the last treatment. Monopodial weight-bearing had become impossible in the last trimester.

A focused physical examination of the left ankle showed a bump on the posterior heel with inflammation to the anterior and posterior Achilles tendon (Figure 1). Pain localized to anterior and 2 cm proximal to the Achilles tendon insertion fullness and tenderness medial and lateral to the tendon, pain with dorsiflexion. There was a pain in the isometric contraction of the Achilles tendon. He's unable to plantarflex against gravity, and the Thompson compression test generates no significant plantar flexion. He's neurovascular intact. The rest of the clinical examination was unremarkable.

Ultrasound of the ankle showed an anechogenic pre-Achilles fluid collection about pre-Achilles bursitis associated with rupture of the anterior fibres of the Achilles tendon. A lateral X-ray and CT scan of the left ankle showed a bone spur and intratendinous calcifications of the Achilles tendon with the Philip–Fowler angle at 87° . The Bohler's angle was at 27° (Figure 1 and Figure 2).

After over 6 months of the failure conservative treatment, surgical management was indicated. AOFAS score preoperative was at 65.

We performed the surgery under spinal anaesthesia, with a pneumatic tourniquet at the root of the limb. The procedure was performed with the patient prone. Midline incision allows revealing a tendon Achille damage $<50\%$ in its middle insertion part. Bursectomy and, resection of the posterosuperior tuberosity of the calcaneus was performed. The size of the calcaneal exostosis was 20 mm high. Then, debridement of necrotic tissue and calcifications in the tendon and any posterior osteophytes were carried out (Figure 3). The insertion base of the Achilles tendon had been raised. Single-row anchor was placed in a calcaneus trench with the good control of fluoroscopy (Figure 4). The proximal part of the tendon was sutured with double Kessler sutures. The tendon had been reinserted at its central part. The peroperative control of the Thompson compressive test was satisfactory. The lower leg was immobilized in 20° plantar flexion. After 6 weeks, this was switched to a walking boot with adjustable plantar flexion. Partial support was

allowed at 6 weeks postoperative. Full rehabilitation was prescribed after the removal of the cast.

At 2-year follow-up, the patient was very satisfied and had no pain when standing on the toes of the operated leg. Dorsiflexion was symmetric and postoperative AOFAS score was at 86. The effective return to full-sport activities was at 6 months at the same level.

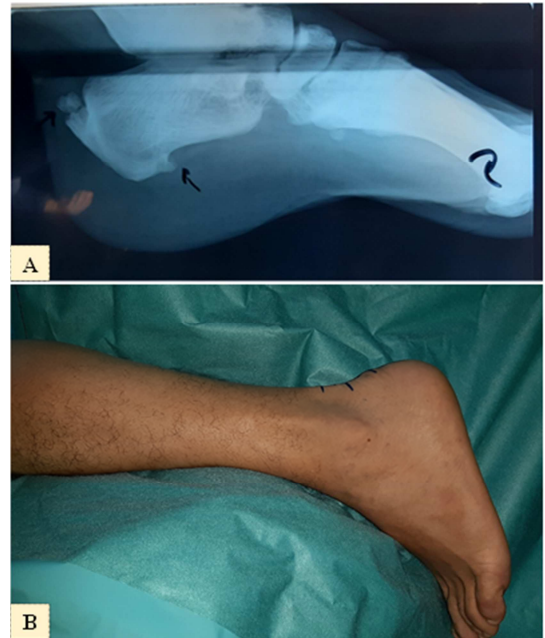


Figure 1. A. Radiographs lateral foot shows bone spur and intratendinous calcification of Achilles tendon. B. Clinical lateral view shows the bump pump in the left heel.

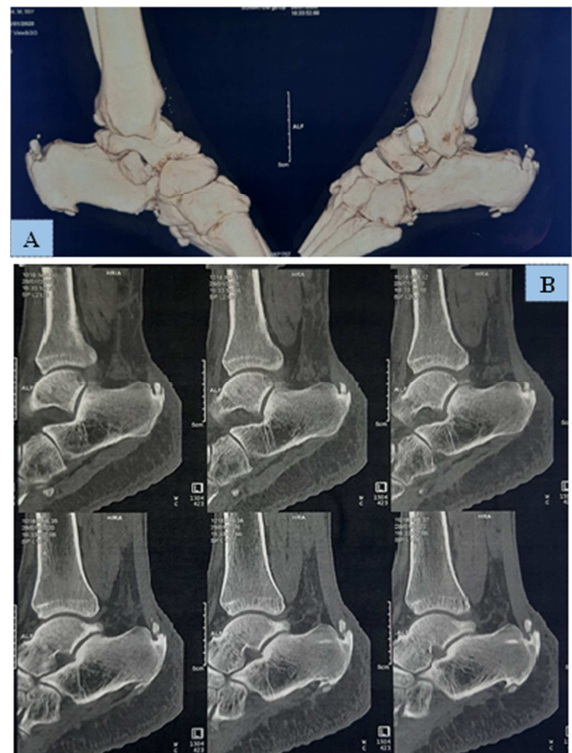


Figure 2. A and B. Sagittal view of the CT Scan foot shows bone spurs and intratendinous calcification of the Achilles tendon.

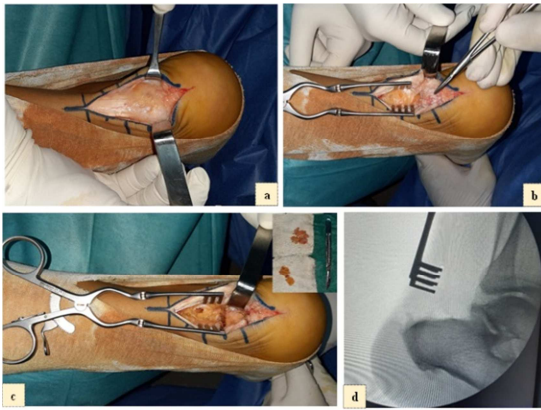


Figure 3. a. Per operative view demonstrates the Achilles tendinitis in its middle part. b. Debridement partial disinsertion of the Achilles tendon. c. Per operative view of calcaneus prominence. d. Per operative fluoroscopy view showing resected calcaneal tubercle and intracalcaneal calcification.

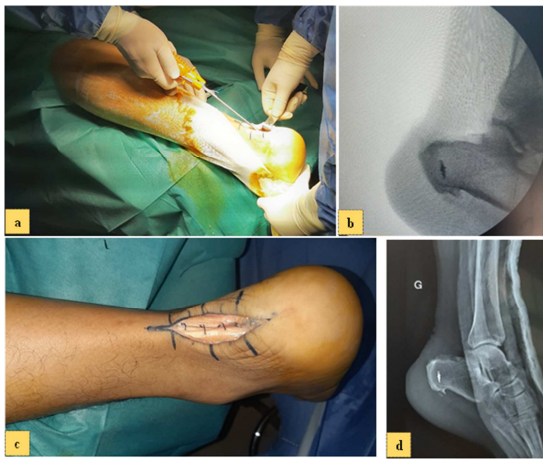

Figure 4. a. Placing the single-row anchor at the calcaneus trench. b and d. Per and postoperative images demonstrate the implantation of the anchor at the calcaneus. c. View of the final Achilles tendon suture with fibre approximation.

3. Discussion

Haglund syndrome is a chronic disorder characterised by posterior heel pain, swelling, and morning stiffness. It's pathologically defined by posterosuperior calcaneal prominence, retrocalcaneal bursitis, and insertional Achilles tendinopathy. Concern middle-aged women and is often bilateral. It's mostly an idiopathic illness, but several factors like the intense activity of sport, ill-fitting shoes and the modification of the biomechanics of the foot, have a major influence on their prevalence [2, 14].

The lateral radiograph of the ankle will show a prominent, large, posterosuperior part of the calcaneus, which can be measured applying the Fowler and Philips angle and the calcaneal pitch angle. Radiographic angle measurements have never shown a relation with Haglund's deformity [2, 15, 16]. A preoperative MRI allows to evaluation the degree of tendon involvement. Preoperative MRI is useful because it provides a better assessment of the impingement and damage to the tendon across from the tuberosity. In our case, the MRI wasn't performed before surgery, and the surgical exploration

showed >50% tendon damage at the insertion area. Thus, we need the use of single-row anchor to improve the reinsertion of the tendon [17, 18].

Treatment of insertional Achilles tendinopathy has to be treated first with non-operative approaches. The aim of non-operative treatment is to reduce inflammation of the retrocalcaneal and discharge posterior heel pain. Non-operative treatment includes reduction in activity intensities, ice bag compression, gastrocnemius stretch, footwear modification, nonsteroidal anti-inflammatory drug administration, extracorporeal shock wave therapy, and injections with a corticosteroid or platelet-rich plasma. Surgical management can be indicated after a failure of non-operative therapy after over 6 months. Different operative therapies are available for insertional Achilles tendinopathy, such as open Achilles tendon contingent or central splitting approaches for calcaneal osteotomy or retrocalcaneal bursa excision. Endoscopic approaches also constitute therapeutic approaches [8, 13, 18].

The endoscopic approach has the privilege of bearing few complications with good patient approval. However, it remains very restricted, compared to open surgery. But sometimes, including widely degenerative Achilles tendon of >50%, large ossification, bony spur and large debridement and reattachment of the Achilles tendon insertion, open surgery is often necessary for an excellent assessment and confirms a good resection of the calcaneal prominence [7, 8, 10]. It isn't rare to find a degenerative or pre-ruptured tendon at its attachment. Sometimes, well exposure imposes the detachment of the tendon from its insertion. Its reattachment at the end of the operation could then be done either by transosseous tunnels or by anchors inserted on the calcaneus trench, as in our case. Double-row suture anchors can be used to augment the tendon insertion after debridement, and partial disinsertion of the Achilles tendon to obtain wide access to the calcific deposit and to excise the deposit perfectly. Single-row bony anchor revealed to give a good outcome in this case. Reinsertion of the Achilles tendon with bone anchors is safe, appear to be effective [11, 18].

4. Conclusion

A suture bridge technique using one or double-row bone anchors is an excellent option for Achilles tendon reattachment in insertional Achilles tendonitis and Haglund's deformity. In our case, the partial removal of the Achilles tendon allows wide access to the calcific deposit and complete excision of the impingement. The reinsertion of the detached Achilles tendon was done with an anchor suture. Suture anchor increases insertion of the tendon after debridement, provides more solidity and assures an early return to sports activities.

Conflicts of Interest

The authors declare that they have no competing interests.

References

- [1] Rigby RB, Cottom JM, Vora A. Early weightbearing using Achilles suture bridge technique for insertional Achilles tendinosis: a review of 43 patients. *J Foot Ankle Surg Off Publ Am Coll Foot Ankle Surg.* oct 2013; 52 (5): 575-9.
- [2] Vaishya R, Agarwal AK, Azizi AT, Vijay V. Haglund's Syndrome: A Commonly Seen Mysterious Condition. *Cureus.* 7 oct 2016; 8 (10): e820.
- [3] Boone SL, Uzor R, Walter E, Elsinger E, Catanese D, Ye K, et al. Safety and efficacy of image-guided retrocalcaneal bursa corticosteroid injection for the treatment of retrocalcaneal bursitis. *Skeletal Radiol.* déc 2021; 50 (12): 2471-82.
- [4] Choo YJ, Park CH, Chang MC. Rearfoot disorders and conservative treatment: a narrative review. *Ann Palliat Med.* sept 2020; 9 (5): 3546-52.
- [5] Alessio-Mazzola M, Russo A, Capello AG, Lovisolo S, Repetto I, Formica M, et al. Endoscopic calcaneoplasty for the treatment of Haglund's deformity provides better clinical functional outcomes, lower complication rate, and shorter recovery time compared to open procedures: a systematic review. *Knee Surg Sports Traumatol Arthrosc Off J ESSKA.* août 2021; 29 (8): 2462-84.
- [6] Boffeli TJ, Peterson MC. The Keck and Kelly wedge calcaneal osteotomy for Haglund's deformity: a technique for reproducible results. *J Foot Ankle Surg Off Publ Am Coll Foot Ankle Surg.* juin 2012; 51 (3): 398-401.
- [7] Laumonerie P, Mattesi L, Patrick C, Tibbo ME, Ancelin D. Endoscopic resection of enthesopathy via a direct midline transtendinous approach with associated reattachment of the Achilles tendon (endo-REDMTART): a cadaveric feasibility study. *Eur J Orthop Surg Traumatol Orthop Traumatol.* 21 août 2021.
- [8] Pi Y, Hu Y, Guo Q, Jiang D, Xie X, Zhao F, et al. Open Versus Endoscopic Osteotomy of Posterosuperior Calcaneal Tuberosity for Haglund Syndrome: A Retrospective Cohort Study. *Orthop J Sports Med.* avr 2021; 9 (4): 23259671211001056.
- [9] Hunt KJ, Cohen BE, Davis WH, Anderson RB, Jones CP. Surgical Treatment of Insertional Achilles Tendinopathy With or Without Flexor Hallucis Longus Tendon Transfer: A Prospective, Randomized Study. *Foot Ankle Int.* sept 2015; 36 (9): 998-1005.
- [10] Maffulli N, Testa V, Capasso G, Sullo A. Calcific Insertional Achilles Tendinopathy: Reattachment with Bone Anchors. *Am J Sports Med.* 1 janv 2004; 32 (1): 174-82.
- [11] Warren B, Black N, Linscheid L, Panchbhavi V, Janney C. Use of Ultrasonically Interdigitated Anchors in Haglund's Deformity Correction Surgery. *Foot Ankle Spec.* avr 2021; 14 (2): 148-52.
- [12] Johnson KW, Zalavras C, Thordarson DB. Surgical management of insertional calcific achilles tendinosis with a central tendon splitting approach. *Foot Ankle Int.* avr 2006; 27 (4): 245-50.
- [13] Nunley JA, Ruskin G, Horst F. Long-term clinical outcomes following the central incision technique for insertional Achilles tendinopathy. *Foot Ankle Int.* sept 2011; 32 (9): 850-5.
- [14] Douma H, Hassani AE, Rifki F, Azriouil O, Dihi B, Madkouri HE, et al. Genetic hypothesis involving Haglund's syndrome and its association with ankylosing spondylitis: case report. *Pan Afr Med J.* 2021; 38: 49-49.
- [15] Bulstra GH, van Rheenen TA, Scholtes VAB. Can We Measure the Heel Bump? Radiographic Evaluation of Haglund's Deformity. *J Foot Ankle Surg Off Publ Am Coll Foot Ankle Surg.* juin 2015; 54 (3): 338-40.
- [16] Lee KT, Hyuk J, Kim SJ. Return to Play After Open Calcaneoplasty for Insertional Achilles Tendinopathy With Haglund Deformity in Competitive Professional Athletes. *Orthop J Sports Med.* juin 2021; 9 (6): 23259671211009820.
- [17] Szaro P, Nilsson-Helander K, Carmont M. MRI of the Achilles tendon - a comprehensive pictorial review. Part two. *Eur J Radiol Open.* 2021; 8: 100343.
- [18] Hardy A, Rousseau R, Issa S-P, Gerometta A, Pascal-Moussellard H, Granger B, et al. Functional outcomes and return to sports after surgical treatment of insertional Achilles tendinopathy: Surgical approach tailored to the degree of tendon involvement. *Orthop Traumatol Surg Res.* 1 sept 2018; 104 (5): 719-23.