

Cantrell Syndrome – A Rare Complex Congenital Anomaly: A Case Report and Literature Review

B. Ennadif^{1,*}, N. Marzouki¹, F. Alaoui Inboui¹, S. Salimi¹, B. Slaoui¹, Elkorchi², K. Chbani²

¹Pediatrics II Department, A. Harouchi Children's Hospital, IBN ROCHD University Hospital Center, Faculty of Medicine, Hassan II University Casablanca, Casablanca, Morocco

²Radiology Department, A. Harouchi Children's Hospital, IBN ROCHD University Hospital Center, Faculty of Medicine, Hassan II University Casablanca, Casablanca, Morocco

Email address:

Basma.ennadif@gmail.com (B. Ennadif)

*Corresponding author

To cite this article:

B. Ennadif, N. Marzouki, F. Alaoui Inboui, S. Salimi, B. Slaoui et al. (2024). Cantrell Syndrome – A Rare Complex Congenital Anomaly: A Case Report and Literature Review. *American Journal of Pediatrics*, 10(1), 13-17. <https://doi.org/10.11648/ajp.20241001.13>

Received: January 10, 2024; **Accepted:** January 29, 2024; **Published:** February 5, 2024

Abstract: Cantrell's pentalogy is a rare and complex white line congenital anomaly, it is first described by Cantrell et al. in 1958. It affects 5.5 children per 1,000,000 live births worldwide. The full spectrum of this syndrome includes five anomalies: an anterior diaphragm defect, a medial supraumbilical abdominal wall defect, a diaphragmatic pericardium defect, a lower sternum defect with intracardiac anomalies. The complete form that associates the five malformations of the Cantrell pentalogy is less common than the incomplete form. The embryogenesis of Cantrell's pentalogy can be caused by a problem in isolation of the frontal mesoderm around 14-18 days of gravity; The etiopathogenesis of this pattern isn't yet fully understood, numerous factors can be indicted. The prognosis depends on the complexity of the cardiac malformation. We report the case of a 3 month old infant with a complete Cantrell pentalogy and complex congenital hear disease as this is the first case that has been reported in Morocco. And we highlight through our work the importance of prenatal diagnosis for early care. This case highlights the value of gestation monitoring and antenatal comforting and perfecting the quality of complaint operation services during the first days of life.

Keywords: Congenital Heart Disease, Thoracoabdominal Wall Defect, Ectopia Cordis, Complete Form, Pentalogy of Cantrell

1. Introduction

Cantrell's pentalogy is a rare and complex white line natural anomaly, described for the first time by Cantrell et al. in 1958 [1]. It affects 5.5 children per live births worldwide. It's defined by the presence of five major blights blights of the anterior diaphragm, midline supraumbilical abdominal wall, diaphragmatic pericardium, lower sternum, and cardiac deformations [1]. The pathogenesis of this pattern isn't completely understood. The complete form that associates the five deformations of the Cantrell pentalogy is less common than the deficient form [2, 3]. The prognostic depends on the complexity of the cardiac contortion, extracardiac abnormalities and other associated abnormalities. We report the case of a 3 month old child with

a complete Cantrell pentalogy, as this is the first case that has been reported in Morocco, to emphasize the significance of prenatal opinion and to present the treatment options available for this pathology.

2. Case Presentation

A 3-month-old infant admitted to our hospital for an abnormally positioned heart and an abdominal wall abnormality. The infant had no history of consanguinity or exposure to known teratogens. However, no prenatal ultrasound was performed during pregnancy. The mother is 22 years old; The parents are in good health with no particular pathological history, notably no congenital malformations in the family. The examination on admission found an infant cyanotic, without pallor, eutrophic, his

weight was 6 kg normal for his age. He had an obvious lower chest wall abnormality, the heart is visible at the epigastrium with a large omphalocele measuring 10×6 cm, extending to the epigastrium, covered by a thin membrane. No other congenital malformations were detected. (Figure 1)

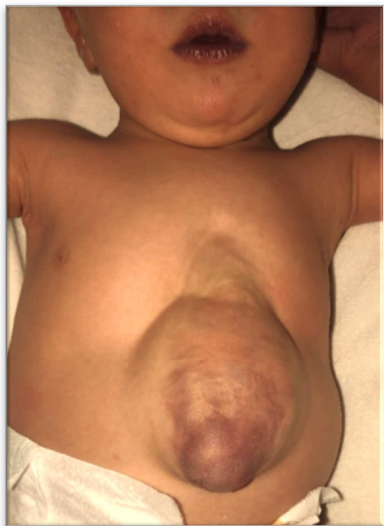

Figure 1. A thoraco-abdominal large defect measuring 10×6 cm.

He was polypneic at 40 cycles per minute and saturated at 78% on room air. He was tachycardic at 132 beats per minute, the peak shock was palpable at the apex. There was a diffuse systolic murmur heard at the level of the epigastrium, the other devices were without abnormalities. Her chest radiograph showed a normal manubrium-sternum and lungs, with a displaced cardiac shadow (Figure 2).

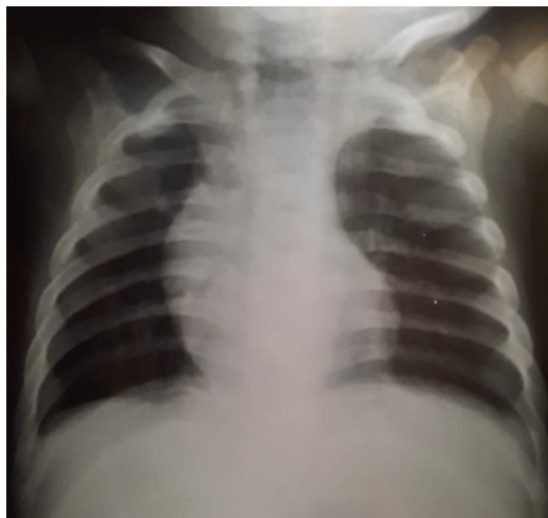

Figure 2. Chest x-ray showing a normal cardiac silhouette; cardio-thoracic index at 0.48.

The thoraco-abdominal CT-angiography showed an externalization of the heart through a 35mm sternal slit, and a single left ventricle. A hepatomegaly with a hepatic arrow at 9 cm with regular contour, a supraumbilical hernia of segments II and III of the liver through a 60 mm defect, a

defect of the anterior part of the diaphragm (Figures 3- 4).

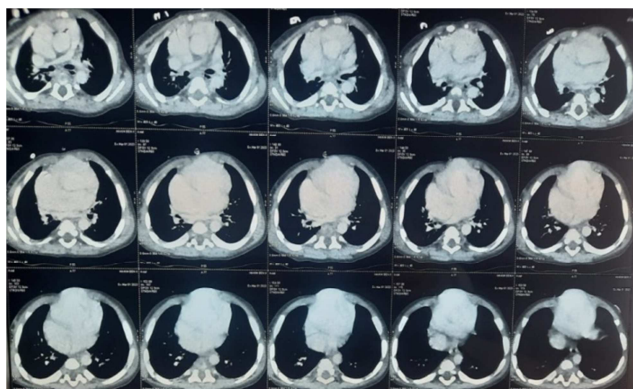


Figure 3. Thoraco-abdominal CT-angiography, showing the externalization of the heart.

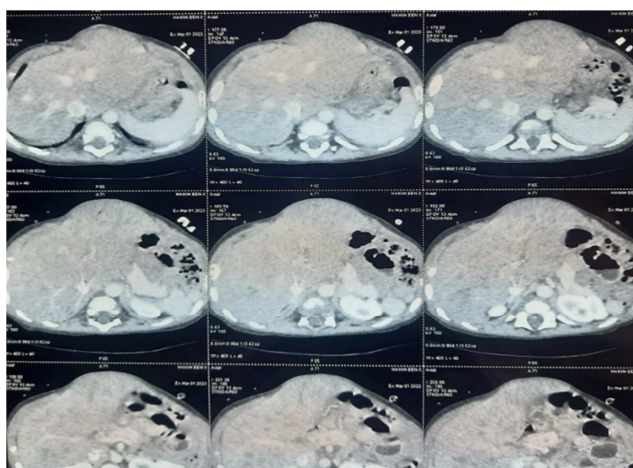


Figure 4. Thoracoabdominal CT-angiography, showing the supraumbilical hernia of segments II and III of the liver.

We also performed Cardiac ultrasound, which showed complex cardiac malformations consisting single ventricle type left ventricle with good function, virtual right ventricle, Tricuspid atresia, Medio-septal muscular intraventricular communication of 4 mm restrictive, 10 mm wide atrial septal defect with rightleft shunt, Hypoplasia of the pulmonary artery and its bronchi, and thrombosed ductus arteriosus. by grouping together the anomalies found in the clinical and radiological examinations, we retain the diagnosis of the complete form of the pentalogy of cantrell class 4 of the tayoma classification [4]. We treated our patient with furosemide 1 mg/kg/12 h to control the heart failure, while waiting for reconstructive surgery.

3. Discussion

Pentalogy of Cantrell was first described by Cantrell, et al. in 1958, the full diapason consists of five anomalies a insufficiency of the anterior diaphragm, a midline supraumbilical abdominal wall disfigurement, a disfigurement in the diaphragmatic pericardium, colorful natural intracardiac abnormalities, and a disfigurement of the lower sternum. Only a many cases with the full diapason of

the pentalogy have been described. [1].

The embryogenesis of Cantrell's pentalogy can be caused by a problem in isolation of the frontal mesoderm around 14-18 days of gravidity, and an anomaly in the migration of some structures to their applicable locales. The incapability to develop a member of the mesoderm results in cardiac, diaphragmatic, pericardial deformations and deformations of the sternal and abdominal wall [5].

The etiopathogenesis of this pattern isn't yet fully understood, numerous factors can be indicted, including inheritable mutations, chromosomal abnormalities and physical and chemical teratogens [6].

Two pathophysiological suppositions have been described the first in mutations in the BMP2 gene (bone morphogenetic protein 2) may be responsible for this pentalogy, because these genes are responsible for the normal development of medium structures [7, 8]. The alternate suppositions is mutation of the ALDH1A2 gene the ALDH1A2 gene canons for the enzyme retinaldehyde dehydrogenase type 2, essential for the conversion of vitamin A into trans- retinoicacid., which is veritably important for organogenesis, it plays an essential part in pleuroperitoneal folding during diaphragm

embryogenesis [7, 9].

Grounded on a study by Tayoma involving 60 cases, the pentalogy is classified as complete or deficient depending on the number of deformations present [10].

1. Complete form Class 1 All five deformations are present
2. Deficient forms Class 2 All four deformations are present, including intracardiac deformations and frontal abdominal wall deformations. Class 3 An deficient form which always includes a sternal disfigurement

A recent review grouping together cases of Cantrell pentalogy reported between 1998 and 2007 showed that the full form of Cantrell pentalogy is the most common, counting for further than half of the cases. and 67 of cases presented intracardiac abnormalities [11]. natural intracardiac anomalies are harmonious features of this pattern, and Cantrell et al. reported ventricular septal disfigurement in nearly all cases and atrial septal disfigurement in roughly half of the cases, as in the case of our case [12].

Piecemeal from the five anomalies of Cantrell's pentalogy, other deformations have been described in several studies reporting literal cases of this pentalogy over time [13]. Table 1.

Table 1. Patients with complete and incomplete Cantrell pentalogy presenting different malformations [11].

Reference	Form	Cardiac Malformations	Associated malformations
Chen et al. 2006 [14]	complete	1) Cardiac ectopia 2) ventricular septal defect	1) Scoliosis, 2) hypoplasia of the right upper limb 3) Ectrodactyly of the right hand and foot
Correa-Rivas et al. 2004 [15]	complete	1) Cardiac ectopia, 2) Atrial septal defect 3) Atrial communication Persistent	1) Cleft lip and palate 2) Bilateral pulmonary hypoplasia
Aslan et al. 2004 [16]	Incomplete	Cardiac ectopia	1) Renal agenesis 2) adreno-hepatic fusion 3) scoliosis
Uygur et al. 2004 [17]	Incomplete	Cardiac ectopia	1) Left club foot, 2) absence of the third finger of the right hand, 3) absence of the left tibia and the right radius
Bittmann et al. 2004 [18]	complete	1) Cardiac ectopy, 2) Ventricular septal defect, 3) Atrial communication	1) Bladder agenesis, 2) polysplenia, 3) lung segmentation defect
Our study	Complete form	1) Cardiac ectopy, 2) Ventricular septal defect 3) Atrial communication Persistent 4) Atrioventricular Canal, 5) Pulmonary hypoplasia	No other malformations

The optimal remedial operation of these cases requires the collaboration of a multidisciplinary platoon, gynecobstetricians, neonatologists, pediatricians, pediatric surgeons, cardiovascular surgeons and intensivists. The surgical intervention for Cantrell's pentalogy substantially comprises four stages soft towel content of the heart, relief of the heart in the casket depression, form of intracardiac blights, and reconstruction of the casket wall [19]. The survival rate after surgical form is only 37 [20]. The main causes of death are tachyarrhythmias, bradycardia, hypotension, diverticulum rupture, and heart failure [20].

A meta- analysis of 23 cases of Cantrell pentalogy published in colorful English journals set up a median survival age of 10 months (between 4 days and 5 times) [21-

25]. With advances in medical knowledge and technology, cases with complex intracardiac deformations can survive longer, beyond 6 times, with normal growth and development [26].

The prognostic of Cantrell's pentalogy depends substantially on the type and complexity of the associated cardiac deformations, and also on the position of the ectopic heart. As in the case of our case, complete Cantrell pattern is associated with a poorer prognostic and advanced mortality than probable and deficient runs without cardiac deformations [10-27].

Antenatal opinion can be performed by good and educated obstetric sonographers as early as 10 weeks of gravidity using traditional two- dimensional (2D) ultrasound; at this stage,

omphalocele and ectopia cordis are common findings [28, 29]. Although 3D ultrasound may be necessary for the opinion of some fetal anomalies, the opinion of Cantrell's pentalogy can be performed satisfactorily with traditional 2D ultrasound [30-32].

Obstetric ultrasound is essential in gestation monitoring in Morocco. still, in our case, the antenatal ultrasound wasn't performed at any time during the gestation and thus we missed the occasion to profit from antenatal comforting and early referral of this child.

4. Conclusion

Cantrell's pentalogy is a fairly rare and complex pattern that causes multitudinous fetal anomalies that can be fatal. We thus emphasize then the significance of antenatal opinion by ultrasound of the 1st trimester, which allows early opinion of the pattern, in order to be suitable to advise and take care of the case meetly and minimize the cerebral trauma she undergoes. Cantrell's pentalogy presents a individual and remedial problem, taking treatment in the neonatal period; This case highlights the value of gestation monitoring and antenatal comforting and perfecting the quality of complaint operation services during the first days of life.

Abbreviations

CT-angiography: Computed Tomography Angiography

BMP 2: Bone Morphogenetic Protein

ALDH1A2: Aldehyde Dehydrogenase 1 Family Member A2

2D: 2dimentions

3D: 3dimentions

Conflicts of Interest

The authors declare no conflicts of interest.

References

- [1] JR Cantrell, JA Haller, MM Ravitch: A syndrome of congenital defects involving the abdominal wall, sternum, diaphragm, pericardium and heart. *Surg Gynecol Obstet.* 1958, 107: 602-614.
- [2] S. Marcella, P. Damiano, AC Colangelo. Conservative management of Cantrell syndrome: a case report. *J Surg Case Rep.* 2020, 100: 10.1093/jscr/rjaa100.
- [3] AM Korver, F Haas, MW Freund, J Strengers: Pentalogy of Cantrell: successful early correction. *Pediatr Cardiol.* 2008, 29: 146-149. 10.1007/s00246-007-9032.
- [4] RI Kylat: Complete and Incomplete Pentalogy of Cantrell Children. 2019, 6: 109. 10.3390.
- [5] A Vůlkova, K Kovacheva, R Rosmanova: Pentalogy of Cantrell--a case report. *Akush Ginekol (Sofia).* 2007, 46: 41-3.
- [6] T Mendaluk, A Mościcka: The incomplete pentalogy of Cantrell - A case report. *Pediatrics Polska.* 2015, 90: 241-44.
- [7] AR Patil, LS Praveen: V A mbica. Pentalogy of cantrell: A case report. *BJR Case Rep.* 2015201520140002, 10.1259/bjrcr.20140002.
- [8] AP Singh, T Castranio, G Scott, et al.: Influences of reduced expression of maternal bone morphogenetic protein 2 on mouse embryonic development. *Sex Dev.* 2008, 2: 134-41. 10.1159/000143431.
- [9] Steiner MB, Vengoechea J, Collins RT: II Duplication of the ALDH1A2 gene in association with pentalogy of Cantrell: A case report. *J Med Case Rep.* 2013, 7: 287.
- [10] N Singh, ML Bera: Pentalogy of Cantrell with left ventricular diverticulum: a case report and review of literature. *Congenit Heart Dis.* 2010, 5: 454-7. 10.1111/j.1747-0803.2009.00375.x.
- [11] JH Van Hoorn, RM Moonen: two patients and a review to determine prognostic factors for optimal approach. *Eur J Pediatr.* 2008, 167: 29-35. 10.1007/s00431-007-0578-9.
- [12] Naburi, E Assenga, S Patel et Al: Class II pentalogy of Cantrell. 2015, 8: 318. 10.1186/s13104-015-1293-7.
- [13] Ranganath P, Pradhan M: Complete pentalogy of Cantrell with craniorachischisis: A case report. *J Prenat Med.* 2012, 6: 10-12.
- [14] Chen CP: Prenatal diagnosis of pentalogy of Cantrell associated with hypoplasia of the right upper limb and ectrodactyly.. *Prenat Diagn.* 2006, 27: 86-87. 10.1002/pd.1610.
- [15] Correa-Rivas MS: Pentalogy of Cantrell: a case report with pathologic findings. *Pediatr Dev Pathol.* 2004, 7: 649-652. 10.1007/s10024-004-9104-5.
- [16] Aslan A, Karaguzel G, Unal I, Aksoy N, Melikoglu M: Two rare cases of the pentalogy of Cantrell or its variants.. *Acta Med Austriaca.* 2004, 31: 85-87.
- [17] Uygur D: An infant with pentalogy of Cantrell and limb defects diagnosed prenatally.. *Clin Dysmorphol.* 2004, 13: 57-58. 10.1097/00019605-200401000-00018.
- [18] Bittmann S: Combined pentalogy of Cantrell with tetralogy of Fallot, gallbladder agenesis, and polysplenia: a case report. *J Pediatr Surg.* 2004, 39: 107-109. 10.1007/s00431-007-0578-9.
- [19] N Alphonso, PS Venugopal: Complete thoracic ectopia cordis. *Eur J Cardio-Thorac Surg.* 2003, 23: 426-8. 10.1016/s1010-7940(02)00811-4.
- [20] Adele P. Williams, M. D: Pentalogy of Cantrell *Semin Pediatr Surg.* 2019, 28: 106-110. 10.1053.
- [21] R Smigiel, A Jakubiak, MP Lombardi: Co-occurrence of severe Goltz-Gorlin syndrome and pentalogy of Cantrell: Case report and review of the literature. *Am J Med Genet.* 2011, 155: 1102-1105. 10.1002.
- [22] Y Ootaki, J Strainic, RM Ungerleider: Pentalogy of Cantrell with double-outlet right ventricle: a case of surgical correction. *Cardiol Young.* 2011, 21: 235-237. 10.1017/S1047951110001770.
- [23] Y Sakasai, BQ Thang: Staged repair of pentalogy of Cantrell with ectopia cordis and ventricular septal defect. *J Card Surg.* 2012, 27: 390-392. 10.1111/j.1540-8191.2012.01456.x.
- [24] Gao Z: Duan QJ et al. Prognosis of pentalogy of Cantrell depends mainly on the severity of the intracardiac anomalies and associated malformations. *Eur J Pediatr.* 2009, 168: 1413-1414. 10.1007/s00431-008-0905-9.

- [25] JY Wan, SH Zhao, SL Jiang: Pentalogy of Cantrell associated with a double-outlet right ventricle. *Chin Med J.* 2012, 125: 3359-3360. 10.3760.
- [26] M Dixit, M Gan, R Mohapatra: Pentalogy of Cantrell: a case report. *J Indian Med Assoc.* 2009, 107: 647-648.
- [27] KK Mallula, C Sosnowski, S Awad: Spectrum of Cantrell's pentalogy: case series from a single tertiary care center and review of the literature. *Pediatr Cardiol.* 2013, 34: 1703-10. 10.1007.
- [28] K Suehiro, R Okutani: Perioperative management of a neonate with Cantrell syndrome. *J Anesth.* 2009, 23: 572-575. 10.1007/s00540-009-0785-9.
- [29] W Sepulveda, AE Wong: Ectopia cordis in a first-trimester sonographic screening program for aneuploidy. *J Ultrasound Med Off J Am Inst Ultrasound Med.* 2013, 32: 865-871. 10.7863/ultra.32.5.865.
- [30] I Gun, M Kurdoglu: Prenatal diagnosis of vertebral deformities associated with pentalogy of Cantrell: the role of three-dimensional sonography?. *J Clin Ultrasound JCU.* 2010, 38: 446-449. 10.1002/jcu.20726.
- [31] EB Rodgers, A Monteagudo: Diagnosis of pentalogy of Cantrell using 2- and 3-dimensional sonography. *J Ultrasound Med Off J Am Inst Ultrasound Med.* 2010, 29: 1825-1828. 10.7863/jum.2010.29.12.1825.
- [32] A Rossi, L Forzano: Incomplete pentalogy of Cantrell during first trimester of pregnancy. *Minerva Ginecol.* 2011, 63: 399-400.