

**Case Report**

# Pyloric Duplication in Ten Years Old Girl: A Case Report

Ni Made Reditya Noviyani<sup>1</sup>, Ni Nyoman Metriani Nesa<sup>1,\*</sup>, I Gusti Ngurah Sanjaya Putra<sup>1</sup>,  
I Putu Gede Karya<sup>1</sup>, Kadek Deddy Ariyanta<sup>2</sup>, I Made Darmajaya<sup>2</sup>, Pande Putu Yuli Anandasari<sup>3</sup>,  
Ni Wayan Winarti<sup>4</sup>

<sup>1</sup>Department of Child Health, Faculty of Medicine, Udayana University/Sanglah Hospital, Denpasar, Indonesia

<sup>2</sup>Department of Surgery, Faculty of Medicine, Udayana University/Sanglah Hospital, Denpasar, Indonesia

<sup>3</sup>Department of Radiology, Faculty of Medicine, Udayana University/Sanglah Hospital, Denpasar, Indonesia

<sup>4</sup>Department of Anatomical Pathology, Faculty of Medicine, Udayana University/Sanglah Hospital, Denpasar, Indonesia

**Email address:**

tyanoviyani13@gmail.com (Ni M. R. Noviyani), metriani\_nesa@yahoo.co.id (Ni N. M. Nesa)

\*Corresponding author

**To cite this article:**

Ni Made Reditya Noviyani, Ni Nyoman Metriani Nesa, I Gusti Ngurah Sanjaya Putra, I Putu Gede Karya, Kadek Deddy Ariyanta, I Made Darmajaya, Pande Putu Yuli Anandasari, Ni Wayan Winarti. Pyloric Duplication in Ten Years Old Girl: A Case Report. *American Journal of Pediatrics*. Vol. 6, No. 4, 2020, pp. 455-458. doi: 10.11648/j.ajp.20200604.21

**Received:** October 10, 2020; **Accepted:** October 26, 2020; **Published:** November 9, 2020

---

**Abstract:** Gastrointestinal duplication cysts are rare congenital anomalies. Pyloric duplication represents 2.2% of all gastrointestinal tract duplications. The presentations merely depend on the site of occurrence, size and type of the cyst, and presence of ectopic mucosal lining. A ten years old girl vomited for two months, accompanied with stomach ache and difficulty in defecation. The color of stool sometimes was black. The body weight decreased twelve kilograms in two months. On physical examination, no abdominal distention and no palpable mass was found, bowel sound was decreased and there was tenderness in epigastric area. Nutritional status of patient was severe malnutrition. Laboratory test revealed mild hypochromic microcytic anemia, severe hyponatremia, severe hypokalemia, and hypoalbuminemia. Abdominal ultrasound revealed thickening of the gastric wall and upper gastrointestinal contrast study revealed partial stenosis with thickening of pyloric wall. Esophagogastroduodenoscopy revealed multiple gastric ulcers and gastric outlet obstruction. Cyst duplication and stricture in the pylorus were found during surgical procedure. The pediatric surgeon performed an excision of duplication cyst and gastroduodenostomy side to side anastomosis. Histopathologic examination from cyst confirmed the enteric duplication cyst. The patient was discharged in good condition. We concluded that pyloric duplication is considered as one of the differential diagnosis in children with symptoms of gastric outlet obstruction. Appropriate surgical procedures should be undertaken to avoid complications.

**Keywords:** Pediatric, Gastrointestinal Duplication Cyst, Pylorus

---

## 1. Introduction

Gastrointestinal tract (GIT) duplication are rare congenital anomalies. The reported incidence is 1:4.500 births, about 60-70% detected in antenatally or within first two years of life. Gastrointestinal tract duplications are ectopic cystic or tubular structures composed of smooth muscle surrounding the mucosa of the gastrointestinal tract and occur most commonly along the ileum, followed by mediastinal, colon, gastric, duodenal, rectal, esophageal, and cervical lesions [1,

2]. Gastric duplications are relatively rare in children. Pyloric duplication represents 2.2% of all gastrointestinal tract duplications. The female-to-male ratio is 2:1. No familial or racial association has been reported [1, 3].

Gastric duplication present with a variety of symptoms or sometimes is encountered during an operation for other problems. The presentations of gastric duplication merely depend on the site of occurrence, size and type of the cyst, and presence of ectopic mucosal lining. The clinical manifestations include gastric outlet obstruction,

gastrointestinal bleeding, and an ulcerated antral mass [4-6].

Gastric duplication is diagnosed by ultrasonography, contrast computed tomography (CT) scan/magnetic resonance imaging (MRI), endoscopy, and scintigraphy that can be used effectively to detect cysts with gastric mucosa [7, 8]. Diagnostic laparoscopy is widely used at present because the preoperative diagnosis duplication of cyst is often inaccurate. Histopathological examination can confirm the diagnosis of gastric duplication. Resection is the treatment of choice with an excellent outcome [9, 10].

We reported a case of pyloric duplication who presented in late childhood with a previously healthy background. The objective of this case report is to describe clinical and examination aspects of pyloric duplication.

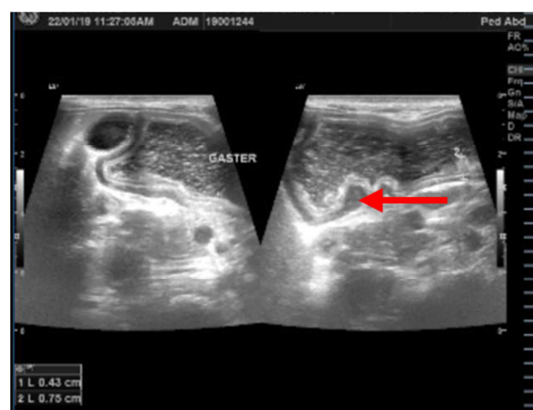## 2. Case Illustration

A ten years old girl came to the emergency room Sanglah Hospital. The patient was referred from S hospital with severe persistent vomiting due to suspect ulcer disease with severe malnutrition and electrolyte imbalance. The patient vomited for two months before admitted in Sanglah Hospital. She had non-bilious vomiting after meal approximately ten times a day with volume two spoons every vomiting. The vomit consisted of meal which she consumed. There was no history of bloody vomiting. This complaint was accompanied with a stomach ache and defecation difficulty. The stomach ache was like heartburn. Sometimes the color of stool was black. The body weight decreased twelve kilograms in two months. There were no fever, headache nor seizure. Patient was the second child in the family, no history of congenital anomalies in her family. There was no consanguineous in her parents. No history of illness nor consuming any medicine during pregnancy period was noted. There was no abnormality during pregnancy or delivery. The patient had normal growth and development before she was sick.

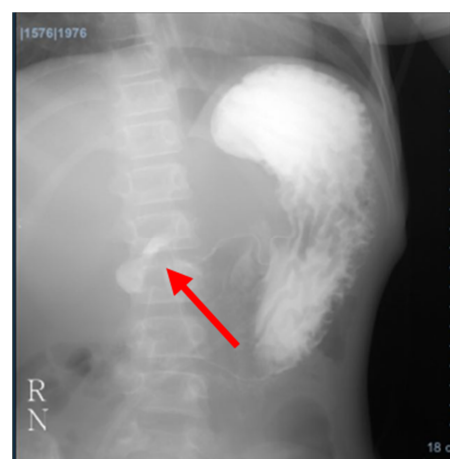
The patient was fully alert when admitted in Sanglah Hospital. The head was normal in shape. There were no sunken eyes, jaundice on the sclera, neither conjunctiva injection. The pupil light reflex was normal and size were equal. The ears, nose, and throat examination were in normal limit. There were no lymph nodes enlargement in the neck or superior clavicle. The chest was symmetrical both on rest and movement. Breath sound was vesicular without rales or wheezing. The first and second heart sound were normal, regular and no murmur in auscultation. There were no lymph nodes enlargement in both of the axilla. Abdomen was no distended. Bowel sound was decreased when auscultated. There was tenderness in epigastric area, but no palpable mass. Liver and spleen were no palpable. Skin turgor was normal. There was no edema in extremities or lymph node enlargement in both of the inguinal. Anal and genital examination were normal. Anthropometric status of patient was 67.8% (severe malnutrition) based on Waterlow classification.

Laboratory test revealed mild hypochromic microcytic anemia (8.67 g/dL), severe hyponatremia (120 mmol/L),

severe hypokalemia (1.83 mmol/L), and hypoalbuminemia (2.6 g/dL). Urine electrolytes and kidney function test were normal. The fecal occult blood test was positive. Abdominal ultrasound revealed thickening of the gastric wall and upper gastrointestinal contrast study revealed partial pyloric stenosis (7-8 millimeters) with thickening of pyloric wall, suspect stenosis due to fibrosis (figure 1). Esophagogastroduodenoscopy (EGD) revealed multiple gastric ulcers (Forrest III) and gastric outlet obstruction (figure 2).

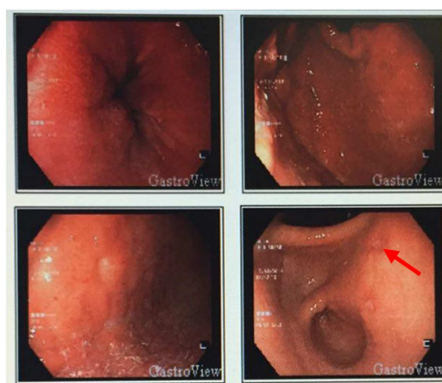


(a)



(b)

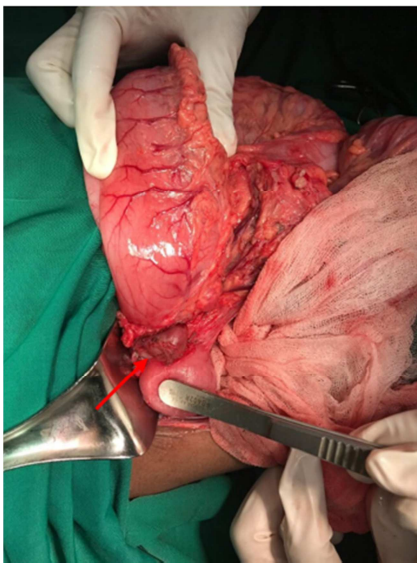
**Figure 1.** Abdominal ultrasound: thickening of the gastric wall (a), upper gastrointestinal contrast study: partial pyloric stenosis (b).



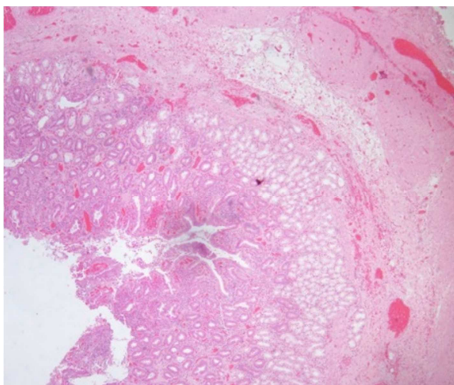
**Figure 2.** Esophagogastroduodenoscopy: gastric ulcer.

Based on clinical and adjunctive examination, the patient was diagnosed with multiple gastric ulcers, gastric outlet obstruction due to suspect pyloric stenosis, severe malnutrition, and electrolyte imbalance (severe hyponatremia, severe hypokalemia). The patient had been given electrolyte correction, proton pump inhibitor intravenously, temporary fasting with parenteral nutrition, and consulted to Pediatric Surgeon. The patient was planned to have exploration laparotomy.

During the surgical procedure, the surgeon found cyst duplication and stricture in the pylorus (figure 3), then they performed an excision of duplication cyst and gastroduodenostomy side to side anastomosis. Histopathologic examination from the cyst was consistent with enteric duplication cyst (figure 4).



**Figure 3.** Duplication cyst in pylorus.



**Figure 4.** Histopathologic feature of pyloric duplication (Hematoxyllin-Eosin slide, 10x objective magnification).

Patient was admitted to the Pediatric Intensive Care Unit (PICU) after surgery. She was given intravenous antibiotic and proton pump inhibitor. She was fasting and given total parenteral nutrition for three days. Three days after surgery, tropic feeding from the feeding tube was given. The patient could move to a regular ward and she was full fed on the eleventh day of surgery. Three days after full fed, the patient

was discharged in good condition and being followed up regularly in out-patient clinic until the case was reported. There were no complications after surgery.

### 3. Discussion

Gastric duplication is uncommon amongst GIT duplication anomalies. Several theories have been proposed to explain its development. These include the persistence of embryonic diverticulum during alimentary development, abortive attempts at twinning, intrauterine vascular accidents, and recanalization with a fusion of embryological longitudinal folds [11, 12]. The patient was ten years old girl who had duplication in the pylorus without a history of congenital anomalies in her family. Mother of the patient had no history of illness nor consuming any medicine during pregnancy period. There was no abnormality during pregnancy or delivery.

The presentations of gastric duplication merely depend on the site of occurrence, size and type of the cyst, and presence of ectopic mucosal lining [6]. Some duplication may be totally asymptomatic, identified on routine physical examination or during investigations for other problems. Common clinical manifestations of pyloric duplication include a palpable abdominal mass and non-bilious vomiting, which is almost present in all cases of literature. Most pyloric duplication cyst has no communication with the adjacent bowel tract [11-13]. Patient experienced non-bilious vomiting as the symptom of gastric outlet obstruction. She had electrolyte imbalance and decreased of body weight due to recurrent vomiting. However, no palpable abdominal mass was found on physical examination. Cyst duplication was found in pylorus during surgical procedure. There was no communication of pyloric duplication with the adjacent bowel tract.

Gastric duplication is associated with different types of ulcers. These could be gastric, duodenal, or colonic. Gastric ulcers could affect the mucosa of the stomach or the gastric lining of the cyst [4, 6]. Normally, acid in the gastric lumen acts directly on the somatostatin cells to stimulate the release of somatostatin, thereby preventing gastrin release from gastrin cells by a paracrine mechanism. When the gastric antral mucosa is isolated from its usual acidic environment, there is no hydrogen ion feedback inhibition of gastrin release, leading to hypergastrinemia followed by increased gastric acid production, recurrent ulceration, and bleeding [8]. The patient had history of black stool. It was the symptom of upper gastrointestinal tract bleeding. We did EGD and the result showed multiple gastric ulcers (Forrest III) and gastric outlet obstruction.

The diagnosis of gastric duplication is difficult because of its rarity. Gastric duplication is diagnosed by ultrasonography, which usually shows a bowel wall signature. Other diagnostic modalities include contrast computed tomography (CT) scan/magnetic resonance imaging (MRI), endoscopy, and scintigraphy that can be used effectively to detect cysts with gastric mucosa. Endoscopic studies are not usually used to diagnose gastric duplication. However, the delay in obtaining the CT scan contributed to the endoscopic diagnosis with

documented progression of a complicated gastric duplication [7, 8]. Diagnostic modalities facilitate the differential diagnosis of gastric duplication, but the disease is most commonly diagnosed during surgery [14]. We performed abdominal ultrasound and the result was thickening of gastric wall. The upper gastrointestinal contrast study showed partial pyloric stenosis with thickening of pyloric wall. Based on these examinations, we found gastric outlet obstruction, but no cyst was detected. Pediatric surgeon found pyloric duplication when they performed an exploratory laparotomy.

Histopathologic examination of the resected segment allows confirmation of the diagnosis. Ladd introduced the term “duplication of the alimentary tract” and set the diagnostic criteria for GIT duplications. The criteria included the presence of a well-developed smooth muscle layer, the presence of an epithelial alimentary tract lining, and an attachment to part of the alimentary tract [15]. Duplications are named according to the location and are generally cystic or tubular masses, in 10-15% cases the cysts are multiple [1, 10]. We did histopathologic examination from excised cyst duplication in pylorus and the morphology result was consistent with enteric duplication cyst.

The excision should be considered in all duplication cases wherever possible. The surgical approach varies with location and type of the cysts. Resection and anastomosis may be required. Important points to be considered in surgical of gastrointestinal duplication cysts include the nature of the blood supply shared between the duplication and native bowel, the presence of heterotopic gastric mucosa which will negate internal drainage due to the risk of peptic ulcerations, and the relationship with adjacent structure. The long-term prognosis of enteric duplication cyst is excellent after surgical treatment [16, 17]. The patient had exploratory laparotomy and pediatric surgeon performed an excision of duplication cyst and gastroduodenostomy side to side anastomosis due to stricture in the pylorus. There were no complications after surgery. The patient was discharged in good condition.

## 4. Conclusion

We should consider pyloric duplication as one of the differential diagnosis in children with symptoms of gastric outlet obstruction. The preoperative diagnosis of duplication cyst is often inaccurate. The cyst can be encountered during an operation for other problems. Appropriate surgical procedures should be undertaken to avoid complications.

## Conflict of Interest

All the authors do not have any possible conflicts of interest.

## Acknowledgements

The first author would like to thank Supervisors for direction and proper guidance in this case report.

## References

- [1] Sharma S, Yadav AK, Mandal AK, Zaheer S, Yadav DK, Samie A. Enteric duplication cysts in children: a clinicopathological dilemma. *JCDR*. 2015; 9: 8-11.
- [2] Cavar S, Bogovic M, Leutic T, Antabak A, Batinica S. Intestinal duplications - experience in 6 cases. *Eur Surg Res*. 2006; 38: 329-32.
- [3] Murty TV, Bhargava RK, Rakas FS. Gastroduodenal duplications. *J Pediatr Surg*. 1992; 27: 515-7.
- [4] Tanaka H, Masumoto K, Sasaki T, Sakamoto N, Gotoh C, Urita Y, et al. Hypergastrinemia and a duodenal ulcer caused by gastric duplication. *Surg Case Rep*. 2016; 2: 75.
- [5] Cunningham S, Hansel D, Fishman E, Cameron J. Foregut duplication cyst of the stomach. *J Gastrointest Surg*. 2006; 10: 620-1.
- [6] Olajide ARL, Yisau AA, Abdulraseed NA, Kashim IOO, Olaniyi AJ, Morohunfado AOA. Gastrointestinal duplications: experience in seven children and a review of the literature. *Saudi J Gastroenterol*. 2010; 16 (2): 105-9.
- [7] Srikanth KP, Thapa BR, Lal SB, Menon P, Sodhi K, Vaiphei K, et al. Noncommunicating gastric antral duplication cyst presenting with hematemesis due to large antral ulcer. *Trop Gastroenterol*. 2015; 36: 134-6.
- [8] Surridge CA, Goodier MD. Gastric duplication cyst: a cause of rectal bleeding in a young child. *Afr J Paediatr Surg*. 2014; 11: 267-8.
- [9] Liu R, Adler DG. Duplication cysts: diagnosis, management, and role of endoscopic ultrasound. *Eusjournal*. 2014; 3: 152-8.
- [10] Mayer JP, Bettoli M. Alimentary tract duplications in newborns and children: diagnostic aspects and the role of laparoscopic treatment. *World J Gastroenterol*. 2014; 20: 14263-71.
- [11] Marginean CO, Marginean C, Horvath E, Gozar L, Gozar HG. Antenatally diagnosed congenital pyloric duplication associated with intraluminal pyloric cyst - rare entity case report and review of the literature. *Rom J Morphol Embryol*. 2014; 55 (3): 983-8.
- [12] Saad DF, Gow KW, Shehata B, Wulkan ML. Pyloric duplication in a term newborn. *J Pediatr Surg*. 2005; 40 (7): 1209-10.
- [13] Shah A, More B, Buick R. Pyloric duplication in a neonate: a rare entity. *Pediatr Surg Int*. 2005; 21 (3): 220-2.
- [14] Ahmed YB, Ghorbel S, Charieg A, Nouira F, Khemekhem R, Jilidi S, et al. Pyloric duplication: about two cases. *Pediatr Neonatal Care J*. 2015; 2 (2): 00065.
- [15] Ladd WE. Duplications of the alimentary tract. *South Med J*. 1937; 30: 363-71.
- [16] Rasool N, Safdar CA, Ahmad A, Kanwal S. Enteric duplication in children: clinical presentation and outcome. *Singapore Med J*. 2013; 54: 343-6.
- [17] Jehangir S, Ninan PJ, Jacob TJ, Eapen A, Mathai J, Thomas RJ, et al. Enteric duplication in children: experience from a tertiary center in South India. *J Indian Assoc Pediatr Surg*. 2015; 20: 174-8.