

Meningitis induced by *Streptococcus pneumoniae* elicits cellular damage but not DNA damage during the acute phase of infection in the hippocampus of Wistar rats

Daphne Santhosh*, Indira Bairy

Department of Microbiology, Melaka Manipal Medical College, Manipal University, Manipal, Karnataka, India

Email address:

daphnevincent@yahoo.com (D. Santhosh), ibairy@yahoo.com (I. Bairy)

To cite this article:

Daphne Santhosh, Indira Bairy. Meningitis Induced by *Streptococcus Pneumoniae* Elicits Cellular Damage but not DNA Damage during the Acute Phase of Infection in the Hippocampus of Wistar Rats. *American Journal of Health Research*. Vol. 2, No. 1, 2014, pp. 15-19. doi: 10.11648/j.ajhr.20140201.13

Abstract: Pneumococcal meningitis is associated with high mortality and morbidity. Great majority of survivors are affected by neurological sequelae due to a wide spectrum of brain injury mainly affecting the cortex and hippocampus. Published data suggest histomorphological observations of these sequelae indicating a pattern of brain damage characterized by necrotic tissue damage in the cerebral cortex and apoptosis of neurons in the hippocampal dentate gyrus. Aim of the present study was to investigate and correlate data for any DNA damage due to the effect of pneumococcal meningitis on the hippocampus in Wistar rats, during the acute phase of the infection. Thirty days old rats were divided into normal control (NC) and meningitis (M) groups. Rats in the meningitis group were infected with *Streptococcus pneumoniae*, intracisternally on postnatal day 31. The concentration of the bacterial suspension in phosphate-buffered saline (PBS) was 1×10^6 CFU/ml. The rats were kept under observation for 18 hrs for clinical symptoms of meningitis to develop. 10-50 μ l of the CSF sample was collected for confirmation by gram's staining and culture. The rats were perfused transcardially with saline followed by 10% formalin. Brains were removed, processed for paraffin sectioning and stained with cresyl violet staining. Neurodegeneration in the hippocampal CA1, CA3 and dentate hilus were quantified. DNA damage was assessed by the alkaline single-cell gel electrophoresis "comet assay" method. The hippocampal sub-regions showed neurodegeneration in the form of cellular damage. Significant fractions of neurons in the above regions were darkly stained and were irregular in shape. There was 56-81% neuronal loss in these regions. The surviving neurons showed 34-45% decrease in cell diameter and 28-29% decrease in the cross-sectional area in the hippocampal sub regions. But there were no DNA damage observed in all the regions of the hippocampus as a whole. Pneumococcal meningitis that was induced in the 30 days old rats conformed to the clinical parameters observed for meningitis and the histological analysis showed cellular damage likewise; but most interestingly there was no DNA damage in the hippocampus. This could be due to the fact that the rats were only in the acute phase of infection. Most probably, the time required for the DNA damage to occur would require that the rats proceed to a chronic phase. This finding could very well hold hope for meningitis cases that could be salvaged during the acute phase itself, thereby curtailing the neurological sequelae commonly observed after recovering from an untreated or chronic pneumococcal infection.

Keywords: Pneumococcal Meningitis, Neuronal Injury, Neurodegeneration, Hippocampus, DNA Damage

1. Introduction

Previous experimental studies have shown that pneumococcal meningitis causes histomorphological necrotic changes in the brain during pathogenesis that involves pneumolysin and H_2O_2 along with reactive free radicals. The passage of pneumococci from the blood into the brain is generally the accepted route by which meningitis develops. Previous studies on endothelial cell culture

models show that pneumococci expressing pneumolysin were able to breach the endothelial cells, whereas mutant pneumococci deficient in pneumolysin were unable to penetrate the cell barrier [1]. This is good evidence that pneumococci expressing pneumolysin may penetrate readily the vasculature of the central nervous system and gain direct entry into the CSF. Because the vascular epithelial cells regulate the passage of molecules from blood to CSF and the ciliated ependyma has a similar function in the regulation of molecules from CSF to brain, it is reasonable to hypothesize

that the effect of pneumolysin on each cell type will share common characteristics. Hirst et al. have shown that pneumolysin is toxic to ciliated ependymal cells [2, 3].

Gross meningeal inflammation has been associated with blood vessel inflammation, central nervous system (CNS) necrosis, neuronal loss and general inflammation of brain tissue and cranial nerves. It is generally believed that prior to meningitis the pneumococci must first successfully colonize the circulation, and providing there is no trauma, breach the blood-brain barrier before they are able to colonize the CSF. Once in the CSF, three stages of events in pneumococcal meningitis have been identified. First, invading bacteria cause an inflammatory response in the CSF; the cerebrovasculature then reacts to this inflammation resulting in hyperemia and ischaemia, and finally toxic events in the brain cells lead to permanent brain injury [4]. Other recent reviews on the pathogenesis of pneumococcal meningitis have focused on the mechanisms of neuronal injury [5-7]. Among the ones listed in the pathogenesis of pneumococcal meningitis; pneumolysin is supposedly the autolysin that recruits apoptosis inducing factor (AIF) that results in apoptotic damage to neuronal cells in the brain.

According to our study, we have found that although conflicting data exists regarding the nature and pathogenesis of pneumolysin along with the other mediators causing neuronal tissue damage; there was found no DNA damage in the neuronal tissue of the hippocampus while there was consistent patterns of cellular damage in the region of the dentate gyrus of the hippocampus during the 'acute' phase of the disease.

2. Materials and Methods

2.1. Induction of Acute Pneumococcal Meningitis

30 days old Wistar rats were used for the study. Experiments were carried out after obtaining institutional animal ethical committee approval. Animal breeding and maintenance were done in accordance with guidelines of the Government of India for use of laboratory animals (Journal of Pharmacology: 1999; 31:92; 95). All animals were maintained under 12:12 hr dark: light environment, in an air conditioned institutional central animal research facility. The concentration of the pneumococcal suspension in 0.03M Phosphate-buffered saline (PBS) was 1×10^6 CFU/ml and density was accordingly adjusted to that of 0.5 McFarlands' nephelometric standard. The rats were anaesthetized with 3%vol/vol halothane/ketamine. The animal was mounted on a stereotaxic frame and were intracisternally infected on post natal day 31 with (10ul capacity) Hamilton's Syringe. The symptoms of meningitis were observed after 18-24 hours.

2.2. Immunohistochemistry

All staining was performed on 20- μ m thaw-mounted cryosections spanning the entire hippocampus of both hemispheres. For quantification of BrDU immunolabeled

cells, every 15th section was studied. Proliferation in the dentate gyrus, DG was determined by light microscopic quantification of BrdU immunostaining. For this purpose, slides were air dried and postfixed for 10 min in 4% freshly made paraformaldehyde in PBS. After blocking with 3% normal goat serum and 0.3% Triton X-100 in PBS, slides were incubated with 2 N HCl for DNA denaturation. The sections were washed in Tris buffered saline (TBS) and treated with 3% hydrogen peroxide to remove the endogenous peroxidase activity in the tissue. For pre-treatment, sections were incubated in 50 % formamide solution in 2 X saline sodium citrate buffer (2X SSC) for 2 hours at 60 °C. Slides were rinsed in PBS and incubated with a rat monoclonal antibody against BrdU (1:50) (Sigma Laboratories, India) at 4°C overnight. The tissue sections were further treated with 0.1M baric acid (P^H 8.5), washed in TBS and were blocked in 10% normal horse serum, with 0.01% triton x-100 for 30 minutes. Briefly Sections were washed in TBS and incubated in horse biotinylated anti mouse IgG as secondary. For visualization, a biotinylated goat anti-rat immunoglobulin G (IgG) and ABC peroxidase kit (Vector Laboratories, USA) were used following the manufacturer's instructions. Diaminobenzidine (Sigma) was used as the chromogenic substrate. Slides were then counterstained with hematoxylin and dehydrated, cleared and coverslipped using DPX. mounting media. The number of newly born cells (BrdU positive cells) were counted at 100X magnification. Using optical fractionator method; total number of newly generated cells were estimated.

2.3. Detection of DNA Damage: Comet Assay: Single Cell Gel Electrophoresis

The brains were dissected out of the cranium and hippocampus was isolated. The tissues were placed in 1 ml of cold Hanks Balanced saline solution (HBBS) containing 20mM EDTA/10 % Dimethyl sulphoxide (DMSO). The rat brains of the normal control group and the meningitic group were processed for single cell suspensions. Around 50 μ l of the suspension was taken on a slide and observed for single cells. 10 μ l of this suspension was mixed with 75 μ l Low melting point agarose (LMPA) and were processed accordingly. Low melting point agarose (LMPA) were prepared freshly in 100mM PBS kept at 37°C were mixed with the 50 μ l cell suspension of the hippocampal tissue. This was layered over the first layer after removing the cover slip. The second layer was cover slipped and kept at 4°C for solidification. This was layered over with 100 μ l of LMPA and kept for solidification covered with a cover slip. After draining, the cell microgels were treated with DNA unwinding solution for 30 minutes at room temperature. The microgels were placed directly onto a horizontal gel electrophoresis chamber filled with DNA unwinding solution. Gels were run on constant current of 300mA at room temperature for 20 minutes. The microgels were stained with ethidium bromide, cover slipped and observed for DNA damage and the number was counted under fluorescence microscope under 40X objective. A total of 112

cells per slide per rat brain were counted.

2.4. Statistical Analysis

All data were expressed as mean \pm SEM and the comparison between the various groups was done by ANOVA and post hoc test was also done wherever necessary with the help of Bonferroni multiple comparison test. P value < 0.05 was considered significant.

3. Results

3.1. Cellular Damage of Hippocampus Neurons

Table 1. are the results of the various parameters observed for rats that have been induced with pneumococcal meningitis and those that are normal without infection. The percentage of damage is documented for the various regions

of the hippocampus. Neuronal cell density especially in the CA3 region was greatly affected with only 19% of cells showing survival while the rest 81% show cellular damage. The dentate hilus region shows 60% reduction in neuronal cell density while 40% showed survival followed by CA1 region. The parameter measuring neuronal diameter was shown to be affected greatly in the dentate hilus region (45%) followed by the CA1 region (36%) and then by the CA3 region (34%). There was not much of a difference in the cross sectional area between the three regions and on an average they showed a damage of 28%. The results of the various regions under the various parameters measured in the hippocampus show a definite pattern of cellular damage consistent with infection and inflammation relating to neuronal insult during bacterial meningitis. All data has been expressed as mean \pm SEM and P value < 0.05 is considered significant.

Table 1. Depicts the parameters analyzed in the CA1, CA3 and the dentate hilus region of the hippocampus.

Parameters analyzed	Normal Control	Meningitis group	Percentage (%)
	(NC) Mean \pm SEM	(MG) Mean \pm SEM	of Damage
CA1			
Neuronal Cell Density	198.1 \pm 3.42	86.83 \pm 3.58	56%
Neuronal Diameter	25.6 \pm 0.96	16.3 \pm 0.67	36%
Cross sectional area	168.1 \pm 4.31	120.6 \pm 8.34	28%
CA3			
Neuronal Cell Density	481.5 \pm 37.46	188.0 \pm 3.96	81%
Neuronal Diameter	29.9 \pm 2.02	19.6 \pm 0.50	34%
Cross Sectional Area	181.1 \pm 4.33	130.0 \pm 8.29	28%
Dentate Hilus			
Neuronal Cell Density	281.281.5 \pm 27.75	113.0 \pm 2.01	60%
Neuronal Diameter	31.9 \pm 0.48	17.6 \pm 0.41	45%
Cross sectional area	181.1 \pm 5.20	128.7 \pm 6.55	29%

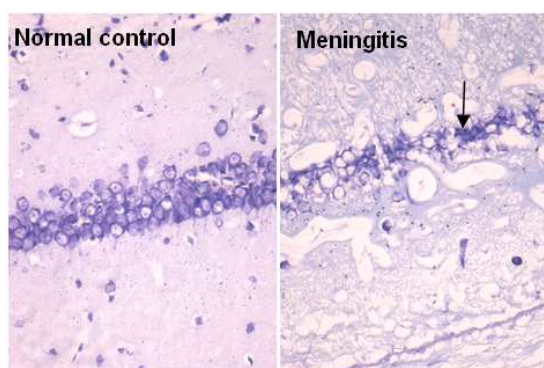


Figure 1. Hippocampus (CA1 region) as seen in control and meningitis brain. Degenerating neurons are darkly stained and show (arrow). Cresyl violet stain (40x magnification)

3.2. Histomorphological Changes of the Cells of the Hippocampus

Fig. 1. shows part of the hippocampus of the CA1 region, stained with cresyl violet staining. The panel on the left

(Normal control) show neurons that are entire with healthy morphology and without any damage to their cell walls or structure. The panel on the right (Meningitis), show neurons that have been affected due to pneumococcal insult to the brain; where the neuronal cells show shrunken morphology with cellular damage. Both panels put together can easily be compared to show the width of the cells in the CA1 region. It is markedly reduced in the case of the meningitis induced rat brains. The same was observed for the CA3 and the dentate hilus regions of the hippocampus in the meningitis brains. Care was taken to keep the brain sections preserved for further analysis and quantification of neuronal cellular damage.

3.3. Comet Assay of Rats with Untreated Pneumococcal Meningitis

Fig.2. shows single cell gel electrophoresis of the hippocampal neurons. The neurons showed no DNA damage as depicted in the slides of the comet assay where there was found to be no comet tails that could significantly

depict DNA damage. The neurons of the normal rat brains and those that have been intracisternally inoculated with pneumococcal meningitis showed definitive DNA morphology and the neuronal insult did not necessarily cause damage to the genome of the hippocampal neurons as was expected to see during disease and pathogenesis. Both the cells of the hippocampus of normal rats and those that of the infected rats were comparably with the same protected DNA genome without visible damage.

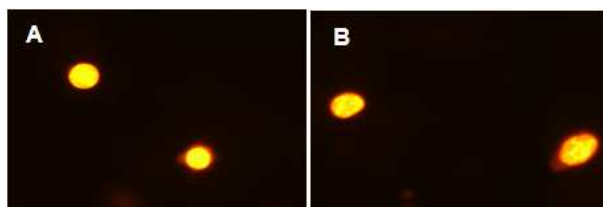


Figure 2. Comet assay: Panel 'A' shows single cells of the hippocampus of a normal rat that did not undergo any DNA damage under the single cell gel electrophoresis conducted at 30 volts for 30 minutes (alkaline) while panel 'B' are hippocampal cells of a meningitis induced rat showing no DNA under the same alkaline condition run in the comet assay. Cells stained with ethidium bromide and observed at 40X magnification

3.4. Assessment of DNA Damage during Acute Pneumococcal Meningitis

Fig 3. Is the measure of the Oliver tail moments (OTM) of the comet assay of the neurons of the hippocampus to check for DNA damage. The graph is a comparison between the hippocampal neurons of the normal rats and those that of the meningitis induced groups. The bars when compared between the two groups does show some difference but in totality with the OTM values obtained; the values do not significantly fall in line with the values to consider DNA damage which is 23 and above. The values obtained for the difference observed in the meningitis group was only found to be negligible and not in the puvieu to consider any DNA damage. The difference in the Oliver tail moments (OTM) of normal (N) (2.204 ± 0.2262 n=6 Vs 2.904 ± 0.2413 n=6; *p value ≤ 0.0354 Statistical analysis: Student-t test.) and meningitis induced rat (M) was only 0.7OTM which is quite negligible.

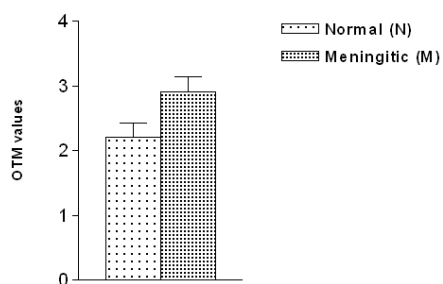


Fig 3. The Oliver tail moments (OTM) values of normal (N) (2.204 ± 0.2262 n=6) and meningitis induced rat (M) (2.904 ± 0.2413 n=6). Statistical analysis: Student-t test. *p value ≤ 0.0354

4. Discussion and Conclusions

The animals were graded to observe for clinical

symptoms of meningitis. The rats infected with intracisternal inoculation of pneumococcal suspension did show less of ambulatory movements and lethargy. The whole brain morphology also showed signs of inflammation due to the presence of petechiae. Microscopic examination of the CSF revealed a picture of pleiocytosis with gram positive diplococci and the gross brain weight was about 200-250 gms on an average in the 30 – 34 days old rats. The hippocampus was decreased significantly in its size and all the layers were decreased in their thickness in the meningitis brain compared to normal control brain. The majority of the neurons showed degenerative features. The degenerating neurons were irregular in shape and were darkly stained.

Experiments showed that pneumococcal meningitis does cause severe lesions in the sub regions of the hippocampus. Mechanism of neuronal injury to the hippocampal neurons could be due to the downregulation of neurotrophic factor during meningitis insult [8]. The neurodegeneration though in the form of cellular damage may result or explain the consequences for cognitive deficits as post infection sequelae [9].

Studies have shown that low leukocyte count during pneumococcal meningitis are generally fatal and a high CSF concentration of bacteria with low counts of leukocytes are well recognized clinically and this scenario before any therapy is a poor prognostic sign in experimental meningitis and also in man. But our study documents pleiocytosis during the acute phase of infection and this may very well contribute to the fact that there is sufficient time for brain repair and regrowth and this could hold much therapeutic prospects for neural stem cell regeneration to thwart progressive chronic disease ending in sequelae such as cognitive deficits. Time of progress of the disease could be one of the factors that could explain why there is no DNA damage in the 'acute' stage of pneumococcal meningitis. The time for the pneumolysin to cause and initiate the apoptosis inducing factor during the acute infection may well be one of the reasons that may help to keep the genome whole without any DNA damage; but only causing cellular damage.

In man, cerebral neuroimaging studies, as shown by Kastenbauer *et al.*, have the potential to monitor the intracranial consequences of meningitis in humans at multiple points in time and could help guide therapy directed at specific aspects of the infection. Unfortunately, the prognosis for patients with *S. pneumoniae* meningitis remains neither qualitatively nor quantitatively different than it was thirty years ago. The study of the infection during the acute stage may well help to bring down the pathophysiology associated with neurodegeneration and neuronal insult during pneumococcal meningitis. This may help the cells to regenerate as still the genome remains intact during the acute phase as brought out from our study. Many lines of recent evidence have revealed, however, that progenitors with the ability to produce new neurons and glia remain in the adult CNS. In particular, neural stem cells

defined with the characteristics of long-term self-renewal and multipotentiality have been shown to persist throughout life in various mammalian species including humans [10]. This could open up vistas for initiating therapeutic modalities with conjunctive therapy to address various pathways that set the inflammatory process and coagulative processes during the course of the infection and this could well be thwarted at the acute phase of infection and to encourage the neuronal cells towards self repair and regrowth.

Acknowledgements

This project was funded by the Department of Science and technology, New Delhi under the women scientists' fellowship.

References

- [1] G. Zysk, B.K. Schneider-Wald, J.H. Hwang et al. Pneumolysin is the main inducer of cytotoxicity to brain microvascular endothelial cells caused by *Streptococcus pneumoniae*. vol. 69. *Infect Immun*, 2001, pp.845–852.
- [2] R.A.Hirst, A.Rutman, K.Sikand, P.W.Andrew, T.J. Mitchell, C. O'Callaghan. Effect of pneumolysin on rat brain ciliary function: comparison of brain slices with cultured ependymal cells. Vol.47. *Pediatr Res*, 2000, pp.381–384.
- [3] B.J.Mohammed, T.J.Mitchell, P.W.Andrew, R.A.Hirst, C. O'Callaghan. The effect of the pneumococcal toxin, pneumolysin on brain ependymal cilia.. vol. 27. *Microb Pathog*, 1999, pp.303–309.
- [4] S.L.Leib, Y.S.Kim, L.L.Chow, R.A.Sheldon, M.G.Ta'uber. Reactive oxygen intermediates contribute to necrotic and apoptotic neuronal injury in an infant rat model of bacterial meningitis due to group B streptococci. Vol. 98. *J Clin Invest*, 1996, pp. 2632–2639.
- [5] W.Michael Scheld, U.Kodel, B.Nathan and H.W.Pfister. Pathophysiology of Bacterial Meningitis: Mechanism(s) of Neuronal Injury. 186(Suppl 2). *The Journal of Infectious Diseases*, 2002, pp.225–233.
- [6] R.Nau, W.Brück. Neuronal injury in bacterial meningitis: mechanisms and implications for therapy. Vol. 25. *Trends Neurosci*, 2002, pp.38–45.
- [7] L. Li, Q.X. Shui, K. Liang, H. Ren, H. Brain-derived neurotrophic factor rescues neurons from bacterial meningitis. Vol. 36. *Pediatr Neurology*. 2007.pp.324-329.
- [8] A. Wellmer, C. Noeske, J. Gerber, U. Munzel, R. Nau. Spatial memory and learning deficits after experimental pneumococcal meningitis in mice. Vol.296. *Neurosci Lett.*, 2000, pp.137–140.
- [9] M Sande and Wills. Leukocyte and bacterial interrelationships in experimental meningitis.. Vol. 9. *Ann. Neurol.*, 1981, pp.328-333.
- [10] Temple, The development of neural stem cells, Vol. 414. *Nature*, 2001, pp.112–117.