

About surgical tactics in damages of the thoracic and lumbar parts of the spine

Yuldashev S. S.

Neurosurgery department of RSCUMA, Samarkand State Medical Institute, Samarkand, Uzbekistan

Email address:

x.karabaev@yandex.ru

To cite this article:

Yuldashev S. S.. About Surgical Tactics in Damages of the Thoracic and Lumbar Parts of the Spine. *American Journal of Clinical and Experimental Medicine*. Vol. 1, No. 3, 2013, pp. 48-52. doi: 10.11648/j.ajcem.20130103.12

Abstract: In the overall structure of spinal injuries in adults vertebro-spinal injury ranges from 2.2% to 20.6%. When fractures of the spine are complicated by neurological disorders, most commonly lower thoracic and lumbar vertebrae - 39.2% and 48.5% are injured respectively. 45 patients with damage to the thoracic and lumbar spine, admitted to the neurosurgical department of RSCUMA. The main method of preparation of the combined graft is performed in the following manner: Bone graft is taken from the iliac crest and wings of the fibula of the patient, depending on the size of the vertebra. Next, the graft is cleaned of soft tissues and placed in a glass, which contains 3% of hydrogen peroxide, then in a second glass with a solution of broad-spectrum antibiotic for 5-10 minutes. To improve and strengthen support ability of bone graft, a hole is formed in the middle of the graft with the drill, which is then filled with bone cement. Bone cement is dissolved before use with a special solvent and liquid form is introduced with a syringe through the hole formed in the bone graft. The bone cement hardens within the bone hole and thereby enhances support ability of the transplant. To increase the coupling properties of the graft a few teeth are formed at its ends. The resulting clinical and neurological findings in these patients showed that after a comprehensive operative and conservative treatment 31 (68.9%) patients had positive neurological symptoms, increased sensitivity below the level of damage, and also the growth of the movement in the distal extremities was noted improvement of function of the pelvic organs in the form of urination. But despite undertaken complex therapeutic measures in 14 (31.1%) patients is not a marked improvement in neurological performance was not noted during treatment. The dynamics of neurological disorders after surgical treatment showed that in complicated injuries of the body of thoracic and lumbar vertebrae combined graft provides sufficient support ability of the spine and thus creates the conditions necessary to restore the function of damaged spinal cord and its elements

Keywords: Vertebro - Spinal Injuries, Diagnostic and Treatments

1. Introduction

In the overall structure of spinal injuries in adults vertebro-spinal injury ranges from 2.2% to 20.6% [1, 2, 3, 4, 5, 6, 7]. When fractures of the spine are complicated by neurological disorders, most commonly lower thoracic and lumbar vertebrae - 39.2% and 48.5% are injured respectively [8].

According to various authors, the greatest proportion of spinal injuries is accounted for cervical - 30.0-40.0% of cases, followed by lumbosacral - 25.0-45.0%, thoracic - 15.0-25.0% and multilevel spinal injuries - about 5% [9,10, 11, 12, 13, 14, 15].

Most patients (50-80%) are the persons of young and working age - 20-50 years [16, 17]. Unstable injuries in the lower thoracic and lumbar spine parts are most common -

to 54.9% of all injuries of the spine and are characterized by a wide variety of factors affecting treatment outcome [18, 19].

There remain a high percentage of deaths among patients with complicated spinal injury - 34.4% [21, 22]. Fatal outcomes depend on the level of localization of injury and according to the literature, the trauma of the cervical parts of the spine and spinal cord is accompanied by the highest mortality rate - up to 75.0%, thoracic - 10.0%, lumbar - to 6.0% [23, 24].

So far, a number of issues, that is indications and choice of access for decompression, methods for correction of posttraumatic deformations stabilization of damaged part of the spine and the choice of plastic materials, the use of metal constructions and non-biological or biological implants remain controversial.

The use of surgical treatment for acute injuries of the spine has two important advantages. First of all - the ability of biomechanical correction with restoration of vertebral segment forms of the spinal canal. Secondly, the - operative treatment can reduce the number of neurological complications and shorten the time of treatment.

Surgical management of spinal cord injury depends on the nature of the spine damage and to a large extent on the spinal cord injury. The main objective in the treatment of such patients is to identify emerging compression of the spinal cord and its elimination at the earliest possible time. Surgical intervention must be resulted in a reliable fixation of the spine, but there is a problem with the choice of a plastic material for the anterior spondylodesis or corporodesis.

The data of the authors suggest that in ventral spondylodesis each of used implants, grafts, biological and nonbiological plastic material having osteoinductive and osteoconductive properties, has certain disadvantages. The most significant disadvantage of many implants, particularly metallic implants is significant difficulty in the further observation of changes in the spinal cord in the area of operations due to their close proximity to the vertebral canal and the creation of background noise in the computer or (CT) or magnetic resonance (MR) imaging.

The purpose of the study: The aim of our study was to improve the results of surgical treatment of patients with unstable body injuries of thoracic and lumbar parts of the spine using a combined transplant.

Material and methods: 45 patients with damage to the thoracic and lumbar spine, admitted to the neurosurgical department of RCSUMA. Of them - 34 (75.5%) patients were men, 11 (24.5%) - women. Age of patients ranged from 16 to 62 years, 23 (51.1%) patients were diagnosed with damage to the spine at the level of Th12 - L1, in 11 (24.4%) - damage to the L1-L2, in 9 (20.0%) damage - L4, minimal damage had Th11 - 2 (4.5%) patients.

Length of hospitalization from the time of injury ranged from 6 hours to 3 days. Distribution of patients according to the mechanism of injury is shown in Table 1.

Table 1.

The mechanism of injury	Number of patients	
	the absolute quantity of patients	%
Falling from a height of	17	37,8
Traffic accident	9	20,0
Consumer injury	15	33,3
Compression of the body with a hard object	4	8,9
TOTAL	45	100

Table 1 shows that of 45 patients - 17 (37.8%) were injured when falling from a height, 9 (20.0%) in road trauma, 15 (33.3%) at the home, and 4 (8.9 %) patients with compression by heavy objects. The complex of

diagnostic measures included clinical conditions, neurological and X-ray (radiography, computed tomography, magnetic resonance imaging) studies.

All patients underwent a thorough neurological examination. In order to maximize objectification of neurological status the International Classification of neurological manifestations of spinal injuries and spinal cord ASIA ISCSI (American Spine Injury Association/International Standards for Neurological and Functional Classification of Spinal Cord Injury) [19,22] was used. Muscle strength and sensitivity were assessed in each segment on both sides in points; the data were brought into the card, and then summed. Particular attention was paid to check motor and sensory functions of segments S2-S4 by the digital examination of the rectum. Almost all of our victims belonged to the ASIA scale of Group D.

The resulting digital characterization of motor and sensory disturbances allowed not only to define clearly the level and degree of spinal cord lesions, but also to conduct dynamic monitoring, which was essential to determine the tactics and evaluation of treatment outcomes.

In the analysis of spondylograms the condition of bodies, arches and processes of damaged and adjacent intact vertebrae and their relationship (the presence of subluxation or dislocation), the state of the intervertebral discs, interspinous spaces, sagittal and frontal profile (presence of cyphotic deformities) were estimated.

According to spondylograph data the degree of damage to the stability of three-column of F.Denis system was determined and assessed (1983), (Table 2).

Table 2

Damaged columns	Number of patients	%
The front	6	13,3
Front and middle	16	35,6
The front, middle and rear	23	51,1
Total	45	100

The structure of the damaged vertebrae, which total was 45, almost half was completely unstable (three-column) injuries - 23 (51.1%). Relatively unstable damage within two (anterior and middle) pillars was observed in 16 (35.6%) cases. The remaining six (13.3%) lesions, affect only the front pillar.

Control of spine radiography in two projections was performed in all patients immediately after surgery, in three, and then in every 6-12 months to assess the correction of posttraumatic deformation, the position of the graft and the timing of formation of interbody bone block.

Computer-tomographic studies were performed on the multislice tomograph of «Siemens» company. Initial CT study was perform in 38 (84.4%) patients in order to clarify the location and nature of bone damage. Scanning (step 1 mm) of the damaged vertebral-motor segments from the seizure of the legs of adjacent intact vertebrae was performed. We studied axial slices, followed by 2D (sagittal)

and 3D reconstruction of the spine. In this geometry of the spine and spinal canal, the nature of fracture, location of bone fragments, narrowing of the spinal canal was clarified.

In the postoperative CT scan was used to assess the quality of performed spinal canal decompression, correction of the deformity and the status of established transplants and quality of forming anterior spondylodesis. This study was performed in 42 (93.3%) patients.

Magnetic resonance imaging was performed in 24 (53.3%) patients. This study complemented the data of spondylography and computed tomography. It was designed to identify and clarify the post-traumatic changes in the spinal cord, the degree of compression of neurovascular structures of the spinal canal, intervertebral disc lesions, and capsular ligamental apparatus of the rear supporting complex.

During the follow-up patients were invited for re-examination or inspected on-site in 3, 6, 12 or more months after the final stage of surgery on the spine. Data collection was carried out by catamnesis survey and assessment of spondylography or computed tomography in the dynamics. All patients vertebral fractures were unstable and complicated the displacement of bone fragments were observed in the spinal canal, and they were subjected to surgical treatment. Surgical intervention included spinal decompression of spinal canal elements, deformity correction and stabilization of damaged motor spinal segments with the restoration of anterior interbody support with combined graft of the front-side access.

In order to ensure the stabilization and fixation of the spinal segment after complete anterior decompression of spinal cord we have developed a composite graft consisting of autologous bone and bone cement (Priority certificate to obtain a patent for the invention of the application for RU № IAP 20,100,362 on 29.07.2010).

Designed combined graft (DCG) - the sizes of which are formed according to the values obtained by a defect in the operated segment of the spine (Fig. 1).

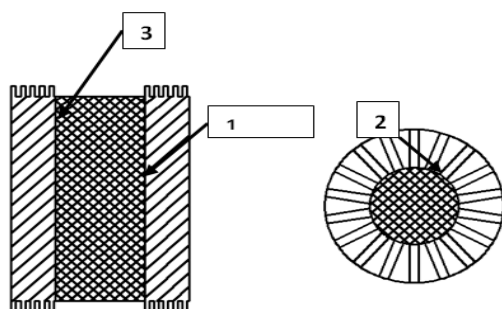


Fig 1. Longitudinal and transverse view of the combined transplantation

- 1-. combined bony wall of the transplantation;
- 2-. notches at the distal and proximal parts of the composite transplantation;
- 3-. the cavity of the transplantation filled with bone cement.

The method of preparation of the combined graft is

performed in the following manner: Bone graft is taken from the iliac crest and wings of the fibula of the patient, depending on the size of the vertebra. Next, the graft is cleaned of soft tissues and placed in a glass, which contains 3% of hydrogen peroxide, then in a second glass with a solution of broad-spectrum antibiotic for 5-10 minutes. To improve and strengthen support ability of bone graft, a hole is formed in the middle of the graft with the drill, which is then filled with bone cement. Bone cement is dissolved before use with a special solvent and liquid form is introduced with a syringe through the hole formed in the bone graft. The bone cement hardens within the bone hole and thereby enhances support ability of the transplant. To increase the coupling properties of the graft a few teeth are formed at its ends.

The use of combined graft in spinal body's injuries in most cases makes it possible; to dispense with external immobilization support ability is not lost when you rebuild graft bone into a single unit. In addition, the combined transplant withstands a greater load than the auto transplant without bone cement.

The use of combined graft during surgery for injuries body of thoracic and lumbar spine bodies is carried out in the following sequence.

In operations on the bodies of the thoracic and lumbar vertebrae is preferred posterolateral thoracotomy through the bed of the resected ribs. Access to lower-thoracic and upper lumbar vertebrae is normally produced by X or XI of the bed edges. Access to the lumbar vertebrae is through transabdominal approach and bodies of broken vertebrae and adjacent discs are resected (Fig. 2 and 3). The grooves in the adjacent vertebrae should be designed in strict accordance with the configuration and parameters of transplants. They should provide a dense and maximum contact of spongy substance with the broken bodies of adjacent vertebrae and the graft, and to prevent migration of the latter.

Increasing of the space between the bodies of blocked vertebrae is achieved by placing a roller under the body of a patient on the operating table or using special the legs of distractors. The legs of distractors are placed on the closing plates of blocked vertebrae or the screws previously screwed into the body adjacent to the damaged vertebrae. After that, the combined graft is placed in the slots of blocked vertebrae (Fig. 4). Then, the roll distractor is removed that results in tight wedge of the graft. The wounds are sewn up in layers and active drainages are kept.

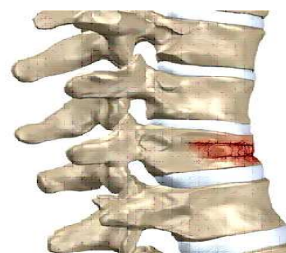


Fig 2. Compression fracture of spine

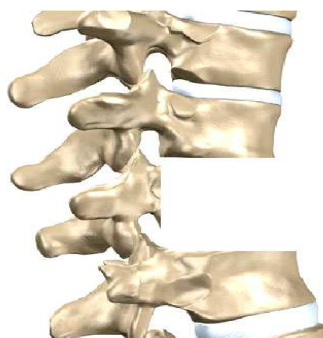

Fig 3. Removal of the damaged vertebra and adjacent discs.

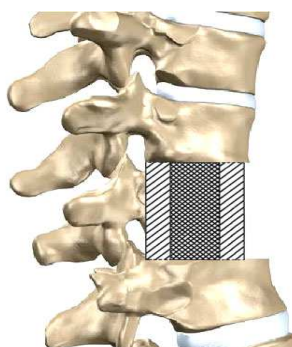


Fig 4. Laying of the combined graft in the bone defect.

All patients had to wear thoracic and lumbar tight corsets in the postoperative period.

In addition to surgery, all patients also received medication. Patients were administered conservative, symptomatic treatment and complex of measures against infectious complications and bedsores. Preparations improving the microcirculation of spinal cord (rheopolyglucin, pentoxifylline), antibiotics and vitamins were administered. In admission to the department patients were given i/v injections of methylprednisolone 30 mg, then immediately after the operation first 30 mg / kg as a stream during 15 min., in 45 minutes i/v drop-by-drop injection during in the day (according to the scheme).

In addition, for the prevention and treatment of spinal cord edema patients were administered antiexsudorific preparation L - lysine aescinat 10.0 ml intravenously with 200.0 ml - 0.9% of saline solution of sodium chloride, 2 times a day for 7-10 days. In order to prevent pulmonary infections during the treatment period, breathing exercises and massage of the chest were carried out.

Timing of follow-up of clinical neurological symptoms and radiological study of patients with damage to the thoracic and lumbar spine ranged from 6 months to 2 years.

2. Results

The resulting clinical and neurological findings in these patients showed that after a comprehensive operative and conservative treatment 31 (68.9%) patients had positive neurological symptoms, increased sensitivity below the level of damage, and also the growth of the movement in the distal extremities was noted improvement of function of

the pelvic organs in the form of urination. But despite undertaken complex therapeutic measures in 14 (31.1%) patients is not a marked improvement in neurological performance was not noted during treatment.

After being discharged from the hospital almost all patients repeatedly received rehabilitation treatment in a regional rehabilitation center.

Studies of x-ray and CT scan of thoracic and lumbar spine in the dynamics showed that in these patients after surgery, the combined graft in the operated spinal segment was held tightly, and stabilization in the operated spinal segment had been reliable. Reducing introduced graft, the distance of the intervertebral space and the mixing of the transplant in these patients were not noted. Radiographic data received 8-10 months after surgery showed that in all patients single and strong bone block was formed in the area of corporodesis by combined transplant.

3. Conclusions

- 1 Designed by a combined graft consisting of autologous bone and bone cement to stabilize the vertebral segment in injuries of thoracic and lumbar parts of spine is more physiological and is as effective as other biological and non-biological implants.
- 2 The dynamics of neurological disorders after surgical treatment showed that in complicated injuries of the body of thoracic and lumbar vertebrae combined graft provides sufficient support ability of the spine and thus creates the conditions necessary to restore the function of damaged spinal cord and its elements.
- 3 Combined transplant reliably provides stabilization and correction of the damaged segment. Radiographic data received 8-10 months after surgery showed that in all patients single and strong bone block was formed in the area of corporodesis by combined transplant.
- 4 Employment of combined graft in most cases eliminates the need for external immobilization, it provides enough support ability and strength of vertebrae.

References

- [1] Aganesov A.G. Surgical treatment of complicated spinal injury in acute period. // Journal of traumatic and orthopedist. - 2003. - № 3, - p. 48-52.
- [2] Lebedev V.V, Krylov V.V Emergency neurosurgery. Moscow: Medicine, 2000. - 568.
- [3] Lutsik A.A. Surgical Management of spinal cord injury // 3rd Congress of Neurosurgeons of Russia: Proceedings of the Congress. - St., 2002. - p. 203-204.
- [4] Polishchuk N.E, Korzh NA, Fishchenko VJ (Eds.) Damage to the spine and spinal cord. - Kiev: Book Plus, 2001 - 388 p.

- [5] Ramih E. The evolution of surgery of spinal injuries in the complex rehabilitation // spine surgery. - № 1, 2004. - P.85-92.
- [6] Kondakov E.N Epidemiology of spinal injuries and spinal cord in St. Petersburg / E.N.Kondakov, I.A.Simonova, I.V.Polyakov // Problems of Neurosurgery. - 2002. - № 2. - p. 50-53.
- [7] American Spinal Injury Association, International Medical Society of paraplegia. International Standards for Neurological and Functional Classifications of Spinal Cord Injury. - Chicago, IL: ASIA / IMSOP, 1992. p- 53.
- [8] Savchenko P.A. Surgical treatment of fractures of the thoracic and lumbar spine // Surgical treatment of spinal injuries and diseases: Mater. of Conference. - Tomsk, 2002. - pp. 151-160.
- [9] Davydov, E. Surgical treatment of injuries and diseases of the spine with preservation of functional mobility in the vertebral-motor segment / Sci. - Practical. Conference "Polenovskie reading": Proc Conf. - St., 2005. - p. 104-105.
- [10] Dudayev, A.K., VP Orlov, NP hawk, Nadulich KA, Ramashov PP Post-traumatic spinal instability and methods of surgical correction. Journal of Neurosurgery questions, 1999. №2. a. 57-64.
- [11] Kornilov, N.V. Damage to the spine. Surgical treatment / - St. Petersburg.: Morsar AB, 2000. - p. 232.
- [12] Sipitiy V.I. etc. Complex reconstructive surgical treatment of severe spinal cord injury vertebro spinal trauma with neurotransplantation / / Sci. - Practical. Conference "Polenovskie reading": Mater/ of Conf. - St., 2005. - p.113.
- [13] Briem D, Lehmann W, Ruecker AH, Windolf J, Rueger JM, Linhart W. Factors influencing the quality of life after burst fractures of the thoracolumbar transition / / Arch Orthop Trauma Surg. - Jul 9, 2004. - p.234-6.
- [14] Capen Daniel A., Willi Haye, (Editors) Comprehensive Management of Spine Trauma, Mosby; 1st edition, 1998, p. 442.
- [15] Chen H.C. Esophageal perforation complicating with spinal epidural abscess, iatrogenic or secondary to first thoracic spine fracture / HCChen, WCTzaan, TYChen, PHTu // Acta Neurochir. (Wien). - 2005. - V.147. - № 4. -p. 431-434.
- [16] Aganesov A.G. Surgical treatment of spinal injuries and diseases of the AO systems CSLP and USS / / Margo anterior. - 2000. - № 5-6. - p. 1-4.
- [17] Leontiev M.A Epidemiology of spinal injuries and the frequency of complete anatomic damage to the spinal cord. Problems of Neurosurgery, 2003. № 2. 26-29.
- [18] Ramih E.A. , MT Atamanenko Surgical methods in the complex treatment of fractures of the thoracic and lumbar spine. - Journal of Traumatology and Orthopedics. N. Priorov, № 3, 2003.
- [19] Kornilov, N.V. Surgical treatment of spinal cord injury / / New Technologies in Medicine: Abstracts of scientific. - Practical conference. 2000. - 4.1. - p. 144.
- [20] Yarik D.E. International standards in the assessment of neurological injury and spinal cord / D.E.Yarikov, I.N.Shevelev, A.V.Baskov // Questions of neurosurgery. - 1999. - № 1. - p.36-38.
- [21] Amar A. Surgical Controversies in the Management of Spinal Cord Injury, Blackwell Publishers, 2004, 400 p.
- [22] Ackery A. A global perspective on spinal cord injury epidemiology // J. Neurotrauma. - 2004. - V.21. - № 10. - p. 1355-1370.
- [23] Aito S. Complications during the acute phase of traumatic spinal cord lesions // Spinal Cord. -2003. - № 11. - p. 629-635.
- [24] Kaya R.A., Aydin Y. Modified transpedicular approach for the surgical treatment of severe thoracolumbar or lumbar burst fractures // Spine. - № 4 (2), 2004. -p.208-217.
- [25] Oertel. J, Niendorf. W.R, Darwish N, Schroeder H.W, Gaab M.R. Limitations of dorsal transpedicular stabilization in unstable fractures of the lower thoracic and lumbar spine: an analysis of 133 patients. // Acta Neurochir (Wien) 2004 Jul; 146 (8), 2004. - P. 771-7.